

Anesthesiology
80:825-831, 1994
© 1994 American Society of Anesthesiologists, Inc.
J. B. Lippincott Company, Philadelphia

Head Extension and Laryngeal View during Laryngoscopy with Cervical Spine Stabilization Maneuvers

Randolph H. Hastings, M.D., Ph.D.,* Paul R. Wood, M.B., B.Ch., F.R.C.P.†

Background: Direct laryngoscopy frequently is modified in patients with known or suspected cervical spine injury. The goals of this study were to measure the degrees of head extension required to expose the arytenoid cartilages and glottis if neck flexion were not possible and to determine whether in-line stabilization maneuvers alter the amount of head extension.

Methods: The subjects were anesthetized patients with normal cervical spines and Mallampati class 1 oropharyngeal views. Head extension was measured relative to a line drawn perpendicular to the table. Stabilization consisted of either passive immobilization, with the head held flat against a rigid board, or axial traction.

Results: Without stabilization, arytenoid cartilage exposure and the best view of the glottis was achieved with a $10 \pm 5^\circ$ (mean \pm SD) head extension and a $15 \pm 6^\circ$ head extension, respectively ($n = 31$). Head immobilization reduced extension angles $4 \pm 5^\circ$ for arytenoid exposure and $5 \pm 6^\circ$ for best view compared with no stabilization.

Conclusions: Head immobilization reduced head extension necessary for laryngoscopy. If head extension is construed to be potentially dangerous in patients with cervical spine injuries, head immobilization without traction might be the preferable stabilization technique. (Key words: Anesthetic techniques: tracheal intubation. Spine: atlantooccipital joint, cervical vertebrae.)

THE management of tracheal intubation in trauma patients with actual or potential cervical spine injuries is a difficult and controversial subject.¹⁻³ Failure to restrain the head and neck increases the incidence of secondary neurologic deficits during the hospital course of cervical spine-injured patients.⁴ Therefore,

in current practice, the technique of direct laryngoscopy normally is modified by precautions to restrict movement of the cervical spine in patients with known or suspected cervical spine injury. The cervical spine-injured patient is restrained with the neck straight and the head flat on a rigid board.⁵ An assistant stabilizes the head and neck and may apply axial traction to the head.⁶ The anesthesiologist is advised to move the head as little as possible.² It is unknown how much risk is associated with direct laryngoscopy or how much head extension is safe.

Unfortunately, the conditions imposed for cervical spine protection may not be favorable for direct laryngoscopy. Usually, the neck is flexed, and the head is extended at the atlantooccipital joint to align the axes of the mouth and larynx.^{7,8} The tongue and submandibular tissues then are displaced from the field of view by upward force with the laryngoscope.⁹ In patients with possible cervical spine fractures, the sniffing position is not employed, and the laryngoscopist may not be able to exert sufficient upward force with the laryngoscope without lifting the patient's head off the board. These limitations could increase the amount of head extension necessary for successful direct laryngoscopy.

In this study, head extension was measured with an angle finder during direct laryngoscopy in anesthetized patients with normal cervical spines. The first goal was to measure the extension angles required to make the arytenoid cartilages visible and to obtain the best view of the glottis when the sniffing position was not used. The second goal was to compare head extension and view of the glottis during laryngoscopy in the same patient, with and without a manual stabilization maneuver. We assessed extension during laryngoscopy performed under one of the following conditions: (1) no stabilization, (2) head immobilization without traction, or 3) in-line axial traction. This was a randomized, prospective study. Neither the laryngoscopist

* Assistant Professor of Anesthesia.

† Visiting Assistant Professor of Anesthesia.

Received from the Department of Anesthesia, San Francisco General Hospital, University of California, San Francisco, California. Accepted for publication January 6, 1994.

Address reprint requests to Dr. Hastings: Anesthesiology Service 125, Veterans Administration Medical Center, 3350 La Jolla Village Drive, San Diego, California 92161.

nor researcher knew in advance which maneuver was to be performed with any laryngoscopy.

Methods

Thirty-one patients with ASA physical status 1 or 2 scheduled for elective surgery with general endotracheal anesthesia were studied. All patients had class I oropharyngeal views based on the classification of Mallampati *et al.*¹⁰ Patients with a history of cervical spine pathology, a clinical examination suggesting potentially difficult direct laryngoscopy, or an increased risk of aspiration were excluded. Signs of possible difficult laryngoscopy included short neck, receding mandible, protruding maxillary incisors, and limited atlantooccipital extension. The study was approved by the University of California, San Francisco Committee on Human Research, and all patients gave written informed consent.

The patient lay supine on the operating table with a rigid board extending from the shoulders to the head. Monitors included a pulse oximeter, an electrocardiogram, a blood pressure cuff, and a precordial stethoscope and capnograph. Premedication was given at the discretion of the attending and resident anesthesiologists. The patient received d-tubocurarine (4 µg/kg) intravenously and breathed 100% O₂ for 3 min. Anesthesia was induced with sodium thiopental (4 mg/kg) and succinylcholine (1.5 mg/kg) intravenously. After the onset of unconsciousness, a Velcro strap was slipped under the occiput and wrapped over the ears and the nose to attach the angle finder to the head. The angle finder was a plastic protractor mounted on a ruler. An aluminum pointer swung freely from the protractor on a ball bearing (fig. 1). Head angles were measured with a method described by Bellhouse and Dore,¹¹ which was based on principles outlined by the American Academy of Orthopedic Surgeons.¹² The head was adjusted to a neutral position by moving the occlusal surface of the maxillary teeth (or the gums in edentulous patients) perpendicular to the rigid board. The angle finder was attached to the left side of the head with the Velcro strap and adjusted so that the pointer indicated 0°, with the angle finder perpendicular to the board and parallel to the occlusal surface of the maxillary teeth (fig. 1A). The angle finder moved as a unit with the patient's head during extension and flexion.

The laryngoscopist, an experienced anesthesia resident or nurse anesthetist, was instructed not to flex the

neck or lift the head off the board. Extension was not limited. First, the arytenoid cartilages were exposed with a Macintosh 3 blade (Gary Hull Anesthesia, Huntington Beach, CA). The laryngoscopist then tried to obtain the best possible view of the glottis. An assistant kneeling at the left side of the laryngoscopist performed the stabilization maneuver. The investigator observed and recorded the degrees of head extension (fig. 1B) with exposure of (1) the arytenoid cartilages and (2) the best view. Laryngoscopy and angle measurements were performed twice on each patient, once with a stabilization maneuver and once without. Between laryngoscopies, the head was returned to the neutral position, the lungs were ventilated, and the angle finder was restored to zero position. The tracheal tube was placed after the second laryngoscopy. Sixteen people were laryngoscopists in this study.

The stabilization maneuver used was either manual head immobilization without traction or manual in-line axial traction. For head immobilization, the assistant placed his or her hands on either side of the patient's head, with the finger tips resting on the mastoid processes and held the head firmly against the rigid board with downward pressure. The assistant did not resist head extension or exert axial traction. For axial traction, the assistant placed his or her hands in the same position and actively pulled the head in the caudal to cephalad direction as strongly as he or she felt would be necessary to stabilize the neck in a cervical spine-injured patient. The force applied with the traction was not measured. For the control laryngoscopy, the assistant also placed his or her hands on the patient's head but did not exert force. Eighteen people assisted with stabilization maneuvers in this study. Assistants were instructed with the information presented above but received no additional coaching or training.

Patients were assigned to three experimental groups. The order was determined randomly before the study began. The 31 patients were distributed among the groups as follows:

1. Head immobilization group. In 14 patients, manual head immobilization was employed during one laryngoscopy and no stabilization was used during the other.
2. Axial traction group. In ten patients, manual in-line traction was compared with the unstabilized state.
3. Control Group. In seven patients, stabilization was not employed during either laryngoscopy. The purpose of this group was to determine the reproduc-

LARYNGOSCOPY WITH CERVICAL SPINE STABILIZATION

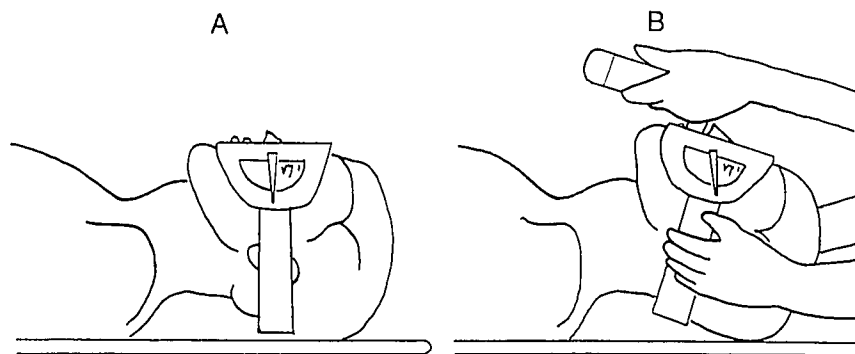


Fig. 1. (A) Attachment and orientation of the angle finder on the subject's head before laryngoscopy. The protractor is raised slightly on a ruler to allow the assistant to hold the subject's head without interfering with the angle finder pointer. (B) Measurement of head extension angle during laryngoscopy. An assistant holds the sides of the head with his or her fingers on the mastoid processes and exerts downward pressure (immobilization), pulls the head axially (traction), or does nothing (control).

ibility of the head extension angle measurement between two successive laryngoscopies in the absence of an experimental intervention.

Neither the laryngoscopist nor the person recording the head extension angle had advance knowledge of the group or maneuver performed. In the head immobilization and axial traction groups, half the patients were assigned randomly to have stabilization during the first laryngoscopy, while the other half had stabilization during the second. Randomization was done by drawing numbers from a table of random numbers.

After tracheal intubation was completed, the laryngoscopist was asked to grade the views obtained with the first and second laryngoscopies using the system of Cormack and Lehane¹³:

- Grade 1 = most of the glottis visible
- Grade 2 = no more than the arytenoid cartilages visible
- Grade 3 = epiglottis only visible
- Grade 4 = failure to expose even the epiglottis

Data for extension angles are presented as mean \pm SD. The differences in extension angles for the two laryngoscopies were compared among the experimental and control groups with one-way analysis of variance with the Student-Newman-Keuls multiple range test. For each group, angles for the two laryngoscopies were compared with the paired *t* test. A *P* value of 0.05 was accepted as significant.

Results

The patients ranged in age from 18 to 49 yr (mean \pm SD, 33 ± 8 yr) and weighed 51–123 kg (mean \pm SD, 71 ± 14). The immobilization, traction, and control groups did not differ with regard to age, weight, or

dose of premedication and induction agents administered (table 1).

Without stabilization, the laryngoscopy grade was 1 or 2 in 30 patients and grade 3 in 1 patient (from the control group). Two patients each in the head immobilization group and the axial traction group changed to grade 3 with stabilization (table 2), even though the complete glottis or arytenoids were visible without stabilization (grades 1 or 2). The laryngoscopic view was the same for both laryngoscopies in all patients in the control group.

It makes sense to compare extension angles only if the laryngeal view is the same for both laryngoscopies. If only the arytenoids are exposed, the extension angle would probably be less than if the full view were obtained, regardless of the effect of stabilization maneuvers. Therefore, results from the four patients in whom the laryngoscopic view changed with stabilization were excluded from the analysis that follows. Head extension angles were compared only for laryngoscopies with the same laryngeal view with and without stabilization.

Without stabilization, head extension angles were $10 \pm 5^\circ$ (range 3 – 25°) to expose the arytenoids and $15 \pm 6^\circ$ (range 5 – 28°) to obtain the best view of the glottis. Head immobilization decreased the angles compared with no stabilization in 10 of 12 patients (fig. 2). The average decreases in angles were $4 \pm 5^\circ$ for arytenoid exposure and $5 \pm 6^\circ$ for best view (table 3). These changes were significant by paired *t* test ($P < 0.05$). Traction increased the angle compared to no traction in seven of eight patients, but the mean increase was not significant ($P = 0.10$). In the control group, extension angles were not significantly different between the first and second laryngoscopies, both without stabilization. By analysis of variance, the change in head extension angles between laryngoscopies differed in the three groups ($P < 0.01$; table 3):

Table 1. Patient Characteristics and Anesthetic Doses

Group	N	Age (yr)	Weight (kg)	Thiopental (mg)	Succinylcholine (mg)	Fentanyl (μ g)	Midazolam (mg)
Immobilization	14	31 \pm 8	72 \pm 19	370 \pm 110	110 \pm 20	130 \pm 70	1.5 \pm 0.5
Axial traction	10	35 \pm 9	70 \pm 10	370 \pm 110	100 \pm 20	100 \pm 80	1.5 \pm 0.5
Control	7	34 \pm 10	70 \pm 6	400 \pm 80	100 \pm 10	60 \pm 70	1.5 \pm 0.5

The change in angle in the immobilization group was significantly different from that in the traction group ($P < 0.01$) but not from that in the control group ($P = 0.08$). Changes in angle in the control group and the traction group were not different.

For the two patients excluded from the immobilization group, the head was extended 28° and 25° for the best view without stabilization, compared to 10° and 23° , respectively, with immobilization. For the two patients from the traction group, head extension angles increased from 16° and 13° for best view without stabilization to 25° and 15° , respectively, with traction.

Discussion

Our study was based on the premise that minimizing head extension is an important goal for laryngoscopy in patients with possible spine injuries. The underlying assumptions were that head extension correlates with movement in the cervical spine and that movement of the spine during laryngoscopy risks secondary neurologic injury. We studied the effects of head stabilization maneuvers on head extension during laryngoscopy. Our subjects were elective surgical patients with normal cervical spines. Therefore, the study is clinically relevant if it can be extrapolated to patients with spine injuries.

Table 2. Laryngoscopy Grades during Stabilization and in Control Group

Group	No. of Patients		
	Grade 1	Grade 2	Grade 3
Immobilization	9	3	2*
Traction	6	2	2*
Control	5	1	1
Total	20	6	5

Grade for control group is for laryngoscopy without stabilization. In the other two groups the grade is with stabilization.

* Four patients changed from grade 1 or 2 to grade 3 with stabilization.

A radiographic study supports the connection between head extension and cervical spine movement. Horton *et al.*¹⁴ showed that direct laryngoscopy causes extension of the atlantooccipital and atlantoaxial joints but minimal movement in the lower cervical spine in normal subjects. The major external movement with direct laryngoscopy is head extension. The neck moves little below the level of the cricoid cartilage during head extension.¹⁵ Therefore, changes in the head extension angle during laryngoscopy probably parallel changes in extension angles in the upper cervical spine in normal subjects. The relationship may not be a degree-for-degree match, nor would it necessarily be linear. The lower cervical spine might move during laryngoscopy in patients with unstable cervical spines.¹⁶

The risk of secondary injury with direct laryngoscopy must depend on the nature and level of the injury and

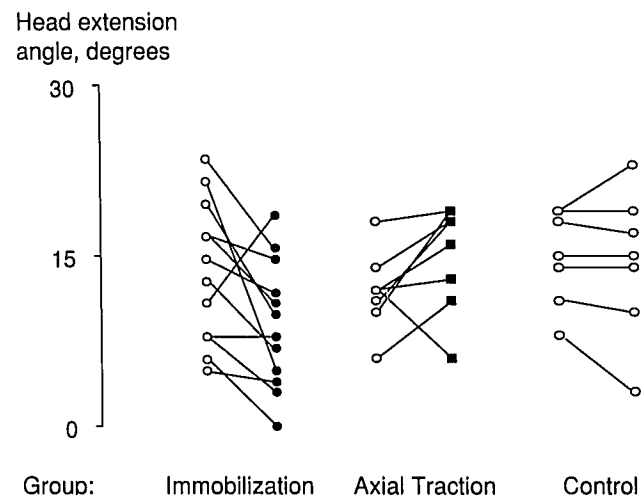


Fig. 2. Head extension angles during laryngoscopy with best view of the glottis. Open circles represent laryngoscopy without stabilization, closed circles represent laryngoscopy with head immobilization, and squares represent laryngoscopy with axial traction. The three maneuvers differ significantly ($P < 0.01$) in their effects on extension angle. Data from four patients in whom the best laryngoscopic view changed with stabilization were excluded, but their exclusion had no effect on the results or statistical analysis.

LARYNGOSCOPY WITH CERVICAL SPINE STABILIZATION

Table 3. Effects of Stabilization Maneuvers on Head Extension Angles

Group	Angle for Arytenoid Exposure (°)			No. of Patients	Angle for Best View (°)			No. of Patients
	A	B	Change		A	B	Change	
Head immobilization A withheld B applied	9 ± 5	5 ± 5*	-4 ± 5†	12	14 ± 6	9 ± 6*	-5 ± 6†	12
Axial traction A withheld B applied	6 ± 2	9 ± 4	4 ± 4	8	12 ± 3	15 ± 5	3 ± 5	8
Control A stabilization withheld B repeat	11 ± 5	11 ± 6	0 ± 2	6‡	15 ± 4	14 ± 7	0 ± 3	7

Values are mean ± SD. The change in angle was calculated for each patient (angle B – angle A) and averaged. A positive number means extension was on the average greater when the stabilization maneuver was applied than when it was withheld.

* Significantly different from angle with stabilization withheld, $P < 0.05$.

† Significantly different from traction group, $P < 0.01$.

‡ Arytenoid exposure was not possible in one patient in the control group.

the amount of spine movement. Injuries of the atlas or axis, where most of the movement occurs, probably carry greater risk than injuries in the lower cervical spine; however, there must be some risk for lower cervical spine injuries. An autopsy study of cadavers with surgically disrupted ligaments in the anterior and posterior compartments found that mask ventilation and direct laryngoscopy displaced injured segments at levels other than C1–C2.¹⁶ In addition, a recent case report documented the occurrence of quadriplegia after airway management in a patient with injuries at C6–C7.¹⁷ Neurologic deficits secondary to airway management are apparently rare, even though most airway maneuvers cause movement in the cervical spine.^{16,18,19} It therefore is not clear how much movement must occur for a significant risk of injury to result. The definitive study would require fluoroscopy during laryngoscopy in thousands of cervical spine-injured patients.

The critical question for everyday clinical practice is, "How much external movement is safe during laryngoscopy?" Because the answer is unknown, the most conservative approach is to minimize the disturbance of laryngoscopy as much as possible. Head extension is the most appropriate movement to consider because it is the major movement that occurs during laryngoscopy. For this study, we wanted to ascertain how much extension was necessary to view the arytenoid cartilages and full glottis under the conditions used for cervical spine protection and to determine whether stabilization maneuvers affected this amount. Arytenoid cartilage exposure was one of the end points, because this rep-

resents the minimum view needed for tracheal intubation under direct vision.

Without stabilization, extension angles of $10 \pm 5^\circ$ and $15 \pm 6^\circ$ were required for arytenoid exposure and the best view, respectively, with the head and neck straight and no sniffing position. These angles are much smaller than the upper limits of head extension in normal people. They also are smaller than the angles observed during laryngoscopy in normal patients in the sniffing position. Horton *et al.*²⁰ reported that maximum head extension in awake volunteers was between 70° and 100° . When those volunteers underwent laryngoscopy under topical analgesia (with no attempt to minimize extension), the plane of the face was extended 20° from horizontal plane, with the neck flexed 35° .²⁰ The angles in our study may have been smaller, because the subjects were anesthetized and paralyzed and a conscious attempt was made to minimize movement. In addition, all our subjects had Mallampati class 1 oropharyngeal views. We cannot comment on whether the sniffing position alters the movement necessary for laryngoscopy, because we did not directly compare head extension with and without the sniffing position. Head movement might be different with a straight laryngoscope blade than with a Macintosh laryngoscope. However, Majernick *et al.*¹⁹ found no difference in cervical spine movement using straight blades and curved blades in a small number of uninjured patients.

Head immobilization and axial traction affected head extension during laryngoscopy differently. Head im-

mobilization significantly decreased the degrees of extension required to view either the arytenoids or full glottis compared to the situation without stabilization. Traction did not have a significant effect. Head immobilization may be beneficial, because it increases the amount of upward and forward force the laryngoscopist can exert with the laryngoscope. This otherwise is limited in patients with potential spine injuries because of the danger of lifting the head. Holding the head on the table creates a counter force, enabling the laryngoscopist to achieve maximal displacement of the submandibular and pharyngeal soft tissues. Presumably, the glottis would then be exposed with less head extension than in the unstabilized state.

The purpose of the control group was to determine how much change in extension angle might be expected simply because of experimental variability in angle measurement. Extension angles changed by more than 1° for consecutive laryngoscopies in only two of seven patients in the control group, compared to 9 of 12 in the immobilization group. The mean difference in angles, however, was not significantly different between the immobilization group and the control group, $5 \pm 6^\circ$ versus $0 \pm 3^\circ$, respectively ($P = 0.08$ by the Student-Newman-Keuls multiple range test). We cannot exclude a type II error because of the small patient number and large variability. Variability could arise from inconsistency in the angle measurement, the effort of the laryngoscopist, or the traction exerted by different assistants. There did not seem to be a systematic variation with the order of laryngoscopy. Mean head extension for full glottic exposure was $14 \pm 6^\circ$ on the first laryngoscopy and $14 \pm 7^\circ$ on the second ($n = 31$).

Variability might have been reduced by having one laryngoscopist and one trained assistant for the entire study, but this was not done. The study was designed to study the stabilization maneuvers as they might be used in clinical practice. The assistant was an anesthesiologist, nurse anesthetist, or surgeon available at the time the anesthetic administration began. The amount of force was not measured and was left to the discretion of the assistant, as would occur in a real situation. The instruction to pull "as hard as you feel is necessary to stabilize an unstable spine" is admittedly nebulous. Other possible instructions, however, such as "balance the force exerted by the intubator,"²¹ are also vague, because the assistant has no feedback on the amount of force. When the study was ended, assistants were asked to judge how much traction they applied. All assistants reported that they used a moderate amount

of force, more than a gentle tug but much less than the maximum possible pull. The force was such that traction could have been maintained comfortably for minutes. Of course, "moderate force" may vary among individuals depending on build, strength, and temperament. None of the assistants, however, appears to have applied severe traction.

This study might not apply to patients with acute cervical spine injuries, because it was carried out on normal anesthetized patients. The mechanics of direct laryngoscopy could vary depending on the level of injury, the amount of bony or ligamentous involvement, and the stability of the spine. Muscle spasm also could affect the force necessary for laryngoscopy. There are at least two reasons why our results might be extrapolated to acutely injured patients. First, muscle spasm would not be a factor in our clinical practice, because direct laryngoscopy in trauma patients usually is accompanied by muscle relaxation and anesthesia when appropriate. Second, our proposed mechanism for the action of passive immobilization should still hold true in patients with spine injuries. Holding the head on the table would provide a counter force allowing greater lift on the jaw, whether or not the cervical spine is injured. Immobilization therefore potentially could reduce the extension required for laryngoscopy in cervical spine-injured patients, just as it does in normal patients.

Difficult laryngoscopy may be more likely in patients treated as though they had cervical spine injuries because the sniffing position is not used. Suderman *et al.*²¹ reported difficulty with orotracheal intubation in 4 of 91 (4.3%) cervical spine-injured patients before elective spine surgery. Estimates of the incidence of difficult laryngoscopy (grade 3 or 4) range from 0.3% to 3% in general surgery patients.^{9,11,22} In this study, 1 of 31 (3.1%) patients had a grade 3 view without stabilization. Two patients each in the immobilization group and the traction group developed a grade 3 view with stabilization. The view did not improve with stabilization in any patient. The number of patients in this study is too small to determine whether either stabilization maneuver has a clinically significant effect on laryngoscopic view.

In summary, small degrees of head extension were required for laryngeal exposure in anesthetized elective surgical patients with heads flat and necks straight— $10 \pm 5^\circ$ for arytenoid exposure and $15 \pm 6^\circ$ for complete glottic exposure. Comparing laryngoscopies in the same patient, arytenoid and glottic exposure were

LARYNGOSCOPY WITH CERVICAL SPINE STABILIZATION

accomplished with less head extension when accompanied by immobilization without traction. The change in head extension caused by traction, compared to the situation with no stabilization maneuver, was in the opposite direction of and significantly different from the change caused by immobilization ($P < 0.01$). It is unclear if these results can be extended to patients with cervical spine injuries, although our proposed mechanism for the effect of immobilization on head extension would be independent of the presence of an injury. Because it is unknown how much head and neck movement is safe during direct laryngoscopy in patients with cervical spine injuries, minimizing the movement might make the anesthesiologist more secure about not causing harm.

References

1. Crosby ET, Lui A: The adult cervical spine: Implications for airway management. *Can J Anaesth* 37:77-93, 1990
2. Hastings RH, Marks JD: Airway management for trauma patients with potential cervical spine injuries. *Anesth Analg* 73:471-482, 1991
3. Wood PR, Lawler PGP: Managing the airway in cervical spine injury: A review of the advanced Trauma Life Support protocol. *Anaesthesia* 47:792-797, 1992
4. Reid DC, Henderson R, Saboe L, Miller JDR: Etiology and clinical course of missed spine fractures. *J Trauma* 27:980-986, 1987
5. Podolsky S, Baraff LJ, Simon RR, Hoffman JR, Larmon BB, Ablon W: Efficacy of cervical spine immobilization methods. *J Trauma* 23:461-465, 1983
6. Grande C, Barton C, Stene J: Emergency airway management in trauma patients with suspected cervical spine injury. *Anesth Analg* 68:416-418, 1989
7. White A, Kander PL: Anatomical factors in difficult direct laryngoscopy. *Br J Anaesth* 47:468-474, 1975
8. Stone DJ, Gal TJ: Airway management, *Anesthesia*. Edited by Miller R. New York, Churchill Livingstone, 1990, pp 1269-1271, 1279
9. Williams KN, Carli F, Cormack RS: Unexpected difficult laryngoscopy: A prospective survey in routine general surgery. *Br J Anaesth* 66:38-41, 1991
10. Mallampati SR, Gugino LD, Desai SP, Waraksa B, Freiburger D, Lui PL: A clinical sign to predict difficult tracheal intubation: A prospective study. *Can Anaesth Soc J* 32:429-434, 1985
11. Bellhouse CP, Doré C: Criteria for estimating the likelihood of difficulty of endotracheal intubation with the Macintosh laryngoscope. *Anaesth Intensive Care* 16:329-337, 1988
12. Heck CV, Hendryson IE, Rowe CR: Joint motion, Method of Measuring and Recording. New York, Churchill Livingstone, 1966, pp 8-9, 44-45
13. Cormack RS, Lehane J: Difficult tracheal intubation in obstetrics. *Anaesthesia* 42:1105-1111, 1984
14. Horton WA, Fahy L, Charters P: Disposition of cervical vertebrae, atlanto-axial joint, hyoid and mandible during x-ray laryngoscopy. *Br J Anaesth* 63:435-438, 1989
15. Alexopoulos C, Larsson SG, Lindholm CE: Anatomic shape of the airway. *Acta Anaesthesiol Scand* 27:185-192, 1983
16. Bivins HG, Ford S, Bezmalinovic Z, Price HM, Williams JL: The effect of axial traction during orotracheal intubation of the trauma victim with an unstable cervical spine. *Ann Emerg Med* 17:25-29, 1988
17. Hastings RH, Kelley SD: Neurologic deterioration associated with airway management in a cervical spine-injured patient. *ANESTHESIOLOGY* 78:580-583, 1993
18. Aprahamian C, Thompson BM, Finger WA, Darin JC: Experimental cervical spine injury model: Evaluation of airway management and splinting techniques. *Ann Emerg Med* 13:584-587, 1984
19. Majernick TG, Bieniek R, Houston JB, Hughes HG: Cervical spine movement during orotracheal intubation. *Ann Emerg Med* 15:417-420, 1986
20. Horton WA, Fahy L, Charters P: Defining a standard intubating position using "Angle Finder." *Br J Anaesth* 62:6-12, 1989
21. Suderman VS, Crosby ET, Lui A: Elective oral tracheal intubation in cervical spine-injured adults. *Can J Anaesth* 38:785-789, 1991
22. Oates JDL, Macleod AAD, Oates PD, Pearsall FJ, Howie CJ, Murray GD: Comparison of two methods for predicting difficult intubation. *Br J Anaesth* 66:305-309, 1991