

CASE REPORTS

Anesthesiology
79:171-173, 1993
© 1993 American Society of Anesthesiologists, Inc.
J. B. Lippincott Company, Philadelphia

Severe Burn Caused by an Operating Room Light

Denis L. Bourke, M.D., * Kelvin Yee, M.D., † Lynette Mark, M.D. ‡

Today's operating rooms are equipped with numerous sophisticated devices that facilitate modern anesthesia and surgery. The anesthesiologist must constantly be alert for the potential harm these devices, or interactions among them, can cause to their patients. We describe a previously unreported complication, a full-thickness burn, caused by one of the oldest and most common operating room devices, the surgical light.

Case Report

An otherwise healthy 62-yr-old man was scheduled for radical retropubic prostatectomy surgery. The patient underwent an uneventful 4-h operation under continuous epidural anesthesia. When the Balford retractor was removed just before beginning closure of the abdominal incision, an approximately 5 × 12 cm area just to the left of the wound was exposed. The area was erythematous and consisted of a single large bulla. It appeared to be a burn. There were no other unexpected lesions. We then noticed that the one of the two operating room lights, which had been directed slightly out of the operating field onto the area where the lesion had been retracted during surgery, emitted a distinctly different, more reddish-yellow, light than the other operating room light.

The patient was examined in the postanesthetic care unit by plastic surgeons, who felt that the lesion was a partial, possibly full-thickness, burn. The burn was treated with silver sulfadiazine cream (Silvadene, Merrion Merrill Dow, Kansas City, MO), frequent dressing changes, and saline irrigation. Seven days later, when the patient was ready to be discharged, an eschar had formed at the site of the lesion (fig. 1). The patient was discharged and continued to have daily dressing

changes, irrigation, and Silvadene cream applications. Three months later, he underwent a scar excision and primary wound closure, leaving him with a 14-cm surgical scar.

Shortly after the operation was completed, we performed several simple tests to confirm our suspicions about the light. In one test, with the operating room temperature at 17° C, the suspect light and its comounted twin (with its color-correcting, heat-removing filter in place) were positioned the standard 42 inches above two pieces of black poster board. Each light was directed at a thermistor probe (Tele-Thermometer 2100, Yellow Springs Instruments, Yellow Springs, OH) placed on the pieces of poster board, and the two lights were turned on. Within 4 min, the temperature of the probe under the light without the filter had gone off the instrument's scale at 50° C. The other temperature probe, under the properly filtered light, stabilized at 32° C after 30 min. In a second test under similar conditions, the thermistor probes were placed inside a balled-up, white, water-soaked gauze surgical sponge. After 30 min, the thermistor probe in the sponge under the unfiltered light read 42° C, while the probe under the filtered light read 24° C.

Discussion

Our patient sustained a severe burn from a common operating room device, the surgical light. How could this have happened?

Several days before our patient's surgery, the lamp in the light fixture had burned out. While replacing the light, a nurse noticed that a bluish glass device (the color-correcting, heat-removing filter) within the light fixture was broken (fig. 2). The light was not used further during that operation. Afterward, a staff person from the engineering department examined the light, removed the broken filter, checked the electrical and mechanical integrity of the device, and indicated that it could be returned to service without the filter. At the time, no one appreciated the importance of the filter.

Many overhead surgical lighting fixtures use tungsten-halogen lamps as the source of light energy. These tungsten-halogen lamps emit light over a wide range of wavelengths, from as short as 300 nm, in the ultra-violet range, to as long as 4,000 nm, well into the infrared range. The wavelengths in the 800-1,400-nm infrared A band are readily absorbed by human tissue, including the skin.¹⁻³ Light in this region can transfer considerable amounts of energy to tissues, causing

* Associate Professor, Baltimore Veterans Affairs Medical Center, Department of Anesthesiology, University of Maryland.

† Resident, Department of Anesthesiology and Critical Care Medicine, The Johns Hopkins School of Medicine.

‡ Assistant Professor, Department of Anesthesiology and Critical Care Medicine, The Johns Hopkins School of Medicine.

Received from the Baltimore Veterans Affairs Medical Center, Baltimore, Maryland; The University of Maryland Medical Center, Baltimore, Maryland; and The Johns Hopkins School of Medicine, Baltimore, Maryland. Accepted for publication March 8, 1993.

Address reprint requests to Dr. Bourke: Anesthesiology, Baltimore, VAMC, 10 North Greene Street, Baltimore, Maryland 21201-1566.

Key words: Complications, burn. Equipment: operating room light.

§ AMSCO Gemini Surgical Light Technical Data Manual. Erie, American Sterilizer, 1989.

CASE REPORTS

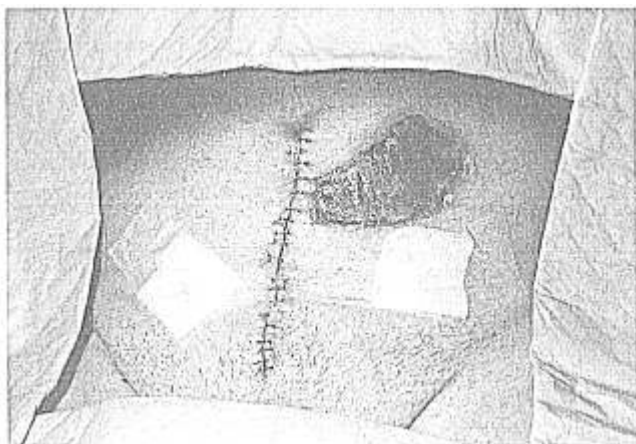


Fig. 1. Photograph, taken 7 days after surgery, of the burn caused by an unfiltered operating room light. An eschar has formed at the site of the lesion.

burns.^{1,4,5} ¶ Operating room surgical lighting devices are designed with either filters, lenses, or special reflectors that eliminate or minimize the transmission of potentially damaging infrared radiation while still producing enough light of the correct wavelengths to enable the surgeon to see and discriminate tissues in the operative field.^{5,6} The Illumination Engineering Society provides standards and testing procedures for surgical lighting devices that ensure adequate, safe lighting with the appropriate wavelengths.^{**} Testing has shown that most surgeons feel they can discriminate tissues best with light color near 5,000° K (approximately the color of noon sunlight).⁶ Illumination Engineering Society standards limit the radiant energy at a standard 42 inches from the light to have peak values of less than 25,000 $\mu\text{W} \cdot \text{cm}^{-2}$.^{**} It can be appreciated from these data that designing surgical lights that provide enough light of the desired color while meeting electrical, mechanical, and radiant energy safety standards is not a simple matter.

The lighting device (AMSCO Gemini™ Surgical Light, Model # AS48-100; American Sterilizer, Erie, PA) used in our operating room had a 200-W tungsten-halogen lamp that emitted light with wavelengths from approximately 300–4,000 nm. The light was filtered

through a borosilicate filter that passed only radiation from 350–750 nm. § The filter eliminated virtually all the infrared light and reduced radiant energy at the surgical site by a factor of ten. Eliminating the filter permitted the patient's skin to be exposed to the full visible spectrum, infrared bands A, B, and C, and, thus, nearly ten times the radiant energy that was intended. Because both the surgeon and the first assistant wore head-mounted fiberoptic lights, the overhead surgical light was not critical to visualization in the operative field and, therefore, was not moved or adjusted throughout the 4-h operation. Because the area the light happened to be focused on was next to the incision and was somewhat distorted by the Balford retractor, no one noticed the erythema or bulla developing during the procedure. Only at the end of the operation, when the retractor was removed from the wound, did the lesion become visible.

Turner *et al.* studied the effect of filtered and unfiltered tungsten-halogen light on rabbit paravertebral muscle. ¶ They adjusted the distance from the lights to provide 3,500 foot-candles at the surgical site, approximating typical operating room conditions. The radiant energies at the wound were an order of magnitude different, 0.28 and 3.28 $\mu\text{W} \cdot \text{cm}^{-2} \cdot \text{lx}^{-1}$ for the filtered and unfiltered lights, respectively. The temperature of the paravertebral muscle tissue under the unfiltered light increased 6.7° C after only 20 min, but there was no temperature increase in the muscle tissue exposed to the filtered light after 1 h. After 7 days, the muscle tissue exposed to the unfiltered light showed histologic changes consistent with accelerated repair. Tissues exposed to filtered light and tissues protected from light exposure showed no histologic changes.

There is little doubt that the injury our patient received was caused by the removal of the filter from the

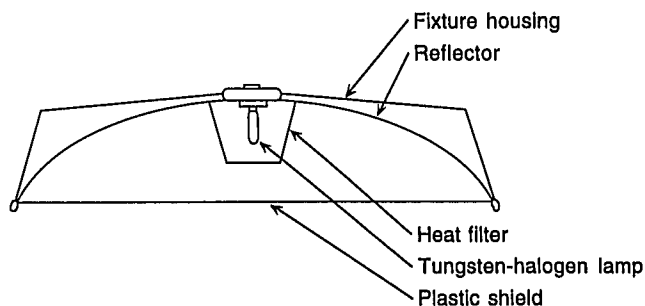


Fig. 2 Schematic diagram of the operating room light. The tungsten-halogen bulb is normally enclosed by a borosilicate, color-correcting, heat-absorbing filter.

¶ Committee on Health Care Facilities: Lighting for health care facilities, CP-29. New York, Illuminating Engineering Society, 1985, pp 15–26.

** Turner JE, Nunez LS, Shannon CJ, O'Leary RK: Effect of illumination on surgical incisions in the paravertebral muscles of rabbits. *Curr Surg* 43:287–291, 1986.

CASE REPORTS

overhead surgical light and exposure to unintended high levels of visible and infrared radiant energy. It is remarkable that such a commonplace and seemingly benign device as the surgical light could cause a large, full-thickness burn that ultimately required plastic surgical repair. This case report underscores the need for vigilance on the part of the anesthesiologist.

References

1. Stolwijk JAJ, Hardy JD: Skin and subcutaneous temperature changes during exposure to intense thermal radiation. *J Appl Physiol* 20:1006-1013, 1965
2. Hardy JD, Muschenheim C: Radiation of heat from the human body. V. The transmission of infra-red radiation through skin. *J Clin Invest* 15:1-9, 1936
3. Hardy JD, Hammel HT, Murgatroyd D: Spectral transmittance and reflectance of excised human skin. *J Appl Physiol* 9:257-264, 1956
4. Sliney DH: Biohazards of ultraviolet, visible and infrared radiation. *J Occup Med* 25:203-206, 1983
5. Beck WC, Heimburger RF: Illumination hazard in the operating room. *Arch Surg* 107:560-562, 1973
6. Beck WC: Choosing surgical illumination. *Am J Surg* 140:327-331, 1980

Anesthesiology

79:173-174, 1993

© 1993 American Society of Anesthesiologists, Inc.

J. B. Lippincott Company, Philadelphia

Profound Hypercarbia Late in the Course of Laparoscopic Cholecystectomy: Detection by Continuous Capnometry

Dennis Hall, M.D., Arthur Goldstein, M.D., Edward Tynan, C.R.N.A., Leonard Braunstein, M.D.

LAPAROSCOPIC techniques increasingly are being applied to intraperitoneal surgical procedures. Carbon dioxide insufflation into the peritoneal cavity is essential. We describe a case in which carbon dioxide insufflation caused profound hypercarbia late in the course of laparoscopic cholecystectomy. This sudden event was detected by continuous capnometry.

Case Report

An 82-yr-old woman was scheduled for a laparoscopic cholecystectomy after admission for jaundice. Medical history was significant for hypertension, treated with enalapril and hydrochlorothiazide. Past surgical and anesthetic history was noncontributory. Physical examination was remarkable only for jaundice. Laboratory evaluation and radiologic findings were consistent with extrahepatic cholestasis

secondary to gallstones. Noninvasive monitoring included an Ohmeda RGM 8250 pulse oximeter/capnometer (Madison, WI). Anesthesia was induced with 2 mg/kg propofol and 0.4 mg/kg atracurium intravenously. After tracheal intubation, anesthesia was maintained with 0.5-1.0% isoflurane, 50% N₂O, 50% O₂, and atracurium. During the 1st hour of anesthesia, the patient also received 2 mg midazolam and 100 µg fentanyl intravenously in divided doses. Sixty minutes after skin incision and carbon dioxide, insufflation was begun (75 min after anesthesia induction), end-tidal carbon dioxide was noted to have increased within 5 min, from 44 to 93 mmHg. Vital signs were stable at this time (temperature 35.0° C, pulse 72, blood pressure 130/70 mmHg, respirations with mechanical ventilation at a rate of 10 and 700 ml expiratory volume). Inspired carbon dioxide was noted to be zero. Hemoglobin oxygen saturation was 98% by pulse oximetry. An arterial blood gas revealed pH 7.02, partial pressure of oxygen 261, carbon dioxide tension 114, and bicarbonate 29.

Immediate hyperventilation by hand was begun (rate 20-25/min, expiratory volume 700-1,000 ml), and the surgical team was informed. At this time, the gallbladder was removed and peritoneal irrigation was accomplished. Several moments later it was noted that the tip of the insufflation port was no longer intraperitoneal. This was not discovered earlier because the camera had been inserted through the same port. The camera had been removed for adjustment and could not be reinserted through this port. After carbon dioxide insufflation was discontinued, end-tidal carbon dioxide returned to normal within about 10 min. Mechanical ventilation was instituted again (rate 10, expiratory volume 700 ml).

Received from the Departments of Anesthesiology and Surgery, Newcomb Medical Center, Vineland, New Jersey. Accepted for publication March 12, 1993.

Address reprint requests to Dr. Hall: 2902 Driftwood Lane, Vineland, New Jersey 08360.

Key words: Carbon dioxide; hypercarbia. Measurement techniques: capnometry. Surgery: laparoscopy.