

## REVIEW ARTICLE

Julien F. Blebyck, M.B., D.Phil., Editor

Anesthesiology  
79:144-163, 1993  
© 1993 American Society of Anesthesiologists, Inc.  
J. B. Lippincott Company, Philadelphia

# The Laryngeal Mask Airway

## Its Uses in Anesthesiology

John H. Pennant, M.A., M.B., B.S., F.R.C.Anaes.,\* Paul F. White, Ph.D., M.D., F.F.A.R.A.C.S.†

### CONTENTS

- I. Introduction
  - A. History and Development of the LMA
  - B. Physical Structure of the LMA
  - C. Cost Considerations
- II. Technical Aspects of the LMA
  - A. Insertion
    1. Preparation of the LMA
    2. Induction of Anesthesia
    3. Insertion Technique
    4. Cardiovascular Response to Insertion
  - B. LMA Position in the Pharynx
  - C. Securing the LMA in Position
  - D. Removal Technique
  - E. Sterilization and Cleaning
- III. Protection of the Airway and Aspiration with the LMA
  - A. Case Studies
  - B. Cricoid Pressure and the LMA
- IV. The Difficult Airway
  - A. Background
  - B. Blind Intubation Techniques Using the LMA
  - C. Fiberoptic Bronchoscope Techniques Using the LMA
- V. Use of the LMA in Emergencies and Cardiopulmonary Resuscitation
- VI. Experience with the LMA in Obstetric Patients
- VII. Experience with the LMA in Pediatric Patients
  - A. General Overview
  - B. Other Uses for the LMA in Children
- VIII. Other Clinical Situations in Which the LMA Has Been Used
  - A. Head and Neck Surgery
  - B. Burn Patients
  - C. Professional Singers
  - D. Intensive Care Unit
  - E. Electroencephalography Mapping Procedures
  - F. Laser Surgery to the Face
  - G. Magnetic Resonance Imaging
- IX. Advantages of the LMA
- X. Disadvantages of the LMA
- XI. Contraindications to Use of the LMA
- XII. Future Directions
- XIII. Summary

### Introduction

THE laryngeal mask airway (LMA) (Intavent International SA, Henley-on-Thames, England) is a novel device that fills the gap in airway management between tracheal intubation and use of the face mask. The LMA is inserted blindly into the pharynx, forming a low-pressure seal around the laryngeal inlet and permitting gentle positive-pressure ventilation. It allows the administration of inhaled anesthetics through a minimally stimulating airway.<sup>1-12</sup> It is relatively simple to insert and may have a useful role in management of the difficult or failed intubation.

The LMA became commercially available in the United Kingdom in 1988, and, within 12 months, was in use in more than 500 British hospitals.<sup>13</sup> The LMA is now used in more than 50% of general anesthetics administered in some centers in the United Kingdom,<sup>2</sup> and its use is increasing in many clinical settings, especially day-case surgery<sup>6,14</sup> and for short procedures in which intubation is unnecessary.<sup>14</sup>

Recently, the LMA was introduced in Australia, Japan, and North America. In August, 1991, the LMA was approved by the U.S. Food and Drug Administration. In anticipation of its widespread distribution in the U.S., it was felt that a thorough review of the current anes-

\* Assistant Professor of Anesthesiology.

† Professor and Holder of the Margaret Milam McDermott Distinguished Chair.

Received from the Department of Anesthesiology and Pain Management, University of Texas Southwestern Medical School at Dallas, Dallas, Texas. Accepted for publication March 8, 1993.

Address reprint requests to Dr. Pennant: Department of Anesthesiology and Pain Management, University of Texas Southwestern Medical School at Dallas, 5323 Harry Hines Boulevard, Dallas, Texas 75235-9068.

Key words: Complications: difficult intubation. Equipment: endotracheal tube; laryngeal mask; oral pharyngeal airway. Techniques: fiberoptic endoscopy; tracheal intubation.

## THE LARYNGEAL MASK AIRWAY

thetia literature would be helpful to the practitioner. Unfortunately, many of the published articles are in the form of anecdotal case reports or appear in nonpeer-reviewed journals. More carefully controlled studies are needed to establish the indications and contraindications for the clinical use of this new airway device.

#### History and Development of the LMA

The development of the LMA began in 1981 at the Royal London Hospital, Whitechapel, in the East End of London.<sup>1,13</sup> A British anesthesiologist, Dr. Archie Brain, suggested that the Goldman Dental Mask could be modified so as to be positioned around the laryngeal inlet rather than over the nose. Similar devices had been described a half-century earlier (*e.g.*, Leech's Pharyngeal Bulb Gasway).<sup>5,15-17</sup>

It was Dr. Brain's belief that the two methods by which the anatomical airway was commonly connected to an artificial airway were less than ideal. The most elegant way to join the two involves an end-to-end junction at the glottis. The face mask falls short because it forms this connection at the mouth and nares, and the tracheal tube goes too far, penetrating the lumen of the respiratory tree. A high lateral pressure is then applied to the delicate epithelial surface, impairing its specialized function and provoking undesirable autonomic responses.

Brain's goal was to develop a device that could rapidly overcome an obstructed airway, and, yet, be simple and atraumatic to insert. Initial studies using plaster-of-Paris casts of the cadaver pharynx indicated the optimal shape for the LMA. A prototype was used on a human patient in 1981, and a successful pilot study on 23 patients soon followed.<sup>1</sup> The LMA was first used in a failed intubation in 1983. Careful observations and clinical experience in more than 7,500 patients led to small changes in design. The availability of propofol and the development of a silicone cuff led to greater success in the use of the LMA. Initially, masks of four different sizes were manufactured (table 1). In 1991, a size 2½ LMA became available for use in older children.

#### Physical Structure of the LMA

Several refinements of Brain's original prototype have led to the current model, which is manufactured by Bivona (Chicago, IL), and distributed by Gensia Pharmaceuticals (San Diego, CA). Constructed entirely of soft medical-grade silicone rubber, so as to withstand repeated autoclaving, the size 4 device consists of a 12-mm ID internally ridged tube or shaft that is fused at a 30° angle to a distal elliptical spoon-shaped mask with an inflatable rim resembling a miniature face mask (figs. 1a, b). There is no latex in any part of the LMA.

**Table 1. Description of Different Sizes of Laryngeal Mask Airway Devices**

Mask Size	Patient Weight (kg)	Internal Diameter (ID, mm)	Length (cm)	Cuff Volume (ml)	Largest ETT (ID, mm)	FOB Size (mm)	Type of FOB That Will Pass through
1	<6.5	5.25	10	2-5	3.5	2.7	Olympus PF-27M ENF-P2 BF-N20 Pentax FB-10H FI-10P
2	6.5-20	7.0	11.5	7-10	4.5	3.5	Olympus ENF-P3 BF-3C20 Pentax FNL-15S
2½	20-30	8.4	12.5	14	5.0	4.0	Olympus LF-1
3	30-70	10	19	15-20	6.0 cuffed	5.0	Olympus BF-2TR BF-P20D
4	>70	12	19	25-30	6.5 cuffed	5.0	Pentax FB-19H FB-19H3

ETT = endotracheal tube; FOB = fiberoptic bronchoscope.

The cuff is inflated *via* a pilot balloon. The shaft opens into the concavity of the ellipse *via* a fenestrated aperture with three orifices to prevent the epiglottis from falling back and blocking the lumen (fig. 1a). A black line runs longitudinally along the posterior curvature of the shaft to aid in orientating the tube *in situ* (fig. 1b). The other four sizes of LMA (#1, 2, 2½, and 3) are scaled-down versions (table 1). Many modifications have been devised, including substitution of a flexo-metallic shaft<sup>18</sup> or a nonkinkable corrugated upper shaft for use in maxillofacial procedures, in which angulation of the tube could result in airway obstruction.<sup>19,20</sup> These modified versions of the LMA are not yet available commercially.

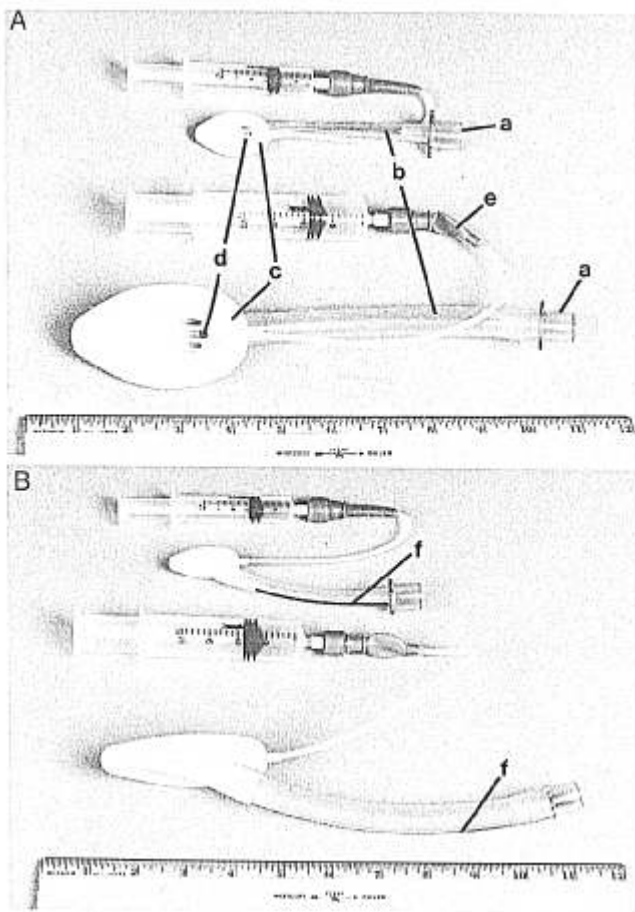


Fig. 1. (A) Anterior view of the size 1 and 4 laryngeal mask airways. *a* = standard 15 mm proximal connector; *b* = shaft; *c* = distal elliptical inflatable cuff; *d* = fenestrated opening of the shaft into the concavity of the laryngeal mask; *e* = pilot balloon. (B) Lateral view of the size 1 and 4 laryngeal mask airways. *f* = longitudinal black line running along the posterior aspect of the shaft.

### Cost Considerations

The complicated manufacturing process explains the relatively high cost of the LMA. Presently, it retails for approximately \$200 in the United States. If each device is reused even 30 times, it will prove to be financially and environmentally beneficial compared with disposable face masks and tracheal tubes. It remains to be seen whether American-trained anesthesiologists will embrace this nondisposable device.

### Technical Aspects of the LMA

#### Insertion

**Preparation of the LMA.** Before it is used in an anesthetized patient, the LMA should be carefully inspected for leaks with the cuff slightly overinflated. In addition, after removing the air from the cuff, it should remain completely deflated. Flexing the LMA 180° should not kink the shaft. Because repeated autoclaving may result in changes in its shape, the dimensions of the cuff can be measured to ensure that they fall within acceptable limits, as defined in the instruction manual.<sup>21</sup>

An LMA of the appropriate size (and one size smaller) should be available for each patient. The cuff is completely deflated while firmly applying its anterior face against a hard surface. It is crucial that the leading edge of the cuff is a smooth, wrinkle-free, rigid wedge to facilitate its passage around the posterior pharyngeal curvature and into the floor of the hypopharynx without colliding with the epiglottis. The posterior aspect of the LMA should be lubricated. Because the lubricant gel may obstruct the distal aperture or trickle into the larynx (and provoke laryngospasm), care should be taken to avoid lubricating the anterior surface of the device. There is no obvious advantage in using lidocaine gel, because this lubricant contains preservatives that may cause throat soreness or allergic reactions.<sup>21</sup>

**Induction of Anesthesia.** Insertion of the LMA requires an anesthetic depth similar to that which allows placement of an oropharyngeal airway.<sup>21</sup> The optimal induction agent would produce jaw relaxation and attenuation of airway reflexes, allowing insertion within 30–60 s of loss of consciousness. With propofol, an induction dose of 2.0–2.5 mg/kg or a blood propofol level of 6–9 µg/ml are necessary.<sup>22,23</sup> When 2.5 mg/kg propofol was compared with 4 mg/kg thiopental in two groups of 40 patients, gagging or coughing occurred in only 2/40 and 3/40 in the propofol group, compared with 12/40 and 6/40 patients, respectively,

## THE LARYNGEAL MASK AIRWAY

with thiopental.<sup>24</sup> An additional bolus of induction agent usually prevents these reflexes. Most problems occurring at induction are resolved by administering supplemental anesthetic agent, although it may be tempting to remove the device if coughing begins. Indeed, removal of the LMA often makes matters worse because airway stimulation is increased.

**Insertion Technique.** The classical intubating or "sniffing" position is recommended, with the neck flexed and head extended. This is best maintained during insertion of the LMA by having the nonintubating hand stabilize the occiput (fig. 2). The jaw may be allowed to fall open, or is held open by an assistant. Use of topical local anesthesia permits insertion in the awake patient. A recent change in insertion technique that may increase the success rate has been recommended by Brain.<sup>21</sup> With the patient's mouth open, and the distal aperture of the LMA facing anteriorly, the tip of the cuff is firmly and continuously applied against the hard palate<sup>25,26</sup> using the index finger of the right hand to guide the tube over the back of the

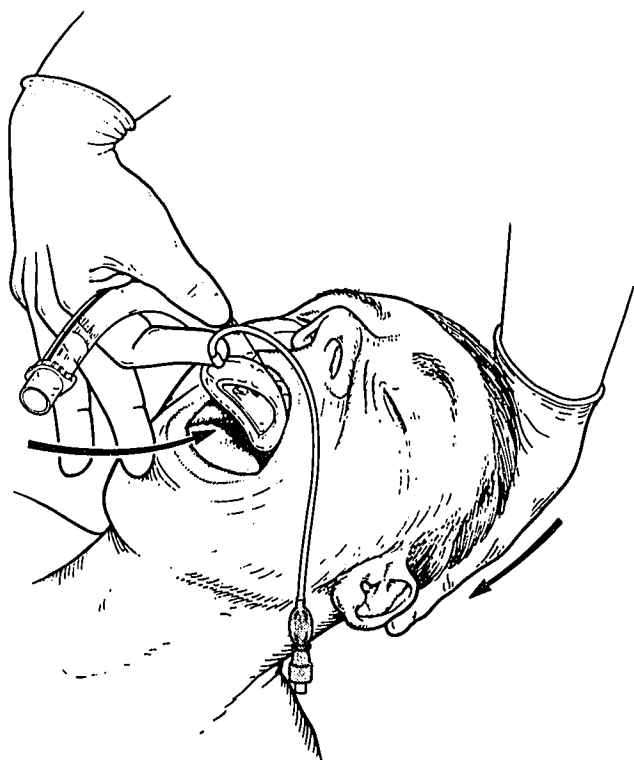


Fig. 2. With the left hand stabilizing the occiput, the posterior surface of the lubricated, deflated cuff is firmly applied against the hard palate as it is advanced into the pharynx. Reproduced with permission.<sup>21</sup>

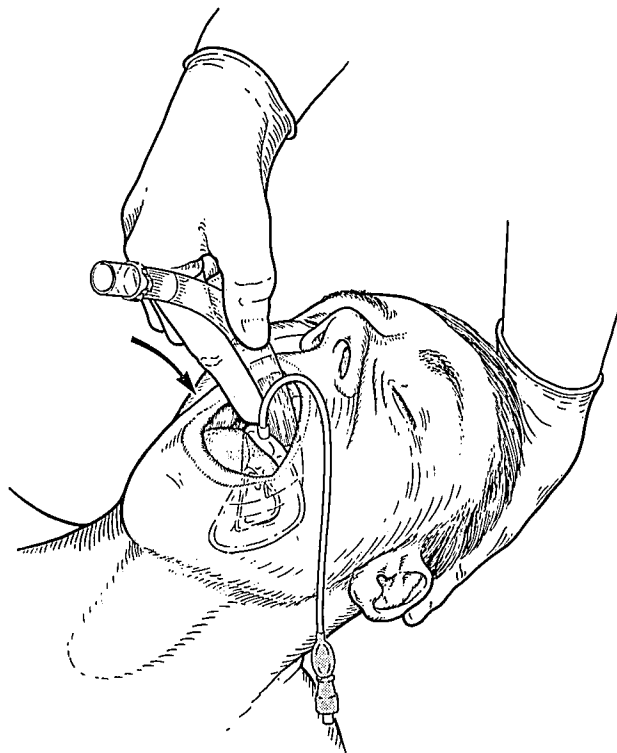


Fig. 3. The cuff is advanced into the posterior pharynx. The right index finger still firmly presses the posterior surface of the cuff against the palate. Reproduced with permission.<sup>21</sup>

tongue (figs. 3 and 4). The tube is then advanced in one smooth movement until a characteristic resistance is felt as the upper esophageal sphincter is engaged. If difficulty is encountered, a rotational movement of the tube,<sup>27</sup> slight inflation of the cuff,<sup>28</sup> a jaw thrust maneuver,<sup>29</sup> or, in rare cases, use of a laryngoscope<sup>30</sup> may be helpful. Usually, once the mask portion is in the mouth, insertion can be completed merely by firmly pushing on the connector with one finger.

Without holding the tube, the cuff is inflated with 10–30 ml of air. This usually causes a characteristic outward movement of the tube of up to 1.5 cm, as the cuff centers itself around the laryngeal inlet, and a slight forward movement of both thyroid and cricoid cartilages (fig. 5).<sup>31</sup> The longitudinal black line on the shaft of the tube should lie in the midline against the upper lip. Any deviation may indicate misplacement of the cuff and partial airway obstruction.

The 15-mm proximal connector is attached to the anesthetic circuit and either spontaneous respiration or intermittent positive pressure ventilation (IPPV) is begun. With IPPV, an audible leak at 15–20 cmH<sub>2</sub>O is common. This rarely complicates ventilation, and often

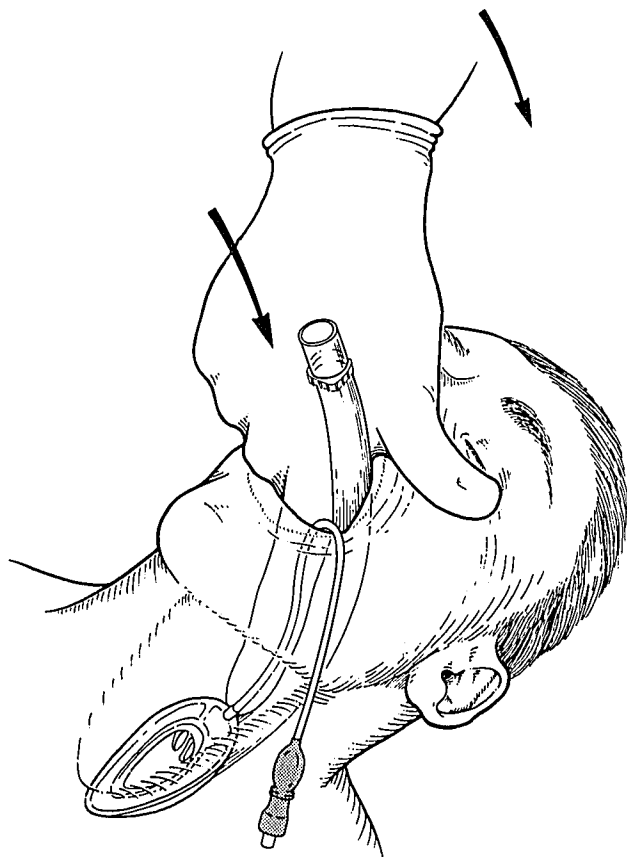


Fig. 4. The cuff is pushed into the hypopharynx. Further gentle downward pressure on the shaft or proximal connector should insure complete insertion. Reproduced with permission.<sup>21</sup>

disappears with time as the hypopharyngeal mucosa molds itself around the cuff perimeter. The LMA has been used without problems in operations of up to 7 h duration, but further studies are needed to determine how long the device can be safely left *in situ*.<sup>21</sup> Concern has been expressed about the prolonged transmission of high cuff pressures against the pharyngeal mucosa.<sup>32</sup>

Nitrous oxide diffuses into the cuff, elevating intracuff pressure to as high as 19 kPa (142 mmHg) over 20–40 min; this can dislodge the device.<sup>33</sup> Other investigators have reported a mean rise in cuff pressure of 30 mmHg over 30 min.<sup>34</sup> Cuff pressure should be monitored if nitrous oxide is used during procedures lasting longer than 1 h. Problems are managed by withdrawing about 25% of the volume from the cuff, or by using a similar nitrous oxide–oxygen mixture to inflate the cuff.

Problems on insertion (e.g., swallowing movements) most commonly result from an inadequate depth of

anesthesia. Supplemental anesthesia should be administered before attempting to reposition the device. Correct insertion on the first attempt occurs in 88–90% of patients, rising to 95–98% on the second attempt.<sup>3,7</sup> Curiously, some authors find it easier to insert the LMA with the bowl facing in a posterior direction.<sup>35,36</sup>

**Cardiovascular Response to Insertion.** Several investigators have commented on the minimal hemodynamic response to insertion of the LMA.<sup>37–42</sup> One study examined cardiovascular variables in 100 patients when either the LMA or a Guedel oral airway were inserted after a standard induction dose of propofol.<sup>39</sup> Both devices produced identical rises in blood pressure and heart rate that returned to preinsertion levels within 1 min. Another study involving 50 patients compared the pressor responses to both LMA insertion and tracheal intubation after a thiopental induction.<sup>40</sup> Both groups demonstrated a transient rise in systolic and diastolic pressures, although the increases were attenuated and

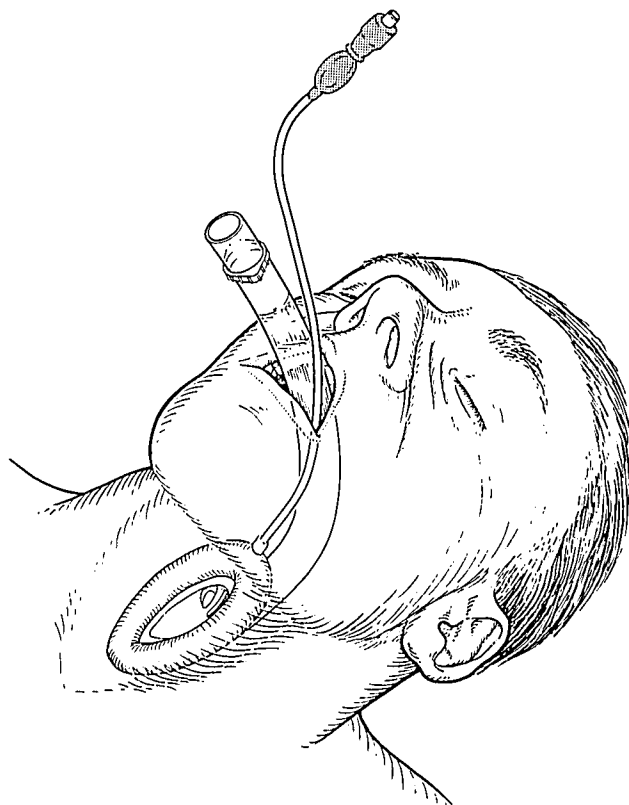


Fig. 5. Without holding the device, the cuff is inflated with the appropriate volume of air. Often, the mask will rise up about 1.5 cm as it settles into its final position. Reproduced with permission.<sup>21</sup>

## THE LARYNGEAL MASK AIRWAY

of a shorter duration in the LMA group. A subsequent study showed that the heart rate was elevated for a longer period of time after tracheal intubation compared with LMA insertion.<sup>42</sup> The authors speculate that the decreased cardiovascular response after insertion of the LMA may be related to a lack of direct laryngeal and tracheal stimulation, to lesser stimulation of the pharynx than with laryngoscopy, or to a shorter duration of direct airway stimulation (because LMA insertion is usually completed more rapidly than tracheal intubation). These minor alterations in cardiovascular dynamics may be further attenuated by superior laryngeal nerve block,<sup>43</sup> and indicate that use of the LMA could be advantageous in situations in which a marked pressor response is undesirable, such as in patients with cardiovascular or cerebrovascular disease.

### *LMA Position in the Pharynx*

When correctly positioned, the tip of the LMA cuff lies at the base of the hypopharynx against the upper esophageal sphincter, the sides lie in the pyriform fossae, and the upper border of the mask lies at the base of the tongue, pushing it forward.<sup>44</sup> The perimeter of the cuff usually forms a seal around the laryngeal inlet up to a pressure of 25 cmH<sub>2</sub>O.<sup>2</sup> The cuff is too broad to pass into the esophagus or larynx. Although the epiglottis often lies within the bowl of the LMA mask, the device functions satisfactorily even when the epiglottis adopts an upright, horizontal, or downfolded position. When grossly malpositioned, the mask may still create a useful airway.<sup>45</sup>

A radiologic investigation of 24 elderly men demonstrated epiglottic downfolding within the cuff in 66% of these cases; this was confirmed by flexible laryngoscopy.<sup>46</sup> In one case, the mask tip was folded back on itself; in another, the tip lay within the larynx, yet ventilation was clinically normal. The high incidence of epiglottic downfolding is a common finding in older men, who tend to have long, floppy epiglottides.

### *Securing the LMA in Position*

To insure that the LMA does not become dislodged during movement of the patient, the tube should be secured with tape (analogous to the endotracheal tube). A bite block prevents the patient from biting down and obstructing or damaging the LMA during emergence. Several special devices have been suggested to secure and protect the LMA, including a tracheal tube holder (Portex, Hythe, UK)<sup>47</sup> and a fiberscope bite guard.<sup>48</sup>

### *Removal Technique*

The LMA cuff protects the larynx from pharyngeal secretions, and must be kept inflated until protective reflexes return. The LMA cuff sits in an area that withstands the passage of boluses of food and liquid, and is tolerated at a light plane of anesthesia in an unstimulated patient.<sup>49</sup> Some patients will even talk with the LMA in place, or calmly remove the device themselves. Otherwise, it should be removed when the patient opens his or her mouth to command.<sup>50</sup> Controversy exists as to whether recovery-room nurses should be allowed to remove the device or whether this procedure should be left to the anesthesiologist.<sup>51-53</sup> The usual equipment for managing airway emergencies, including a suction device, must be immediately available.

### *Sterilization and Cleaning*

The LMA is manufactured of medical-grade silicone and can withstand repeated autoclaving procedures. Sterilization using glutaraldehyde, formaldehyde, or ethylene oxide is contraindicated. The manufacturers guarantee each mask for a minimum of 10 autoclavings, although some centers have masks that are functional after 250 cycles.<sup>2</sup> It may be a problem to keep track of how many usage cycles an individual LMA has undergone.<sup>54-56</sup>

The LMA should be washed with water and a mild detergent as soon as possible after extubation (*i.e.*, before secretions solidify). A pipe cleaner-type brush should be used to clean out the shaft by insertion through the distal aperture to avoid damaging the grille bars. If the cuff is not completely deflated before autoclaving, it may rupture, or the pilot tube valve may become dislodged from its seating. This valve is the most vulnerable component of the LMA (but the manufacturer will supply replacements). The device should then be autoclaved at 121–134° C for at least 3 min. At higher temperatures the tube is prone to fragmentation.<sup>54,57</sup> The life span of the LMA is prolonged by careful use and by avoiding forceful removal of the device through a partially open mouth.

### **Protection of the Airway and Aspiration with the LMA**

The LMA is contraindicated if a risk of aspiration exists, unless other techniques for securing the airway have failed. It is the potential for aspiration that has caused most concern among users of the LMA device.

The inflatable cuff does not guarantee an airtight seal to protect the larynx from vomitus. It is not an alternative to the cuffed tracheal tube, and cannot reliably isolate the airway. An uncontrolled study using fiberoptic bronchoscopy showed the esophagus to be visible within the mask in 6–9% of patients,<sup>58,59</sup> although the device's position permitted satisfactory ventilation. In these situations, the LMA is malpositioned and may produce gastric distention, which may increase the risk of regurgitation. Using Brain's modified insertion technique,<sup>21</sup> the risk of inclusion of the esophagus within the bowl of the mask may be reduced. Routine fiberoptic bronchoscopy cannot be recommended to confirm correct placement of the device.

#### Case Studies

The LMA was used without problems for emergency laparotomy in an obese patient with bowel obstruction who could not be intubated.<sup>60</sup> However, several reports have described episodes of aspiration in "fasted" patients during elective procedures.<sup>51,52,61–65</sup> In one case, aspiration occurred on emergence when the cuff was prematurely deflated.<sup>64</sup> In another, anesthesia had become too light in a patient at risk of aspiration after a femoral fracture the previous day.<sup>65</sup> Contamination of the bronchial tree was confirmed by bronchoscopy in several of these cases. Although all patients recovered, some developed severe aspiration pneumonitis.<sup>52,64,65</sup>

The bowl of the LMA may channel vomitus into the larynx in situations in which its cuff includes the esophagus. Prior use of a gastric tube may prevent these problems, although its presence may also impair the integrity of the lower esophageal sphincter and make regurgitation more likely. The effect of the use of a nasogastric tube was studied in 15 patients being ventilated with a LMA.<sup>66</sup> Although no gastric insufflation of air was detectable, the authors recommend avoiding a nasogastric tube in routine cases. Brain, on the other hand, believes that a wide-bore tube is best passed into the esophagus before inserting the LMA. Alternatively, an orogastric tube may be introduced later if the cuff is slightly deflated.<sup>21,22,67</sup>

The overall incidence of regurgitation and aspiration with the LMA is unknown. One investigation found no cases in 200 patients,<sup>9</sup> although another study reported 8 instances of regurgitation with 2 aspirations in 546 "fasted" patients.<sup>68</sup> One aspiration was mild, and the other occurred in a patient who should have been considered as having a "full stomach." Experience with

more than 7,000 patients in one center in England indicates that the incidence of regurgitation is "very low."<sup>2</sup> The incidence appears lower than in earlier reports involving paralyzed intubated patients in which 70 of 900 subjects (7.8%)<sup>69</sup> and 22 of 152 subjects (14.5%),<sup>70</sup> respectively, demonstrated "silent" regurgitation during general anesthesia. To further confuse the issue, a recent abstract studied 30 subjects and discovered a 33% incidence of regurgitation of methylene blue into the esophagus during spontaneous ventilation with the LMA, although none was noted when using a face mask and Guedel airway.<sup>71</sup> This disturbing report conflicts with the results of other investigators, who repeated the study but could not demonstrate regurgitation in any patient.<sup>72</sup>

The significance of detecting small amounts of gastric acid or methylene blue refluxing into the esophagus from the stomach is unclear. The variable figures found in the many studies may simply reflect the sensitivity of the detection techniques. Although the incidence of clinically significant regurgitation appears to be very low, a large controlled study is needed to settle this controversial issue. If the LMA is correctly inserted and positioned, no aspiration of regurgitant fluids should occur, but in those instances in which the upper esophageal sphincter is included within the bowl of the mask,<sup>58,59</sup> aspiration is a distinct possibility.

Provided that the manufacturer's recommendations are followed, the risk of aspiration using the LMA can be minimized.<sup>73</sup> It has been suggested that the operator should: (1) routinely test the cuff for defects before the operation; (2) avoid lubricating the anterior surface of the mask (lubricant may be aspirated); (3) only insert the LMA when an adequate anesthetic depth has been obtained; (4) maintain an adequate anesthetic depth throughout surgery; (5) avoid disturbing the patient during emergence; and (6) keep the cuff inflated until the patient is awake.

Should regurgitation or vomiting occur with the LMA in place, the hypopharynx should be suctioned and the LMA replaced with a tracheal tube if aspiration has occurred. Following a severe case of aspiration pneumonitis that occurred preoperatively, Nanji and Maltby recommend removal of the LMA.<sup>65</sup> They suggest that vomitus can "escape" into the oral and nasal cavities if the LMA is removed, implying that the LMA may funnel regurgitated material into the trachea. According to Brain, aspiration is detected earlier when using the LMA than with a face mask because vomitus is quickly noted welling up the transparent shaft of the LMA. He

recommends tilting the patient head-down, leaving the LMA *in situ*, and suctioning through the LMA tube.<sup>63</sup>

What about aspiration from above the LMA cuff? In contrast to the conflicting opinions regarding regurgitation of gastric contents, the findings on aspiration of pharyngeal contents are clearer. No methylene blue could be detected within the airway when it was instilled above the cuff in 64 patients,<sup>59</sup> and no barium introduced into the oropharynx was detectable in the trachea or lungs by either fiberoptic bronchoscopy or x-ray in another study.<sup>74</sup> When the LMA was employed in dental surgery, blood was visible within the bowl of the mask after its removal in only 3% of 223 cases.<sup>75</sup> However, a case report of cleft palate repair did find blood on the laryngeal aspect of the LMA.<sup>76</sup> Although these observations indicate that the LMA may be suitable for use during ENT and dental procedures, the possibility of aspiration from the esophagus remains a concern.

#### *Cricoid Pressure and the LMA*

The LMA has been successfully used in emergencies when tracheal intubation by an experienced anesthesiologist was impossible.<sup>77,78</sup> However, one report of a failed obstetric intubation stated that the LMA could not be successfully inserted when cricoid pressure was applied.<sup>79</sup> A larger study of 80 patients found that cricoid pressure did not affect the ease of intubation or the final position of the LMA. By tilting the larynx, the LMA made blind intubation (through the LMA) more difficult.<sup>80,81</sup> A more recent study showed that the LMA could only be inserted correctly in 3 of 22 patients when cricoid pressure was applied,<sup>82</sup> although ventilation with a face mask was still possible. However, muscle relaxants were not employed. It would appear that transient release of cricoid pressure aids LMA placement and subsequent intubation through the LMA. With respect to the risk of aspiration, it may be safer to maintain ventilation with a face mask using continuous cricoid pressure, rather than attempting LMA insertion, in this situation.

### **The Difficult Airway**

#### *Background*

Difficulty with tracheal intubation or the ability to maintain a patent airway occurs in 1–3% of patients and contributes to anesthetic morbidity and mortality.<sup>83,84</sup> Although the LMA was developed as an artificial airway for routine general anesthesia, it has a role in

supporting airways that are difficult to manage and as an aid to blind<sup>13,85,86</sup> and fiberoptic intubation<sup>87–90</sup> in both elective<sup>91–97</sup> and emergent situations.<sup>60,77,78,98–103</sup> The LMA has even been used as the sole means of airway support for open-heart surgery when intubation was impossible.<sup>104</sup> The advantages of the LMA are that it is easy to insert even when used by inexperienced operators,<sup>105,106</sup> and that it is positioned blindly without laryngoscopy. Interestingly, Brain suggests that the LMA is easier to insert when the larynx is more anterior, a situation in which tracheal intubation is thought to be more difficult.<sup>21,60</sup> The ability to insert the LMA without having to extend the neck indicates an additional advantage in patients with disease or instability of the cervical spine.<sup>101,107,108</sup> However, if intubation is difficult because of limitation of mouth opening (<1.5 cm), the LMA cannot be used.

Benumof suggests that the low risk/benefit ratio associated with the LMA means that it may be a suitable alternative before trans-tracheal jet ventilation is attempted in the “difficult airway management algorithm.”<sup>109</sup> Familiarity with the LMA should be obtained before attempting to use it in difficult situations, and a full range of equipment and personnel should be available if alternative means for obtaining an acceptable airway are required. Although protection against aspiration is not reliably provided by the LMA, it is probably safer, in this respect, than a face mask. Passage of the LMA in the emergency patient with a full stomach who cannot be intubated is controversial, and correct placement may be more difficult when cricoid pressure is applied (see section on Cricoid Pressure and the LMA).<sup>82</sup>

Fisher *et al.*<sup>11</sup> believe the LMA is unsuitable for elective cases in the prone or jack-knife position, although it has been successfully employed in these situations.<sup>6,13,33,110</sup> Frerk also advises caution,<sup>111</sup> because most published studies of the LMA as an aid to difficult intubation involved patients whose airways were easily managed using conventional techniques. One small prospective study concluded that the LMA is as easy to use in the difficult intubation.<sup>112</sup> A litany of case reports exist in which the LMA has been lifesaving,<sup>60,85,98,100–102,113–115</sup> and it may also facilitate tracheal intubation. Further studies are needed to define the role of the LMA in these challenging situations.

#### *Blind Intubation Techniques Using the LMA*

When the LMA is correctly inserted, its distal aperture sits directly over the laryngeal inlet, thereby allowing



tracheal intubation by a variety of blind and fiberoptic techniques in awake or anesthetized patients. Because blind intubation can be accomplished rapidly with the LMA and does not require specialized equipment, it may play a role in both elective and emergent situations, even on awake patients.<sup>88,116</sup> Placement of the LMA is facilitated if glottic reflexes can be obtunded by either deep anesthesia, topical anesthesia, or the use of muscle relaxants. Techniques for blind intubation with the LMA include the following.

1. A gum elastic bougie (GEB) with an anterior angulation of its distal tip was passed blindly through a LMA into the tracheas of two patients who experienced difficulty at intubation<sup>115</sup> and in 21 of 25 cases in another study.<sup>117</sup> Once the distal aperture of the LMA has been negotiated, the authors recommend rotating the GEB 180° to facilitate its passage into the trachea. The LMA was withdrawn and a tracheal tube "railroaded" over the GEB into the trachea. This maneuver permits removal of the LMA and the passage of any size of tracheal tube, and allows better surgical access to the oropharynx. The disadvantages are that the airway is neither protected nor controlled once the LMA has been taken out, and passage of a tracheal tube over the GEB may not be successful. The success rate in a study of 50 patients was 84–88%.<sup>117–119</sup> Malpositioning of the LMA was the usual cause of failure to successfully pass the GEB. Other investigators have reported success using this technique,<sup>120,121</sup> which has also been used in a 4-kg baby.<sup>85</sup>
2. Some investigators have refined the blind technique by passing a GEB or a guide tube into the trachea under vision with a fiberoptic bronchoscope (FOB) positioned within the LMA.
3. Brimacombe removed the distal aperture bars of the LMA and passed a GEB through the LMA into the trachea, followed by a 5.0-mm cuffed microlaryngoscopy tube (over the GEB) to allow ventilation.<sup>122,123</sup>
4. With the LMA in place, an uncut, lubricated, 6.0-mm cuffed tracheal tube can be blindly passed through the shaft of a size 3 or 4 LMA and into the trachea before the tracheal tube's cuff is inflated.<sup>86,124,125</sup> The LMA length is such that, when the tracheal tube is fully inserted, about 8 cm project beyond the distal aperture, and the upper margin of the tube cuff lies about 3 cm below the vocal

cords. The tracheal tube must be rotated 15–90° counter-clockwise<sup>22,124</sup> to allow its bevel to pass between the grille bars of the LMA distal aperture. In a study of 50 patients, 72% were intubated in an average of 13 s using this technique, and a further 12% after minor adjustments.<sup>86,124</sup> A later study performed by the same authors on 100 patients reported 90% success using this blind intubation technique.<sup>80</sup> A similar degree of success was reported using the size 1 and 2 LMA.<sup>126</sup> However, when cricoid pressure was applied (to mimic the emergency situation), this figure fell to 56%. Momentary relaxation of cricoid pressure allowed tracheal intubation in 96% of cases. Cricoid pressure increases the angle between the axes of the LMA and the trachea, making intubation more difficult. Problems were most frequent in men with large floppy epiglottides that would fold down over the laryngeal inlet. Although ventilation was normal, the floppy epiglottis provides a physical barrier to passage of the tracheal tube. Furthermore, removing the LMA with the 6.0-mm tube in place is difficult, as there is no way of stabilizing the tracheal tube as the LMA is withdrawn; the tight fit between the tracheal tube and the inner wall of the LMA shaft tends to result in extubation of the trachea. Passage of a fiberoptic bronchoscope through the tracheal tube before removal of the LMA is helpful in this situation.

These studies may be criticized for including healthy, paralyzed patients who would probably have been easily intubated using a laryngoscope. The applicability of these data to the difficult intubation scenario can only be inferred. However, three patients with a history of difficult intubations were easily intubated using this technique.<sup>124</sup> These authors suggest the rapidity with which the emergent airway can be secured with a LMA makes it a better option than the use of a face mask, and that it should be included in the failed intubation drill before a surgical airway is attempted.

#### *Fiberoptic Bronchoscope Techniques Using the LMA*

The fiberoptic bronchoscope (FOB) is often useful in the acute emergency, but is time-consuming, may be less available, and may be difficult to use when blood or secretions obscure the view. Situations in which the

## THE LARYNGEAL MASK AIRWAY

FOB may be helpful in conjunction with the LMA include the following.

1. A FOB can easily be passed through the LMA into the trachea (table 1).<sup>87,89,90,122,127</sup> Use of a tracheal tube connector with a rubber seal allows leisurely inspection of the tracheobronchial tree while keeping the patient asleep. A lubricated 6.0-mm cuffed tracheal tube premounted on the FOB can then be advanced into the trachea. The LMA cuff should be deflated after the tracheal tube cuff is inflated. If an adaptorless tracheal tube is used, the LMA can be withdrawn up the shaft of the bronchoscope before the trachea is intubated. However, leaving the LMA *in situ* permits tracheal extubation before the patient awakens. If necessary, a tube exchanger or GEB can be used to allow removal of the LMA and replacement with a larger tracheal tube.<sup>89,118,119</sup> Given the difference between the diameter of the bronchoscope and the internal diameter of the LMA shaft, little resistance to ventilation is encountered during bronchoscopy.
2. Brimacombe devised a LMA with its distal aperture bars removed and a longitudinal slit up its shaft.<sup>122</sup> A FOB with a mounted tracheal tube is passed through the LMA into the trachea; the LMA is then "peeled off" and the tube advanced over the FOB into the trachea. This allows insertion of a larger tracheal tube than when using an unmodified LMA. However, the modifications are not simple to perform and a 6.0-mm tracheal tube is satisfactory in most clinical situations.

### Use of the LMA in Emergencies and Cardiopulmonary Resuscitation

The role of the LMA when used by paramedical personnel in the initial phase of resuscitation has not been defined. Paramedics are increasingly able to perform tracheal intubation, but in difficult cases (*e.g.*, because of anatomical reasons or for fear of moving the cervical spine and causing secondary neurological damage), the LMA should be available.<sup>108</sup> Two studies have shown that personnel with no previous experience using the LMA were successful in more than 90% of cases.<sup>105,106</sup> However, all the subjects in these trials were healthy, nonobese, fasted, anesthetized adults; therefore, extrapolation to the field scenario can only be speculated.

Although one small field study confirmed these findings, no clinical information was provided regarding the 25 patients investigated.<sup>128</sup> Use of the LMA in the semi-conscious combative trauma patient with a full stomach and possible cervical spine or thoracic injury may not be helpful and may provoke vomiting. However, it may prove to be a safe alternative to the Esophageal Obturator Airway, which has serious complications and requires neck flexion for insertion.<sup>129</sup> The role of the LMA in cardiopulmonary resuscitation merits formal evaluation.<sup>13,21,101,130</sup>

### Experience with the LMA in Obstetric Patients

Although the LMA is contraindicated in patients "at risk" of regurgitation, several anecdotal accounts exist in which it proved lifesaving in cesarean sections when tracheal intubation or ventilation with a face mask were unsuccessful.<sup>77,78,98,102</sup> In each case, the LMA was quickly inserted on the first attempt. Many authors believe it should be available in the "failed intubation pack" in every delivery suite.<sup>131-133</sup> If desired, a nasogastric tube can be passed behind the LMA cuff into the esophagus to allow gastric drainage.<sup>21,63</sup>

The LMA is not a fail-safe device, and its placement may be unsuccessful even when cricoid pressure is released (see section on Cricoid Pressure and the LMA).<sup>79,113</sup> Tunstall believes it has a role in the difficult obstetric intubation when spontaneous ventilation has resumed.<sup>134</sup> Other investigators think instrumentation of the airway at this stage could provoke vomiting and risk aspiration, as cricoid pressure may have to be momentarily released to allow its successful insertion.<sup>82</sup> Similarly, if ventilation with a face mask is possible when cricoid pressure is applied, it may be safer not to attempt to use the LMA unless surgery must proceed immediately. In the worst case scenario, in which intubation and face mask ventilation of the obstetric patient are unsuccessful and spontaneous ventilation has not resumed, the LMA should be considered before the institution of cricothyroid puncture or cricothyroidotomy,<sup>100,109,135</sup> both of which may require prolonged release of cricoid pressure. Once inserted, it may then

‡ Report on Confidential Enquiries into Maternal Deaths in the United Kingdom 1985-87. London, Her Majesty's Stationery Office, 1991.

be possible to intubate the trachea with a 6.0-mm cuffed tube passed through the LMA (see section on Blind Intubation Techniques Using the LMA).<sup>124</sup> Thorough familiarity with the LMA is essential, and only a brief trial should be attempted if the procedure is unsuccessful.

### Experience with the LMA in Pediatric Patients

#### General Overview

Studies of the pediatric airway using infant cadavers led Brain to conclude that their pharyngeal anatomy was similar to that of adults, allowing scaled-down versions of the adult LMA to be developed.<sup>13</sup> Sizes 1 and 2, and, later, a size 2½ pediatric LMA have been produced (table 1). When a size 2 was used in patients weighing more than 25 kg, inflation of the stomach tended to occur; the size 3 corrected this, but was too large for some children.

Experience in adults is essential before attempting to utilize the LMA in pediatric patients, because difficulties are encountered more commonly, particularly with the size 1 LMA.<sup>136</sup> Greater anesthetic depth is required when placing the LMA in a child than when inserting an oral airway. It was recommended that the LMA should only be inserted in spontaneously breathing children, and positive pressure ventilation should be avoided. The reasons may be related to the smaller margin for error in positioning the device in children. Even when the LMA is correctly positioned, inflation of the stomach is still possible if airway inflation pressures exceed the LMA cuff seal pressure (a leak at about 20 cmH<sub>2</sub>O is usually found).<sup>137</sup> A recent prospective study involving 2,359 patients, many of whom were children who were ventilated, did not report this complication.<sup>138</sup> Dislodgement occurs more easily in children and the LMA must be securely fixed in place. Capnography is most accurate if sampling is performed at the distal end of the LMA.<sup>139</sup> Breath-holding and laryngospasm may be mistaken for incorrect positioning, but usually result from inadequate anesthesia. Tonsillar enlargement can make LMA insertion difficult.<sup>140</sup> Correct placement on the first insertion attempt occurs in 85–90% of cases, increasing to 92–98% after two attempts.<sup>140,141</sup> In a study of 48 children undergoing otological surgery, successful positioning on the first attempt occurred in 67% of cases, although the operators

had little prior experience with the pediatric LMA and performance improved with increased experience.<sup>142</sup> The most difficult aspect of insertion in children is negotiation of the posterior pharyngeal curvature. Various maneuvers may be performed to minimize this problem, including: (1) inserting the LMA laterally, rather than in the midline; (2) applying the mask firmly against the hard palate; (3) pulling the tongue forward; (4) repositioning the head; (5) adding or removing air to the cuff; (6) application of continuous positive airway pressure (CPAP); (7) use of a laryngoscope; and (8) insertion, like a Guedel oropharyngeal airway, in the "back-to-front" position before rotating 180°. <sup>35,36</sup> Difficulty occurred in 46 of 200 cases in a group of children aged 14 months to 14 yr: the rotational maneuver was successful in 56% of the initial failures, and the other maneuvers overcame the difficulty in the remainder.<sup>140</sup>

The epiglottis is included within the bowl of the LMA in 49% of children and is frequently displaced downward over the vocal cords.<sup>143</sup> This has been independently confirmed by fiberoptic laryngoscopy<sup>141</sup> and magnetic resonance imaging (MRI).<sup>137</sup> Magnetic resonance imaging confirmed some degree of epiglottic downfolding in 82% of pediatric patients, and also demonstrated that, although the cuff lay in the oropharynx (instead of the hypopharynx) in 7% of children, no interference with its normal function was evident.<sup>137</sup> McLeod *et al.* intubated 20 children with a size 1 LMA, and 20 with a size 2 LMA, and determined their position by flexible laryngoscopy.<sup>141</sup> A clear view of the larynx was possible in 25% of cases and a partial view in 25% of cases; downfolding of the epiglottis obscured the laryngeal inlet in the remaining 50% of cases. Mizushima *et al.* inserted the size 1 LMA in 50 infants.<sup>144</sup> A clinically acceptable airway was obtained in 94% of cases on the first attempt, although, on fiberoptic examination, in only 44% of instances had perfect positioning been achieved. Delayed airway obstruction developed in 12 infants. They concluded that a clinically patent airway does not guarantee ideal LMA positioning or continued airway patency in infants. Although downfolding of the epiglottis can impair blind intubation techniques,<sup>145</sup> it only interferes with ventilation in about 2% of cases. Reinsertion or use of a larger mask typically corrects the problem. It is recommended that intubation through the LMA in children should always be preceded by a fiberoptic assessment of the epiglottis position.<sup>145</sup>

## THE LARYNGEAL MASK AIRWAY

Because of its smaller size, the size 2 pediatric LMA tube may occasionally kink.<sup>146,147</sup> Partial obstruction of the LMA shaft was reported in 20–50% of pediatric patients,<sup>148</sup> although kinking with the adult LMA was detected in only 10% of cases when a fiberoptic assessment was performed.<sup>58</sup> Recent changes in the manufacturing process have decreased the likelihood of kinking.<sup>149</sup>

The largest study of LMA use in children involved 200 patients at the Hospital for Sick Children in London.<sup>140</sup> A size 2 was used in 198 cases and the size 1 was used twice. Sixteen children had known airway problems, but in only one was the LMA unsuccessful in obtaining a patent airway. There were problems in 47 cases, leading to abandonment of the technique in 5 children. Fiberoptic laryngoscopy was performed in 24 cases and epiglottic downfolding was seen in 8 (all of whom had unobstructed airways). Removal of the LMA was uneventful in 95% of cases, and the 5% in which problems were encountered during emergence from anesthesia did not require intervention. In three children, it was impossible to correctly insert the LMA after repeated attempts. The authors concluded that the LMA is a useful adjunct to upper airway management during spontaneous ventilation in pediatric patients. These investigators recommend antisialogogue premedication, insertion at an adequate depth of anesthesia, secure fixation, and use of a bite block. However, they do not consider the LMA to be the technique of choice for managing children with known airway problems. There are few reports on the use of the LMA in children younger than 3 months. Anatomical differences in the larynx of these small patients may explain the lower success rate when using the device in this subpopulation.

### *Other Uses for the LMA in Children*

**Diagnostic Fiberoptic Bronchoscopy.** A FOB can be easily passed through the LMA, avoiding nasal trauma secondary to passage through the nasopharynx.<sup>150–153</sup> It thereby avoids the need for tracheal intubation (which, itself, may cause pathological change) and allows an unimpaired dynamic view of the vocal cords. As the internal diameter of the LMA is greater than the equivalent tracheal tube that would have to be used, a larger FOB may be used, and, accordingly, a better view of the lower airway can be obtained. The space between the FOB and the inner wall of the LMA allows adequate ventilation to continue during bronchoscopy,

whereas the airway resistance may be excessive when an appropriately sized tracheal tube is used. Conventional rigid bronchoscopes with an internal diameter of less than 2.5 mm have no suction channel or tip control, and ventilation is impossible when the eyepiece is inserted. Several sizes of FOB are small enough to pass through the size 1 and 2 LMA (table 1).<sup>154</sup>

**Difficult Intubations<sup>94</sup>.** The LMA has been used for surgery in children with subglottic stenosis, in whom instrumentation of the trachea may provoke edema and worsen airway obstruction,<sup>155</sup> and for maintenance of an airway during emergency tracheostomy in a neonate with Pierre-Robin syndrome in whom tracheal intubation and ventilation with a face mask were unsuccessful.<sup>156</sup> It has been successfully inserted in four awake children with severe Pierre-Robin syndrome before induction of general anesthesia.<sup>157</sup> Passage of a guide tube through the LMA allowed blind tracheal intubation over the guide in a baby with Pierre-Robin syndrome who was difficult to intubate.<sup>85</sup> In a 30-month-old child with Pierre-Robin syndrome in whom tracheal intubation had been impossible on several occasions, causing surgery to be cancelled, a cleft palate repair was performed using a LMA.<sup>76</sup> Surgical access was impaired, but the procedure was performed satisfactorily. The LMA also proved useful for surgery in patients with juvenile-onset rheumatoid arthritis.<sup>91</sup>

**Outpatient Dental Extractions.** During maintenance of anesthesia, the incidence of hypoxia is lower and the mean arterial oxygen saturation is higher with the LMA than with the conventional nasal mask, although surgery may be prolonged because of impaired surgical access.<sup>158</sup> The LMA cuff acts as a "throat pack," preventing aspiration of blood, teeth and secretions.<sup>75</sup> It also provides a better seal than a nasal mask, allowing more precise control of anesthetic depth and less environmental pollution with anesthetic gases.

**Radiation Therapy.** For repeated treatments in small children, tracheal intubation can produce subglottic mucosal damage. Use of the LMA offers an excellent alternative to the endotracheal tube.<sup>75,159–161</sup>

**Children Undergoing Examinations under Anesthesia and Measurements of Intraocular Pressure (IOP).** Tracheal intubation and the pressure of a face mask on the globe interfere with the IOP measurements.<sup>41,162</sup> However, insertion of the LMA produced no significant change in IOP, and allowed anesthesiologists to keep their hands outside the surgical field.<sup>41</sup>

**Minor Otological Surgery.** With a LMA, children experience fewer hypoxic episodes and interruptions to surgery because of airway manipulation than with face mask anesthesia, in which jaw thrusts move the operative field.<sup>142</sup>

### Other Clinical Situations in Which the LMA Has Been Used

#### *Head and Neck Surgery*

The large shaft of the LMA impairs surgical access to the oral cavity.<sup>2</sup> However, tonsillectomy is easily performed using the LMA, because the tonsils lie above the cuff. The LMA protects the larynx from blood and secretions, making a throat pack unnecessary. The head can be turned to the side without displacing the LMA, although extreme neck flexion may obstruct the tube.<sup>21</sup> The LMA provides for a quiet recovery with minimal coughing. Prototype tubes with a flexometallic shaft are more difficult to insert, but may prevent compression by the mouth gag.<sup>18,20</sup>

Thyroidectomy procedures have been performed using the LMA. The cuff displaces the thyroid more anteriorly, facilitating surgical access.<sup>21</sup> However, some authors believe that use of the LMA is dangerous during thyroidectomy, because tracheal manipulation by the surgeon can move the larynx relative to the mask.<sup>163</sup> The LMA was successfully used in 11 of 13 thyroidectomy patients, even when tracheal deviation was present.<sup>164</sup> In one case with tracheal deviation, the LMA could not be positioned, and, in another case, an endotracheal tube had to be used when surgical manipulation of the goiter produced a large leak around the LMA cuff.<sup>164</sup> The vocal cords are easily inspected intraoperatively by passing a flexible laryngoscope through the LMA, facilitating identification of the recurrent laryngeal nerves.<sup>125,150,164-166</sup> Visualization of the vocal cords at the end of surgery avoids the need for direct laryngoscopy.

Use of the LMA is also a suitable alternative to tracheal intubation in ophthalmologic procedures, because it is associated with a lower IOP and less coughing and straining than with tracheal intubation.<sup>41,167-170</sup> When used for minor dental surgery that would otherwise be

performed using a nasal mask or tracheal intubation,<sup>75,114,171</sup> the LMA provided a satisfactory airway in 98% of 687 patients.<sup>75</sup> The LMA was also successfully used during surgical reduction of a nasal fracture.<sup>172</sup>

#### *Burn Patients*

The LMA provides a good airway for repeated dressing changes in patients with facial burns and contractures, in whom intubation may be difficult and application of a face mask would interfere with the procedure and could damage the healing burn.<sup>93,95</sup>

#### *Professional Singers*

Tracheal intubation may produce changes in the epithelial lining of the vocal cords.<sup>173</sup> An extensive double-blind comparison of the LMA and tracheal tube demonstrated a significant reduction in voice changes with the LMA. It has been suggested that the LMA has advantages over tracheal intubation for professional voice users requiring general anesthesia.<sup>164</sup>

#### *Intensive Care Unit*

Little experience exists regarding the role of the LMA in the intensive care setting, where the device may be left *in situ* for several hours (or days). One report describes intermittent insertion of the LMA under topical anesthesia to facilitate tracheal suction in an elderly hemiplegic patient who would otherwise have required a minitracheotomy.<sup>174</sup> However, carefully performed trials are needed before more widespread use of this technique in the Intensive Care Unit can be recommended.

#### *Electroencephalography Mapping Procedures*

The LMA is recommended in patients being evaluated for epilepsy surgery.<sup>175</sup> Temporal lobe electroencephalographic recordings are performed using percutaneous electrodes passed through the foramen ovale; using a face mask impairs access. The LMA provides an excellent alternative to tracheal intubation when used with intravenous sedation techniques for this short procedure.

#### *Laser Surgery to the Face*

Formal testing of the flammability of the LMA with various laser devices has not been performed. However, a study of its role in day-case anesthesia for removal of port wine stains in children showed it to be superior to the conventional face mask technique.<sup>176</sup> Because

§ Harris TM, Johnston DF, Collins SRC, Heath ML: A new general anaesthetic technique for use in singers: The Brain laryngeal mask airway versus endotracheal intubation. *J Voice* 4:81-85, 1990.

## THE LARYNGEAL MASK AIRWAY

these lesions usually occur in the periorbital area, laser requires intermittent removal of the face mask (which is flammable), allowing anesthetic gases and high levels of oxygen to flood into the operating field. The LMA reduces this fire hazard by confining the anesthetic mixture to the anesthetic circuit. However, when positive pressure ventilation is employed, some leakage of the anesthetic mixture around the LMA cuff may occur. Repeated direct laser pulses of  $10 \text{ J} \cdot \text{cm}^{-2}$  did not ignite the LMA, even when 100% oxygen or a nitrous oxide–oxygen mixture was flowing through the device. The black markings on the shaft of the tube may vaporize, but the underlying plastic remains undamaged.

### *Magnetic Resonance Imaging*

Administration of general anesthesia in the MRI scanner poses several problems for the anesthesiologist.<sup>177,178</sup> The LMA contains no ferromagnetic components and provides a suitable alternative to tracheal intubation for procedures in children.<sup>137,179</sup> It also avoids the necessity for laryngoscopes, which are magnetically attracted to the scanner and become difficult to use. The LMA is now manufactured with a tiny metallic spring in the pilot valve; this can interfere with scanning.<sup>180</sup> Spring-free LMA are available for use with MRI. Furthermore, the LMA may not be suitable if magnetic resonance spectroscopy is performed, because the resonance of some silicone-containing materials is identical to that of human tissue, impairing the interpretation of the scans.<sup>181</sup>

### **Advantages of the LMA**

Compared with the tracheal tube, sore throat is less problematic with the LMA, occurring in 4–12% of patients.<sup>3,6,9,110,182,183</sup> These figures are comparable with the incidence of sore throat for anesthetized unintubated patients,<sup>184</sup> whereas the incidence for patients who have undergone tracheal intubation may exceed 28%.<sup>182,185,186</sup> The largest survey evaluated 321 patients after a variety of procedures. Compared with a 47% incidence in patients who had their trachea intubated, mild or moderate soreness was reported by only 7% of those who had an LMA inserted, and 10% who had a face mask and oropharyngeal airway. Twenty-four hours later, 3% of the intubated group still complained of severe soreness, and none of the patients in the other

groups had any complaints.<sup>187</sup> These authors do not state whether the anesthetic gases were humidified or warmed. Dryness of the throat is reported more often with the LMA than with the face mask. Finally, the incidence of sore throat does appear to decrease with increased clinical experience in using the LMA.

The LMA frees the anesthesiologist's hands for record keeping, monitoring and drug administration. Fatigue from maintaining the airway is eliminated,<sup>188</sup> preventing deterioration of the airway over time.

The technique for using the LMA is easily learned, and quickly mastered by medical and paramedical personnel.<sup>3,105,106</sup>

Avoidance of a face mask reduces injury to the eyes and facial nerves.<sup>5</sup>

Inserting the LMA is simple, and does not require muscle relaxants or the use of a laryngoscope. Avoidance of succinylcholine may minimize postoperative myalgia, and elimination of the need for muscle relaxants may contribute to financial savings. Avoidance of laryngoscopy also reduces the risk of trauma to the lips, gums, and teeth. Coughing, laryngospasm, and stridor appear to be no more common with the LMA than when using an oropharyngeal airway. The LMA appears to be a safe and acceptable technique for day-case anesthesia.<sup>6,188,189</sup>

There is minimal cardiovascular response to insertion of the LMA.<sup>39</sup>

The LMA is better tolerated than a tracheal tube at "lighter" levels of anesthesia, and patients usually awakened before they strenuously object to its presence.

In the absence of a sizable gas leak around the LMA cuff, operating room pollution is reduced compared with a face mask,<sup>8,190</sup> particularly in edentulous or bearded patients. Sarma studied the LMA in seven subjects breathing 70% nitrous oxide through a circle system, and found that the mean  $\text{N}_2\text{O}$  level in the area of the anesthesiologist was 4.5 parts per million (ppm), far below the 25 ppm recommended by NIOSH<sup>7,191–193</sup> and comparable to levels seen with tracheal intubation. However, when IPPV was employed,  $\text{N}_2\text{O}$  levels increased and, on one occasion, reached 280 ppm.

The LMA provides a safer and more secure airway in children and adults than a face mask, with fewer episodes of hypoxia detected by pulse oximetry.<sup>7</sup>

Unlike the tracheal tube, there is minimal risk of esophageal or endobronchial intubation.

Insertion and removal of the LMA has minimal (if any) effects on IOP.<sup>41,167,168</sup>

The LMA may have a useful role in the management of difficult intubations and emergency resuscitation.

The LMA is useful in operations on professional singers, in whom tracheal intubation carries the risk of damage to the vocal cords, resulting in voice changes.

The LMA imposes less resistance to breathing compared with the corresponding tracheal tube.<sup>194</sup>

### Disadvantages of the LMA

Aspiration of gastric contents remains the most serious potential problem during the use of the LMA device.

Inflation of the stomach has occurred (especially in children) when IPPV is employed and airway pressures exceed 20 cmH<sub>2</sub>O.<sup>22,195</sup> Although the upper esophageal sphincter opening pressure is around 38 mmHg (51 cmH<sub>2</sub>O) in the awake patient, it decreases to a mean of 6 mmHg (8 cmH<sub>2</sub>O) in paralyzed, anesthetized adults.<sup>66,196</sup> One study showed that the LMA produced a sustained fall in lower esophageal sphincter pressure of 3.6 cmH<sub>2</sub>O.<sup>197</sup> Air swallowing during spontaneous ventilation with the LMA in the presence of an inadequate depth of anesthesia has also been described.<sup>198</sup> The vigilant anesthesiologist should regularly check for gastric distention.

Cuff herniation after overinflation or repeated auto-claving may lead to difficulty in placement.<sup>199</sup>

Partial airway obstruction can be detected using fiberoptic bronchoscopy in 10% of adult<sup>2</sup> and 25–50% of pediatric cases<sup>41</sup> when the LMA is in use. This is clinically unimportant in most instances, and is usually caused by downfolding of a long, floppy epiglottis.<sup>43,58</sup> Another cause of "obstruction" is laryngospasm on insertion; this usually resolves spontaneously within 20 s.<sup>2</sup> Occasionally, the inflated LMA cuff displaces the cricoid region anteriorly, producing airway obstruction secondary to large aryepiglottic folds prolapsing into the larynx.<sup>200</sup>

Coughing and laryngospasm occur about as frequently with the LMA as with an oropharyngeal airway, and are usually caused by insertion in the presence of inadequate anesthesia.<sup>43</sup>

Kinking of the pediatric-size LMA (#2) is possible, although this is less common now that the shaft is more rigid.<sup>149</sup>

Postextubation stridor has been described, but the case report involved a patient with severe chronic obstructive pulmonary disease, and may have been related

to an allergic reaction to preservatives in the lidocaine gel used for lubricating the LMA.<sup>201</sup>

Trapping of the epiglottis in the distal aperture could have resulted in severe epiglottic edema and complete obstruction. Fortunately, this complication was diagnosed by fiberoptic laryngoscopy performed because of increasing airway obstruction.<sup>159</sup>

Difficulty positioning the LMA in the presence of tonsillar hypertrophy has occurred.<sup>30</sup> This problem was easily circumvented by using a laryngoscope to help guide the LMA into the hypopharynx.

When used for dental surgery, access to the mouth is impaired and operating time may be prolonged.<sup>158</sup>

Air leakage around the cuff occurs at ventilatory pressures > 17 cmH<sub>2</sub>O if the size 3 LMA is used in a large adult,<sup>3</sup> or >20 cmH<sub>2</sub>O if the appropriate size is used.<sup>182</sup> A leak is usually seen at higher pressures in women than men.

Transient dysarthria may occur if the LMA cuff is overinflated during prolonged procedures.<sup>21</sup>

Nitrous oxide diffuses into the cuff and, with time, may cause overinflation and, eventually, displacement of the device. This may account for the gradual onset of airway obstruction in one case report.<sup>33</sup>

Uvular bruising may follow forceful attempts to pass the LMA around the posterior pharyngeal curvature.<sup>9,27</sup> This problem is avoidable if the cuff is fully deflated and lubricated. Posterior pharyngeal wall edema has been described in one child with Down's syndrome, leukemia, and oral candidiasis, occurring as a band across the area where the mucosa was compressed between the posterior surface of the LMA and the anterior border of the third cervical vertebral body.<sup>202</sup> This child had received 14 anesthetics using the LMA in a 25-day period of time.

### Contraindications to Use of the LMA

The following are contraindications to use of the LMA: (1) inability to extend the neck or open the mouth > 1.5 cm, making advancement of the LMA into the hypopharynx difficult (*e.g.*, ankylosing spondylitis, severe rheumatoid arthritis, cervical spine instability); (2) pharyngeal pathology (*e.g.*, abscess, hematoma, tissue disruption); (3) airway obstruction at or below the larynx; (4) low pulmonary compliance or high airway resistance (*e.g.*, morbid obesity, bronchospasm, pulmonary edema or fibrosis, thoracic trauma); (5) inad-

## THE LARYNGEAL MASK AIRWAY

equate depth of anesthesia to relax pharyngeal musculature; (6) increased risk of regurgitation (*e.g.*, hiatus hernia, pregnancy, "full" stomach, intestinal ileus); and (7) one-lung ventilation.

### Future Directions

A nasal LMA has been developed, and work continues in the search for the "ultimate" LMA that would also protect against aspiration. Although many specialized versions of the LMA are under investigation (including models with temperature and oximetry probes), new roles are continually found for the standard model, as experience is gained in its clinical use. Further studies are warranted to define the other indications for its use. Concern has been expressed that anesthesiologists in training will not acquire the manual skills required for airway management with a face mask, because LMA insertion has proved to be a simple and successful alternative.

### Summary

The LMA is a useful airway device for most adult and pediatric patients. It is easy and atraumatic to insert, with minimal somatic and autonomic responses from the patient. It is a suitable alternative to the face mask and to tracheal intubation in a wide variety of clinical situations. In addition, the LMA facilitates blind and fiberoptic techniques of intubation, but its role in the emergency scenario has yet to be established. The preliminary experience gained with this device in Europe and Australasia suggests that it may also transform contemporary anesthetic practice in the United States.

The authors wish to thank Drs. A. I. J. Brain and M. F. Watcha for their helpful advice and comments.

### References

- Brain AIJ: The laryngeal mask: A new concept in airway management. *Br J Anaesth* 55:801-804, 1983
- Leach AB, Alexander CA: The laryngeal mask: An overview. *Eur J Anaesthesiol Suppl* 4:19-31, 1991
- Brodrick PM, Webster NR, Nunn JF: The laryngeal mask airway. A study of 100 patients during spontaneous breathing. *Anaesthesia* 44:238-241, 1989
- Amaha K, Yasuda I, Makita K, Toyooka H: Laryngeal mask: A newly designed oral airway. *Japanese Journal of Anesthesiology* 38:1383-1394, 1989
- Maltby JR, Loken RG, Watson NC: The laryngeal mask airway: Clinical appraisal in 250 patients. *Can J Anaesth* 37:509-513, 1990
- Coyne BJ: The use of the laryngeal mask airway in day case and short stay surgery. *Ir J Med Sci* 159:185-186, 1990
- Sarma VJ: The use of a laryngeal mask airway in spontaneously breathing patients. *Acta Anaesthesiol Scand* 34:669-672, 1990
- Brattebø G, Wisborg T, Rodt SÅ: The laryngeal mask: A new tool for creating a free airway. *Nord Med* 106:109-111, 1991
- McCrirrick A, Ramage DTO, Pracilio JA, Hickman JA: Experience with the laryngeal mask airway in two hundred patients. *Anaesth Intensive Care* 19:256-260, 1991
- Maltby JR: The laryngeal mask airway. *Anesth Rev* 18:55-57, 1991
- Fisher JA, Ananthanarayan C, Edelist G: Role of the laryngeal mask in airway management (editorial). *Can J Anaesth* 39:1-3, 1992
- Benumof JL: Laryngeal mask airway: Indications and contraindications (editorial). *ANESTHESIOLOGY* 77:843-846, 1992
- Brain AIJ: The development of the laryngeal mask: A brief history of the invention, early clinical studies and experimental work from which the laryngeal mask evolved. *Eur J Anaesthesiol Suppl* 4:5-17, 1991
- Hughes JA, Gataure PS: Pattern of use of the laryngeal mask airway (letter). *Anaesthesia* 47:354, 1992
- Leech BC: The pharyngeal bulb gasway: A new aid in cyclopropane anesthesia. *Anesth Analg* 16:22-25, 1937
- Bodman R: Déjà vu (letter). *Br J Anaesth* 64:406, 1990
- Brain AIJ: Déjà vu (letter). *Br J Anaesth* 64:406, 1990
- Alexander CA: A modified Intavent laryngeal mask for ENT and dental anaesthesia (letter). *Anaesthesia* 45:892-893, 1990
- Michel MZ, Crosse MM: Modification of laryngeal mask airway (letter). *Anaesthesia* 46:422-423, 1991
- Williams PJ, Bailey PM: Comparison of the reinforced laryngeal mask airway and tracheal intubation for adenotonsillectomy. *Br J Anaesth* 70:30-33, 1993
- Brain AIJ: The Intavent Laryngeal Mask Instruction Manual, 2nd edition. Henley-on-Thames, England, Intavent International SA, 1991
- Brain AIJ: Further developments of the laryngeal mask (letter). *Anaesthesia* 44:530, 1989
- Blake DW, Donnan G, Bjorksten AR, Dawson P: Propofol induction for laryngeal mask insertion: Dose requirement and cardio-respiratory effects (abstract). *Anaesth Intensive Care* 20:108, 1992
- Brown GW, Patel N, Ellis FR: Comparison of propofol and thiopentone for laryngeal mask insertion. *Anaesthesia* 46:771-772, 1991
- Brain A: Proper technique for insertion of the laryngeal mask (letter). *ANESTHESIOLOGY* 73:1053-1054, 1990
- White DC: The laryngeal mask: A non-invasive airway. *Eur J Anaesthesiol Suppl* 4:1-4, 1991
- Lee JJ: Laryngeal mask and trauma to uvula (letter). *Anaesthesia* 44:1014, 1989
- Newman PTF: Insertion of a partially inflated laryngeal mask airway (letter). *Anaesthesia* 46:235, 1991
- Cass L: Inserting the laryngeal mask (letter). *Anaesth Intensive Care* 19:615, 1991
- van Heerden PV, Kिरrage D: Large tonsils and the laryngeal mask airway (letter). *Anaesthesia* 44:703, 1989
- Brain AIJ: Laryngeal mask and trauma to uvula (letter). *Anaesthesia* 44:1014-1015, 1989



32. Marjot R: Pressure exerted by the laryngeal mask airway cuff upon the pharyngeal mucosa. *Br J Anaesth* 70:25-29, 1993
33. Collier C: A hazard with the laryngeal mask airway (letter). *Anaesth Intensive Care* 19:301, 1991
34. Lumb AB, Wrigley MW: The effect of nitrous oxide on laryngeal mask cuff pressure. *Anaesthesia* 47:320-323, 1992
35. McNicol LR: Insertion of laryngeal mask airway in children (letter). *Anaesthesia* 46:330, 1991
36. Chow BFM, Lewis M, Jones SEF: Laryngeal mask airway in children: Insertion technique (letter). *Anaesthesia* 46:590-591, 1991
37. Alexander CA, Leach AB, Thompson AR, Lister JB: Use your Brain! (letter). *Anaesthesia* 43:893-894, 1988
38. Wood MLB, Forrest ETS: Haemodynamic response to insertion of laryngeal mask (letter). *Anaesthesia* 44:938, 1989
39. Hickey S, Cameron AE, Asbury AJ: Cardiovascular response to insertion of Brain's laryngeal mask. *Anaesthesia* 45:629-633, 1990
40. Braude N, Clements EAF, Hodges UM, Andrews BP: The pressor response and laryngeal mask insertion. A comparison with tracheal intubation. *Anaesthesia* 44:551-554, 1989
41. Watcha MF, White PF, Tyschen L, Stevens JL: Comparative effects of laryngeal mask airway and endotracheal tube insertion on intraocular pressure in children. *Anesth Analg* 75:355-360, 1992
42. Wilson IG, Fell D, Robinson SL, Smith G: Cardiovascular responses to insertion of the laryngeal mask. *Anaesthesia* 47:300-302, 1992
43. Dasey N, Mansour N: Coughing and laryngospasm with the laryngeal mask (letter). *Anaesthesia* 44:865, 1989
44. Goudsouzian NG, Denman W, Cleveland R, Shorten G: Radiologic localization of the laryngeal mask airway in children. *ANESTHESIOLOGY* 77:1085-1089, 1992
45. Molloy AR: Unexpected position of the laryngeal mask airway (letter). *Anaesthesia* 46:592, 1991
46. Nandi PR, Nunn JF, Charlesworth CH, Taylor SJ: Radiological study of the laryngeal mask. *Eur J Anaesthesiol Suppl* 4:33-39, 1991
47. Worsley MH, Howie CCM: Fixation of the laryngeal mask airway (letter). *Anaesthesia* 45:1001, 1990
48. Marks LF: Protection of the laryngeal mask airway (letter). *Anaesthesia* 45:259, 1990
49. Wilkins CJ, Cramp PGW, Staples J, Stevens WC: Comparison of the anesthetic requirement for tolerance of laryngeal mask airway and endotracheal tube. *Anesth Analg* 75:794-797, 1992
50. Brain AJ: Aspiration pneumonia and the laryngeal mask airway (letter). *Anaesthesia* 46:418, 1991
51. Wilkinson PA: The laryngeal mask. Cautionary tales (letter). *Anaesthesia* 45:167, 1990
52. Kochli N: Aspiration and the laryngeal mask airway (letter). *Anaesthesia* 46:419, 1991
53. Erskine RJ, Rabey PG: The laryngeal mask airway in recovery (letter). *Anaesthesia* 47:354, 1992
54. Crawford M, Davidson G: A problem with a laryngeal mask airway (letter). *Anaesthesia* 47:76, 1992
55. Squires SJ: Fragmented laryngeal mask airway (letter). *Anaesthesia* 47:274, 1992.
56. Squires SJ: Identification of laryngeal mask airways (letter). *Anaesthesia* 47:533, 1992
57. Woods K: A problem with a laryngeal mask airway (letter). *Anaesthesia* 47:76, 1992
58. Payne J, Edwards J: The use of the fiberoptic laryngoscope to confirm the position of the laryngeal mask (letter). *Anaesthesia* 44:865, 1989
59. John RE, Hill S, Hughes TJ: Airway protection by the laryngeal mask: A barrier to dye placed in the pharynx. *Anaesthesia* 46:366-367, 1991
60. Brain AJ: Three cases of difficult intubation overcome by the laryngeal mask airway. *Anaesthesia* 40:353-355, 1985
61. Campbell JR: The laryngeal mask: Cautionary tales (letter). *Anaesthesia* 45:167-168, 1990
62. Criswell J, John R: The laryngeal mask: Cautionary tales (letter). *Anaesthesia* 45:168, 1990
63. Brain AJ: The laryngeal mask and the oesophagus (letter). *Anaesthesia* 46:701-702, 1991
64. Griffin RM, Hatcher IS: Aspiration pneumonia and the laryngeal mask airway. *Anaesthesia* 45:1039-1040, 1990
65. Nanji GM, Maltby JR: Vomiting and aspiration pneumonitis with the laryngeal mask airway. *Can J Anaesth* 39:69-70, 1992
66. Graziotti P, Murphy D: Is a nasogastric tube useful when ventilating through laryngeal mask airway? (abstract). *Anaesth Intensive Care* 20:108-109, 1992
67. Brain AJ: The laryngeal mask in patients with chronic respiratory disease (letter). *Anaesthesia* 44:790-791, 1989
68. Cyna AM, MacLeod DM: The laryngeal mask: Cautionary tales (letter). *Anaesthesia* 45:167, 1990
69. Blitt CD, Gutman HL, Cohen DD, Weisman H, Dillon JB: "Silent" regurgitation and aspiration during general anaesthesia. *Anesth Analg* 49:707-712, 1970
70. Turndorf H, Rodis ID, Clark TS: "Silent" regurgitation during general anaesthesia. *Anesth Analg* 53:700-703, 1974
71. Barker P, Murphy P, Langton JA, Rowbotham DJ: Regurgitation of gastric contents during general anaesthesia using the laryngeal mask airway (abstract). *Br J Anaesth* 67:660P, 1991
72. El Mikatti N, Luthra AD, Healy TEJ, Mortimer AJ: Gastric regurgitation during general anaesthesia in the supine position with the laryngeal and face mask airways. *Br J Anaesth* 69:529P-530P, 1992
73. Brain AJ: Studies on the laryngeal mask: First, learn the art (letter). *Anaesthesia* 46:417-418, 1991
74. Cork RC, Kaul B, Frink EJ, Standen JR, Depa R: Comparison of laryngeal mask with endotracheal tube for airway control (abstract). *ANESTHESIOLOGY* 75(suppl):A1112, 1991
75. Young TM: The laryngeal mask in dental anaesthesia. *Eur J Anaesthesiol Suppl* 4:53-59, 1991
76. Beveridge ME: Laryngeal mask anaesthesia for repair of cleft palate. *Anaesthesia* 44:656-657, 1989
77. Chadwick IS, Vohra A: Anaesthesia for emergency Caesarean section using the Brain laryngeal airway (letter). *Anaesthesia* 44:261-262, 1989
78. de Mello WF, Kocan M: The laryngeal mask in failed intubation (letter). *Anaesthesia* 45:689-690, 1990
79. Christian AS: Failed obstetric intubation (letter). *Anaesthesia* 45:995, 1990
80. Heath ML, Allagain J: Intubation through the laryngeal mask: A technique for unexpected difficult intubation. *Anaesthesia* 46:545-548, 1991
81. Brimacombe J: Cricoid pressure and the laryngeal mask airway (letter). *Anaesthesia* 46:986-987, 1991
82. Ansermino JM, Blogg CE: Cricoid pressure may prevent insertion of the laryngeal mask airway. *Br J Anaesth* 69:465-467, 1992

## THE LARYNGEAL MASK AIRWAY

83. Latto IP, Rosen M: Difficulties in Tracheal Intubation. London, Baillière Tindall, 1985
84. Morgan M: The confidential enquiry into maternal deaths (editorial). *Anaesthesia* 41:689-691, 1986
85. Chadd GD, Crane DL, Phillips RM, Tunell WP: Extubation and reintubation guided by the laryngeal mask airway in a child with the Pierre-Robin syndrome. *ANESTHESIOLOGY* 76:640-641, 1992
86. Heath ML, Allagain J: The Brain laryngeal mask airway as an aid to intubation (abstract). *Br J Anaesth* 64:382P-383P, 1990
87. Benumof JL: Use of the laryngeal mask airway to facilitate fiberoptic-aided tracheal intubation (letter). *Anesth Analg* 74:313-315, 1992
88. Tuck M, Phillips R, Corbett J: LMA for fiberoptic bronchoscopy (letter). *Anaesth Intensive Care* 19:472-473, 1991
89. Smith JE, Sherwood NA: Combined use of laryngeal mask airway and fiberoptic laryngoscope in difficult intubation (letter). *Anaesth Intensive Care* 19:471-472, 1991
90. McNamee CJ, Meyns B, Pagliero KM: Flexible bronchoscopy via the laryngeal mask: A new technique. *Thorax* 46:141-142, 1991
91. Smith BL: Brain airway in anaesthesia for patients with juvenile chronic arthritis (letter). *Anaesthesia* 43:421-422, 1988
92. Thomson KD: Laryngeal mask airway for elective tracheostomy (letter). *Anaesthesia* 47:76, 1992
93. Russell R, Judkins KC: The laryngeal mask airway and facial burns (letter). *Anaesthesia* 45:894, 1990
94. Ravalia A, Goddard JM: The laryngeal mask and difficult tracheal intubation (letter). *Anaesthesia* 45:168, 1990
95. Thomson KD, Ordman AJ, Parkhouse N, Morgan BDG: Use of the Brain laryngeal mask airway in anticipation of difficult tracheal intubation. *Br J Plast Surg* 42:478-480, 1989
96. Logan A StC: Use of the laryngeal mask in a patient with an unstable fracture of the cervical spine (letter). *Anaesthesia* 46:987, 1991
97. Loken RG, Moir CL: The laryngeal mask airway as an aid to blind orotracheal intubation (letter). *Can J Anaesth* 39:518, 1992
98. McClune S, Regan M, Moore J: Laryngeal mask airway for Caesarean section. *Anaesthesia* 45:227-228, 1990
99. Allen JG, Flower EA: The Brain laryngeal mask. An alternative to difficult intubation. *Br Dent J* 168:202-204, 1990
100. McCrirrick A: The laryngeal mask airway for failed intubation at caesarean section (letter). *Anaesth Intensive Care* 19:135, 1991
101. Calder I, Ordman AJ, Jackowski A, Crockard HA: The Brain laryngeal mask airway: An alternative to emergency tracheal intubation. *Anaesthesia* 45:137-139, 1990
102. Storey J: The laryngeal mask for failed intubation at caesarean section (letter). *Anaesth Intensive Care* 20:118-119, 1992
103. Riley RH, Swan HD: Value of the laryngeal mask airway during thoracotomy (letter). *ANESTHESIOLOGY* 77:1051, 1992
104. White A, Sinclair M, Pillai R: Laryngeal mask airway for coronary artery bypass grafting (letter). *Anaesthesia* 46:234, 1991
105. Davies PRF, Tighe SQM, Greenslade GL, Evans GH: Laryngeal mask airway and tracheal tube insertion by unskilled personnel. *Lancet* 336:977-979, 1990
106. Pennant JH, Walker MB: Comparison of the endotracheal tube and laryngeal mask in airway management by paramedical personnel. *Anesth Analg* 74:531-534, 1992
107. Brain AJ: The laryngeal mask airway: A possible new solution to airway problems in the emergency situation. *Arch Emerg Med* 1:229-232, 1984
108. Pennant JH, Pace NA, Gajraj NM: Use of the laryngeal mask airway in the immobilized cervical spine (abstract). *ANESTHESIOLOGY* 77(suppl):A1063, 1992
109. Benumof JL: Management of the difficult adult airway: With special emphasis on awake tracheal intubation. *ANESTHESIOLOGY* 75:1087-1110, 1991
110. Miranda AF, Reddy SVG: Controlled ventilation with Brain laryngeal mask. *Med J Malaysia* 45:65-69, 1990
111. Frerk CM: Intubation through the laryngeal mask (letter). *Anaesthesia* 46:985-986, 1991
112. Mahiou P, Narchi P, Veyrac P, Germond M, Gory G, Bazin G: Is laryngeal mask easy to use in case of difficult intubation? (abstract). *ANESTHESIOLOGY* 77(suppl):A1228, 1992
113. Freeman R, Baxendale B: Laryngeal mask airway for Caesarean section (letter). *Anaesthesia* 45:1094-1095, 1990
114. Kendall N: The Brain laryngeal mask: An alternative to difficult intubation (letter). *Br Dent J* 168:278, 1990
115. Chadd GD, Ackers JWL, Bailey PM: Difficult intubation aided by the laryngeal mask airway (letter). *Anaesthesia* 44:1015, 1989
116. Brimacombe JR: LMA in awake fiberoptic bronchoscopy (letter). *Anaesth Intensive Care* 19:472, 1991
117. Allison A, McCrory J: Tracheal placement of a gum elastic bougie using the laryngeal mask airway (letter). *Anaesthesia* 45:419-420, 1990
118. Sellers WFS, Edwards RJ: Awake intubation with Brain laryngeal mask (letter). *Anaesth Intensive Care* 19:473, 1991
119. Hasham F, Kumar CM, Lawler PGP: The use of the laryngeal mask airway to assist fiberoptic orotracheal intubation (letter). *Anaesthesia* 46:891, 1991
120. McCrirrick A, Pracilio JA: Awake intubation: A new technique. *Anaesthesia* 46:661-663, 1991
121. Carey MF, Smith J, Cooney CM: Laryngeal mask to aid tracheal intubation (letter). *Anaesthesia* 46:1083, 1991
122. Brimacombe J, Johns K: Modified Intavent LMA (letter). *Anaesth Intensive Care* 19:607, 1991
123. Brimacombe J: Training in fiberoptic laryngoscopy (letter). *Br J Anaesth* 67:503, 1991
124. Heath ML: Endotracheal intubation through the laryngeal mask: Helpful when laryngoscopy is difficult or dangerous. *Eur J Anaesthesiol Suppl* 4:41-45, 1991
125. Tanigawa K, Inoue Y, Iwata S: Protection of recurrent laryngeal nerve during neck surgery: A new combination of neutracer, laryngeal mask airway, and fiberoptic bronchoscope (letter). *ANESTHESIOLOGY* 74:966-967, 1991
126. White AP, Billingham IM: Laryngeal mask guided tracheal intubation in paediatric anaesthesia (letter). *Paediatric Anaesthesia* 2:265, 1992
127. Silk JM, Hill HM, Calder I: Difficult intubation and the laryngeal mask. *Eur J Anaesthesiol Suppl* 4:47-51, 1991
128. de Mello WF, Ward P: The use of the laryngeal mask airway in primary anaesthesia (letter). *Anaesthesia* 45:793-794, 1990
129. Schwartz AJ, Campbell FW: *Cardiopulmonary resuscitation, Clinical Anesthesia*. Edited by Barash PG, Cullen BF, Stoelting RK. Philadelphia, JB Lippincott, 1989, pp 1477-1515
130. Tighe SQM, Greenslade GL, Davies PRF, Evans GH: Use of the laryngeal mask airway in primary care (letter). *Anaesthesia* 46:163, 1991
131. de Mello WF: Management of failed endotracheal intubation

- at caesarean section (letter). *Anaesth Intensive Care* 19:303–304, 1991
132. Reynolds F: Tracheostomy in obstetric practice: How about the laryngeal mask airway? (letter). *Anaesthesia* 44:870, 1989
  133. McClune S, Moore JA: The laryngeal mask in failed intubation (letter). *Anaesthesia* 45:690, 1990
  134. Tunstall ME: Failed intubation in the parturient (editorial). *Can J Anaesth* 36:611–613, 1989
  135. O'Sullivan G, Stoddart PA: Failed tracheal intubation (letter). *Br J Anaesth* 67:225, 1991
  136. Dubreuil M, Laffon M, Plaud B, Penon C, Ecoffey C: Incidence of complications with size 1 laryngeal mask (abstract). *ANESTHESIOLOGY* 77(suppl):A1174, 1992
  137. Goudsouzian NG, Denman W, Cleveland R, Shorten G: Radiologic localization of the laryngeal mask airway in children. *ANESTHESIOLOGY* 77:1085–1089, 1992
  138. Vergese C, Smith TGC, Young E: Prospective survey on the use of the laryngeal mask airway in 2359 patients. *Anaesthesia* 48:58–60, 1993
  139. Spahr-Schopfer I, Bissonnette B, Hartley E: Capnography and the laryngeal mask airway in children (abstract). *Can J Anaesth* 39:A135, 1992
  140. Mason DG, Bingham RM: The laryngeal mask airway in children. *Anaesthesia* 45:760–763, 1990
  141. McLeod DH, Narang VPS: Functional and anatomical assessment of the laryngeal mask airway in infants and children. *Anaesth Intensive Care* 20:109, 1992
  142. Johnston DF, Wrigley SR, Robb PJ, Jones HE: The laryngeal mask airway in paediatric anaesthesia. *Anaesthesia* 45:924–927, 1990
  143. Rowbottom SJ, Simpson DL, Grubb D: The laryngeal mask airway in children: A fiberoptic assessment of positioning. *Anaesthesia* 46:489–491, 1991
  144. Mizushima A, Wardall GJ, Simpson DL: The laryngeal mask airway in infants. *Anaesthesia* 47:849–851, 1992
  145. Dubreuil M, Ecoffey C: Laryngeal mask guided tracheal intubation in paediatric anaesthesia (letter). *Paediatric Anaesthesia* 2:344, 1992
  146. Goldberg PL, Evans PF, Filshie J: Kinking of the laryngeal mask airway in two children (letter). *Anaesthesia* 45:487–488, 1990
  147. Wilson IG, Eastley R: A modification of the laryngeal mask airway (letter). *ANESTHESIOLOGY* 74:1157, 1991
  148. Rowbottom SJ, Simpson DL: Partial obstruction of the laryngeal mask airway (letter). *Anaesthesia* 45:892, 1990
  149. Martin DW: Kinking of the laryngeal mask airway in two children (letter). *Anaesthesia* 45:488, 1990
  150. Rowbottom SJ, Morton CPJ: Diagnostic fiberoptic bronchoscopy using the laryngeal mask (letter). *Anaesthesia* 46:161, 1991
  151. Walker RWM, Murrell D: Yet another use for the laryngeal mask airway (letter). *Anaesthesia* 46:591, 1991
  152. Mackawa N, Mikawa K, Tanaka O, Goto R, Obara H: The laryngeal mask may be a useful device for fiberoptic airway endoscopy in pediatric anaesthesia (letter). *ANESTHESIOLOGY* 75:169–170, 1991
  153. Thomas F: Masque laryngé pour fibroscopie chez l'enfant (letter). *Ann Fr Anesth Reanim* 10:495, 1991
  154. Ovassapian A: *Fiberoptic Airway Endoscopy in Anesthesia and Critical Care*. New York, Raven Press, 1990, pp 7–8
  155. Asai T, Fujise K, Uchida M: Use of the laryngeal mask in a child with tracheal stenosis. *ANESTHESIOLOGY* 75:903–904, 1991
  156. Denny NM, DeSilva KD, Webber PA: Laryngeal mask airway for emergency tracheostomy in a neonate (letter). *Anaesthesia* 45:895, 1990
  157. Markakis DA, Sayson SC, Schreiner MS: Insertion of the laryngeal mask airway in awake infants with the Robin sequence. *Anesth Analg* 75:822–824, 1992
  158. Bailie R, Barnett MB, Fraser JF: The Brain laryngeal mask: A comparative study with the nasal mask in paediatric dental outpatient anaesthesia. *Anaesthesia* 46:358–360, 1991
  159. Miller AC, Bickler P: The laryngeal mask airway: An unusual complication. *Anaesthesia* 46:659–660, 1991
  160. Taylor DH, Child CSB: The laryngeal mask for radiotherapy in children (letter). *Anaesthesia* 45:690, 1990
  161. Grebenik CR, Ferguson C, White A: The laryngeal mask airway in pediatric radiotherapy. *ANESTHESIOLOGY* 72:474–477, 1990
  162. Watcha MF, Chu FC, Stevens JL, White PF: Intraocular pressure and hemodynamic changes following tracheal intubation in children. *J Clin Anesth* 3:310–313, 1991
  163. Charters P, Cave-Bigley D, Roysam CS: Should a laryngeal mask be routinely used in patients undergoing thyroid surgery? (letter). *ANESTHESIOLOGY* 75:918–919, 1991
  164. Greatorex RA, Denny NM: Application of the laryngeal mask airway to thyroid surgery and the preservation of the recurrent laryngeal nerve. *Ann R Coll Surg Engl* 73:352–354, 1991
  165. Akhtar TM: Laryngeal mask airway and visualisation of vocal cords during thyroid surgery (letter). *Can J Anaesth* 38:140, 1991
  166. Tanigawa K, Inoue Y, Iwata S: Should a laryngeal mask be routinely used in patients undergoing thyroid surgery? (letter). *ANESTHESIOLOGY* 75:919, 1991
  167. Akhtar TM, Kerr WJ, Kenny GNC: Comparison of laryngeal mask airway with tracheal intubation for intraocular surgery (abstract). *Br J Anaesth* 67:215P, 1991
  168. Holden R, Morsman CDG, Butler J, Clark GS, Hughes DS, Bacon PJ: Intraocular pressure changes using the laryngeal mask airway and tracheal tube. *Anaesthesia* 46:922–924, 1991
  169. Akhtar TM, McMurray P, Kerr WJ, Kenny GNC: A comparison of laryngeal mask airway with tracheal tube for intra-ocular ophthalmic surgery. *Anaesthesia* 47:668–671, 1992
  170. Lamb K, James MFM, Janicki PK: The laryngeal mask airway for intraocular surgery: Effects on intraocular pressure and stress responses. *Br J Anaesth* 69:143–147, 1992
  171. Noble H, Wooler DJ: Laryngeal masks and chair dental anaesthesia (letter). *Anaesthesia* 46:591, 1991
  172. Bing J: Masque laryngé pour réduction de fracture du nez (letter). *Ann Fr Anesth Reanim* 10:494, 1991
  173. Peppard SB, Dickens JH: Laryngeal injury following short-term intubation. *Ann Otol Rhinol Laryngol* 92:327–330, 1983
  174. Lim W: Yet another use for the laryngeal mask (letter). *Anaesthesia* 47:175–176, 1992
  175. Ammar T, Towey RM: The laryngeal mask airway (letter). *Anaesthesia* 45:75, 1990
  176. Garbin GS, Bogetz MS, Grekin RC, Frieden IJ: The laryngeal mask as an airway during laser treatment of port wine stains (abstract). *ANESTHESIOLOGY* 75(suppl):A953, 1991
  177. Menon DK, Peden CJ, Hall AS, Sargentoni J, Whitwam JG: Magnetic resonance for the anaesthetist. *Anaesthesia* 47:240–255, 1992
  178. Sury MRJ, Johnstone G, Bingham RM: Anaesthesia for magnetic resonance imaging of children. *Paediatric Anaesthesia* 2:61–68, 1992
  179. Rafferty C, Burke AM, Cossar DF, Farling PA: Laryngeal mask

## THE LARYNGEAL MASK AIRWAY

and magnetic resonance imaging (letter). *Anaesthesia* 45:590-591, 1990

180. Langton JA, Wilson I, Fell D: Use of the laryngeal mask airway during magnetic resonance imaging (letter). *Anaesthesia* 47:532, 1992

181. Fairfield JE: Laryngeal mask and magnetic resonance: A caution (letter). *Anaesthesia* 45:995, 1990

182. Brain AJ, McGhee TD, McAteer EJ, Thomas A, Abu-Saad MAW, Bushman JA: The laryngeal mask airway: Development and preliminary trials of a new type of airway. *Anaesthesia* 40:356-361, 1985

183. Reddy SVG, Win N: Brain laryngeal mask: Study in 50 spontaneously breathing patients. *Singapore Med J* 31:338-340, 1990

184. Jensen PJ, Hommelgaard P, Søndergaard P, Eriksen S: Sore throat after operation: Influence of tracheal intubation, intracuff pressure and type of cuff. *Br J Anaesth* 54:453-456, 1982

185. Brindle GF, Soliman MG: Anaesthetic complications in surgical out-patients. *Can Anaesth Soc J* 22:613-619, 1975

186. Jones MW, Catling S, Evans E, Green DH, Green JR: Hoarseness after tracheal intubation. *Anaesthesia* 47:213-216, 1992

187. Alexander CA, Leach AB: Incidence of sore throats with the laryngeal mask (letter). *Anaesthesia* 44:791, 1989

188. Smith I, White PF: Use of the laryngeal mask airway as an alternative to a face mask during outpatient arthroscopy. *ANESTHESIOLOGY* 77:850-855, 1992

189. Goodwin APL, Rowe WL, Ogg TW: Day case laparoscopy: A comparison of two anaesthetic techniques using the laryngeal mask during spontaneous breathing. *Anaesthesia* 47:892-895, 1992

190. Barnett R, Gallant B, Fossey S, Finegan B: Nitrous oxide environmental pollution: A comparison between face mask, laryngeal mask and endotracheal intubation (abstract). *Can J Anaesth* 39:A151, 1992

191. National Institute for Occupational Safety and Health: Criteria for a Recommended Standard: Occupational Exposure to Waste Anesthetic Gases and Vapors. Cincinnati: US Department of Health, Education and Welfare, 1977: DHEW Publication No. (NIOSH), pp 77-140

192. Sarma VJ, Leman J: Laryngeal mask and anaesthetic waste gas concentrations (letter). *Anaesthesia* 45:791-792, 1990

193. Boström U, Sarma J: Laryngeal mask: A new method for free airways in anesthesia and emergency care. *Lakartidningen* 88:2375-2376, 1991

194. Bhatt SB, Kendall AP, Lin ES, Oh TE: Resistance and additional inspiratory work imposed by the laryngeal mask airway: A comparison with tracheal tubes. *Anaesthesia* 47:343-347, 1992

195. Wittmann PH, Wittmann FW: Laryngeal mask and gastric dilatation (letter). *Anaesthesia* 46:1083, 1991

196. Vanner RG, O'Dwyer JP, Pryle BJ, Reynolds F: Upper oesophageal sphincter pressure and the effect of cricoid pressure. *Anaesthesia* 47:95-100, 1992

197. Rabey PG, Murphy PJ, Langton JA, Barker P, Rowbotham DJ: Effect of the laryngeal mask airway on lower oesophageal sphincter pressure in patients during general anaesthesia. *Br J Anaesth* 69:346-348, 1992

198. Brimacombe JR: Laryngeal mask anaesthesia and recurrent swallowing. *Anaesth Intensive Care* 19:275-276, 1991

199. Welsh BE: Will we ever learn? (letter). *Anaesthesia* 45:892, 1990

200. Dubreuil M, Janvier G, Dugrais G, Berthoud MC: Uncommon laryngeal mask obstruction (letter). *Can J Anaesth* 39:517-518, 1992

201. Gunawardene RD: Laryngeal mask and patients with chronic respiratory disease (letter). *Anaesthesia* 44:531, 1989

202. Marjot R: Trauma to the posterior pharyngeal wall caused by a laryngeal mask airway (letter). *Anaesthesia* 46:589-590, 1991