

this time, it has been used to diagnose fatal reactions to penicillin, muscle relaxants,<sup>11</sup> and thiopental.<sup>12</sup>

## REFERENCES

1. Doenicke A, Lorenz W, Stanworth D, Duka T, Glen JB: Effects of propofol on histamine release, immunoglobulin levels and activation of complement in healthy volunteers. *Postgrad Med* 61:15-20, 1985
2. Laxenaire MC, Kamel L, Zeravi Z, Manel J, Bois JP: Histamine-liberation non spécifique et propofol. *Ann Fr Anesth Reanim* 6:230-232, 1987
3. Laxenaire MC, Gueant JL, Bermejo E, Mouton C: Anaphylactic shock due to propofol. *Lancet* 2:739-740, 1988
4. Laxenaire MC, Gueant JL, Moneret-Vautrin DA, Motin J, Larget S, Lepointe F, Rossi A: Anaphylactic shock to propofol at the time of first exposure. *Ann Fr Anesth Reanim* 9:R125, 1990
5. Naquib M: Anaphylactoid reactions following propofol-atracurium sequence. *Can J Anaesth* 36:358-359, 1989
6. Aitken HA: Weals after propofol. *Anaesthesia* 43:170, 1988
7. Jamieson V, Mackenzie J: Allergy to propofol? *Anaesthesia* 43:70, 1988
8. Stoelting RK: Allergic reactions during anesthesia. *Anesth Analg* 62:341-346, 1983
9. Fox GS, Wilkinson RD, Rabow FI: Thiopental anaphylaxis. A case and a method of diagnosis. *ANESTHESIOLOGY* 35:655-657, 1971
10. Fisher MM, Baldo BA, Silbert BS: Anaphylaxis during anesthesia: Use of radioimmunoassays to determine etiology and drugs responsible in fatal cases. *ANESTHESIOLOGY* 75:1112-1115, 1991
11. Baldo BA, Fisher MM: Anaphylaxis to muscle relaxant drugs: Cross-reactivity and molecular basis of binding of IgE antibodies detected by radioimmunoassay. *Mol Immunol* 20:1393-1400, 1983
12. Harle DG, Baldo BA, Fisher MM: The molecular basis of IgE antibody binding to thiopentone: Binding of IgE from thiopentone-allergic and non-allergic subjects. *Mol Immunol* 27:853-858, 1990

Anesthesiology  
77:386-388, 1992

## Kartagener's Syndrome: Anesthetic Considerations

ANTHONY M.-H. HO, M.S., P.E., M.D., F.R.C.P.C.,\* MICHAEL J. FRIEDLAND, M.B., F.R.C.P.C.†

Kartagener's Syndrome is a rare disorder characterized by situs inversus, including dextrocardia, and primary ciliary dyskinesia resulting in chronic respiratory tract infections, bronchiectasis, and sinusitis.<sup>1</sup>

We present, to our knowledge, the first recorded case in the English literature of anesthetic management of a patient with Kartagener's Syndrome.

## CASE REPORT

A 68-yr-old woman was admitted to the hospital for bleeding colonic polyps and gingiva. The patient was diagnosed as having Kartagener's Syndrome; this diagnosis was based in part on clinical findings of situs inversus, including dextrocardia, recurrent respiratory infection, bi-

lateral predominantly basal bronchiectasis, chronic ear infections, and occasionally, bronchospasm. She had a history of recurrent atrial fibrillation, hypertension, and diabetes mellitus and was receiving Coumadin, diltiazem, and captopril. She had a cough productive of yellowish phlegm. Chest examination revealed rales at both lung bases and diffuse bronchospasm. Her admission coagulation profile was abnormal (international normalized ratio 3.7, activated partial thromboplastin time 55 s). The preoperative electrocardiogram done with leads normally placed showed abnormal limb and precordial leads (fig. 1A). A normal ECG emerged when all the leads were reversed (fig. 1B). Spirometry showed a moderate obstructive pattern. The chest x-ray revealed cystic bronchiectasis at both lung bases and dextrocardia.

The patient received vitamin K and several days of chest physiotherapy and bronchodilator and antibiotic treatment before undergoing resection of what then was revealed to be an adenocarcinoma of the colon.

Premedication consisted of oxazepam, morphine, and scopolamine. Before the induction of anesthesia, a lumbar epidural catheter was placed for postoperative pain management. A radial arterial monitor was inserted. A central venous catheter was placed in the left internal jugular vein, according to the assumption that the great vessels and the thoracic duct were mirror images of normal. Despite the patient's prominent front teeth and a mild micrognathia, visualization of the larynx was not difficult during awake laryngoscopy under topical anesthesia. Anesthesia then was induced, and the patient's trachea was intubated and her lungs mechanically ventilated. The humidification of the inspired gases was maintained with a heat and humidity exchanger (Thermavent®). Bronchoscopy was performed and showed that the tracheal and bronchial mucosa were grossly normal. The left main stem bronchus was found to be slightly more in the caudad-cephalad direction than on the right. The first lobar bronchus on the left main was at about 2-3 cm from the carina, and the first lobar bronchus

\* Assistant Clinical Professor of Anesthesia, McMaster University School of Medicine; Staff Anesthetist, Trauma Team Leader, Hamilton Civic Hospitals, Hamilton, Ontario, Canada.

† Associate Staff Anesthetist, Women's College Hospital, Toronto, Ontario, Canada.

Received from Hamilton Civic Hospitals, Hamilton, and Women's College Hospital, Toronto, Ontario, Canada. Accepted for publication April 1, 1992.

Address reprint requests to Dr. Ho: Department of Anesthesia, Hamilton Civic Hospitals, 237 Barton Street East, Hamilton, Ontario, L8L 2X2, Canada.

Key words: Complications: dextrocardia; Kartagener's Syndrome; bronchiectasis; situs inversus.

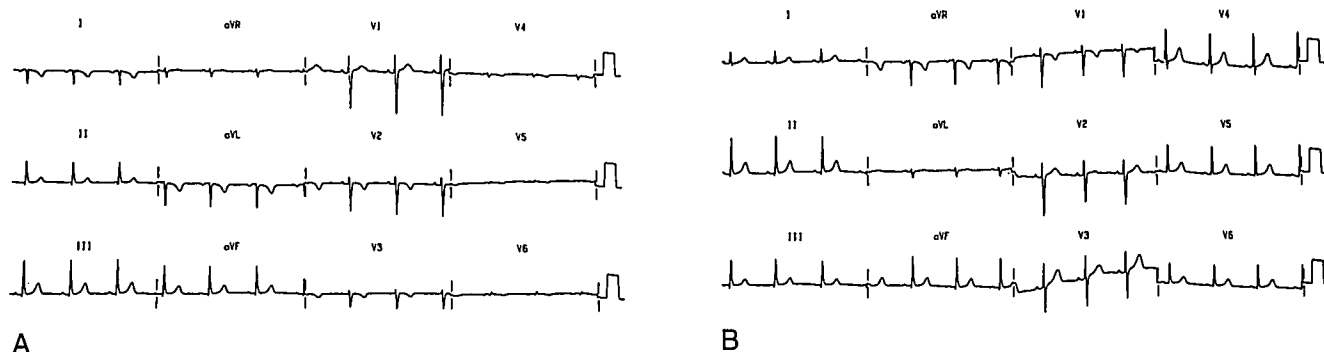


FIG. 1. A: The patient's ECG taken with all leads in standard locations. B: The patient's ECG taken with all leads in mirror locations of standard.

from the right main stem bronchus was at about 4–5 cm. Therefore, the lungs were inverted as well.

The anesthetic and surgery proceeded smoothly. The patient's trachea was extubated at the end of the case. For upper airway patency, an oropharyngeal airway was chosen over a nasal one because this patient was already prone to infections of her ears and paranasal sinuses. Supplemental oxygen was humidified, since drying of her airway secretions would have further impaired clearance. Postoperative analgesia with epidural morphine was highly satisfactory. The patient made an uneventful recovery.

# DISCUSSION

The prevalence of situs inversus varies from 1:6,800 to 1:35,000 in Europe and the United States,<sup>2</sup> 1:5,000 in Israel,<sup>2</sup> and 1:4,100 in Japan.<sup>2,3</sup> About 20% of all persons with situs inversus have bronchiectasis, and almost as many have chronic paranasal sinusitis to complete the syndrome described by Siewart in 1904<sup>1</sup> and by Kartagener in 1933.<sup>1</sup> Kartagener's Syndrome accounts for possibly half of all patients with primary ciliary dyskinesia.<sup>4</sup> These patients have a congenital defect in the synthesis of the protein dynein.<sup>1,4,5</sup> The overall effect is reduced ciliary beat frequency and waveforms that are invariably abnormal—uncoordinated multiplanar beats with no evidence of metachronicity.<sup>6</sup> It has been postulated that visceral rotation, which occurs between days 10 and 15 of gestation, is the result of propulsion by visceral epithelial cilia. Thus, in people with ciliary motility impairment, the visceral orientation occurs at random; some 50% of them have situs inversus.<sup>4</sup>

Impaired mucociliary transport leads to recurrent respiratory tract infections (sinusitis, bronchitis, pneumonia, otitis media) that can be traced back to early childhood or even infancy.<sup>7</sup> Neonatal respiratory distress is not uncommon.<sup>8</sup> Bronchiectasis, usually in dependent parts of the lungs, often develops during childhood and adolescence.<sup>7</sup> Chest radiographic findings may include hyperinflation, bronchial wall thickening, segmental atelectasis, bronchiectasis, or consolidation.<sup>9</sup> Spirometry usually reveals an obstructive pattern but occasionally reveals a restrictive impairment due to resection surgery for bronchiectasis.<sup>1</sup> In situs inversus, by definition, the lungs also

are inverted, even though clear documentation of such is scarce.<sup>1,10,11</sup>

In most cases of Kartagener's Syndrome, dextrocardia is the only cardiac abnormality.<sup>12</sup> Rarely, one or more associated cardiac abnormalities are present, such as transposition of the great arteries and trilobular or bilobular heart.<sup>13</sup> Isolated dextrocardia with abdominal viscera in normal positions (situs solitus) is invariably associated with various combinations of severe cardiac malformations, the commonest being ventricular inversion, single ventricle, pulmonary stenosis, abnormalities of the atrioventricular valves, and anomalies of systemic and pulmonary venous return.<sup>14</sup> Dextrocardia must be distinguished from a right-sided heart due to rotation, intrathoracic abnormalities, or other causes.<sup>12</sup>

This case demonstrates in part the anesthetic concerns of patients with Kartagener's Syndrome. Preoperatively, the pulmonary status should be managed by chest physiotherapy, and any infections should be treated. Bronchiectasis can progress to cor pulmonale, pulmonary edema, and amyloidosis, none of which, fortunately, was present in our patient. Humidification of inspired gases should be beneficial to the clearance of mucus. The ECG changes in mirror image dextrocardia are inverted lead I, interchanged leads II and III, interchanged leads aVR and aVL, decreasing QRS amplitude from leads V1 to V6, and interchanged leads V1 and V2. The placement of precordial or, preferably, all leads should be reversed for accurate interpretation. Theoretically, preoperative medications should not include those with anticholinergic and cough-suppressing effects, to prevent further compromise of airway secretion clearance.

Cardiopulmonary inversion requires that the anesthesiologist carefully consider a number of issues. Pulmonary aspirations in patients with Kartagener's Syndrome may favor the left lung, which is also the larger lung; unintentional endobronchial intubation with a single lumen endotracheal tube usually will result in nonventilation of the right lung; right bronchial suctioning will be more difficult to perform with nonangulated suction catheters.

In patients with Kartagener's Syndrome, the use of a left-sided double-lumen tube may result in occlusion of the left upper lobe. When lung isolation is needed, we suggest that tracheal intubation be done first with a bronchial blocker and a single-lumen tube. Then bronchoscopy should be performed to confirm that pulmonary inversion is present and to position the bronchial blocker in the appropriate bronchus. If a double-lumen tube is required, we recommend that the left-sided tube be inserted with the bronchial tube on the right. The endobronchial stylet and the upper part of the tube must be bent 180° from their original orientation prior to insertion such that the normal curvature of the oropharynx is still followed. The same principles apply to the use of a right-sided tube. The same margin of safety in positioning double-lumen tubes should apply,<sup>15</sup> but with the sides reversed.

In dextrocardia, the position of ECG leads should be the mirror image of normal, as should that of the paddles of external defibrillation, cardioversion, and pacing. Since the great vessels and the thoracic duct are likely to be reversed, cannulation of the internal jugular vein preferably should be made on the left. The postoperative chest x-ray of our patient confirmed a left-sided superior vena cava with the central venous catheter in situ. During insertion, a pulmonary artery catheter should be oriented in anticipation of a clockwise direction of migration (as seen from the head of the patient) through the cardiac chambers and pulmonary artery.

We recommend in pregnant women with Kartagener's Syndrome that uterine displacement be to the right. In addition, we believe that nasal airways and tubes are relatively contraindicated because of the risk of paranasal sinusitis and ear infections. Aseptic techniques are important because of the possibility of abnormal neutrophil chemotaxis.<sup>16</sup>

In summary, we present the anesthetic management of a patient with Kartagener's Syndrome, in whom we have found complete inversion of the lungs in addition to dextrocardia and abdominal organ inversions. We also discuss the anesthetic implications of bronchiectasis, ciliary motility impairment, and situs inversus totalis. By adhering to the above recommendations, the anesthetic management of patients with Kartagener's Syndrome should be reasonably uncomplicated.

The authors thank Dr. G. L. Dunn, Dr. J. B. Forrest, and Dr. R. M. K. W. Lee for their valuable comments and Mrs. G. Pereira for her excellent secretarial assistance.

## REFERENCES

1. Afzelius BA, Mossberg B: The immotile-cilia syndrome including Kartagener's syndrome, *The Metabolic Basis of Inherited Disease*. 6th edition. Edited by Scriver CR, Beaudet AL, Sly WS, Valle D. New York, McGraw-Hill, 1989, pp 2739-2750
2. Rott H-D: Kartagener's syndrome and the syndrome of immotile-cilia. *Hum Genet* 46:249-261, 1979
3. Katsuhara K, Kawamoto S, Wakabayashi T, Belsky JL: Situs inversus totalis and Kartagener's syndrome in a Japanese population. *Chest* 61:56-61, 1972
4. Afzelius BA: A human syndrome caused by immotile-cilia. *Science* 193:317-319, 1976
5. Rossman CM, Forrest JB, Ruffin RE, Newhouse MT: Immotile-cilia syndrome in persons with and without Kartagener's syndrome. *Am Rev Respir Dis* 121:1011-1016, 1980
6. Rossman CM, Lee RMKW, Forrest JB, Newhouse MT: Nasal cilia in normal man, primary ciliary dyskinesia and other respiratory diseases: Analysis of motility and ultrastructure. *Eur J Respir Dis* 64(suppl 127):64-70, 1983
7. Rossman CM, Newhouse MT: Primary ciliary dyskinesia: Evaluation and Management. *Pediatr Pulmonol* 5:36-50, 1988
8. Whitelaw A, Evans A, Corrin B: Immotile cilia syndrome: A new case of neonatal respiratory distress. *Arch Dis Child* 56:432-435, 1981
9. Nadel HR, Stringer DA, Levison H, Turner JAP, Sturgess JM: The immotile cilia syndrome: Radiological manifestations. *Radiology* 154:651-655, 1985
10. Kartagener M, Stucki: Bronchiectasis with situs inversus. *Arch Pediatr* 79, 193-207, 1962
11. Woodring JH, Royer JM, McDonagh D: Kartagener's syndrome. *JAMA* 247:2814-2816, 1982
12. Nugent EW, Planth WH Jr, Edwards JE, Schlant RC, Williams WH: Congenital heart disease, *The Heart*. 6th ed. Edited by Hurst JW, Logue RB, Rackley CE, Schlant RC, Sonnenblick EH, Wallace AG, Wenger NK. New York, McGraw-Hill, 1986, p 688-689
13. Goldstein JL, Brown MS: Genetics and cardiovascular disease, *Heart Disease*. 2nd ed. Edited by Braunwald E. Philadelphia, WB Saunders, 1984, p 1618
14. Kaplan S: Congenital heart disease, *Cecil Textbook of Medicine*. 18th ed. Edited by Wyngarden JB, Smith LH Jr. Philadelphia, WB Saunders, 1988, p 315
15. Benumof JL, Partridge BL, Salvatierra C, Keating J: Margin of safety in positioning modern double lumen endotracheal tubes. *ANESTHESIOLOGY* 67:729-738, 1987
16. Valerius NH, Knudsen BB, Pedersen M: Defective neutrophil motility in patients with primary ciliary dyskinesia. *Eur J Clin Invest* 13:489-494, 1983