

Anesthesiology
76:869, 1992

Accidental Burn during Tonsillectomy

To the Editor:—Accidental burns may occur in the operating room from different sources.^{1,2} Presented here is a case of accidental second-degree burns that occurred when a warmed bag of intravenous fluid (IVF) was used to hyperextend the neck during a tonsillectomy.

A thirty-yr-old, 70-kg woman, ASA physical status 1, was admitted for elective tonsillectomy. Under general anesthesia, the patient was positioned supine with both arms tucked by her sides. The neck was hyperextended by placing a 1-l bag of IVF between the scapulae. The IVF bag was placed on top of a heating blanket warmed to 39° C. Two layers of cotton sheets were between the patient and the IVF bag. Surgery proceeded for 30 min, and after uneventful extubation and emergence, the patient was brought to the recovery room. Fifteen minutes later, the patient complained of pain and burning sensations across the upper back. Examination at this time revealed a 10 × 30-cm area of second-degree burn with blistering, transversely across the upper back (fig. 1). The outline of the injury corresponded to the position and shape of the IVF bag.

The patient was referred to the hospital burn center. A silver sulfadiazene 1% occlusive dressing was applied. The patient was discharged

the following day and was subsequently treated at the burn center outpatient clinic. The burns healed well without skin grafting.

It is routine at our institution to use an IVF bag under the scapulae to allow neck hyperextension during tonsillectomy. This IVF bag is normally at room temperature. In the case presented, the IVF bag was from a fluid warmer set at 55° C. This temperature accommodates cooling of IVF during administration.³ To identify the causative factors, in the above case, we attempted to simulate the events surrounding the injury. A heated IVF bag from the same warmer was used to support the shoulders of an awake volunteer. Although only warm to the touch, the IVF bag was uncomfortably hot when laid upon, and the pain was intolerable after 10 min. The temperature of this IVF bag was 48° C at the outset and decreased only 3.2° C during 30 min of exposure to the warming blanket. The blanket apparently limited the dissipation of heat from the IVF. Both pressure and persistent heat likely contributed to the burn in our patient.

CRISTINA G. PAMAAR, M.D.
Resident in Anesthesiology

IDREES AHMAD, M.D.
Attending Anesthesiologist

NICHOLAS J. MARSH, D.O.
Resident in Anesthesiology
Department of Anesthesiology
Saint Barnabas Medical Center
Old Short Hills Road
Livingston, New Jersey 07039

REFERENCES

1. Becker CM, Malhotra IV, Hedley-Whyte J: The distribution of radiofrequency current and burns. *ANESTHESIOLOGY* 38:106–121, 1973
2. Rao VK, Dibbell DG: Accidental hand burns caused by operating room lights. *Am J Hand Surg* 13A:50–52, 1988
3. Norman EA, Ahmad I, Zeig NJ: Delivery temperature of heated and cooled intravenous solutions. *Anesth Analg* 65:693–696, 1986

(Accepted for publication February 21, 1992.)

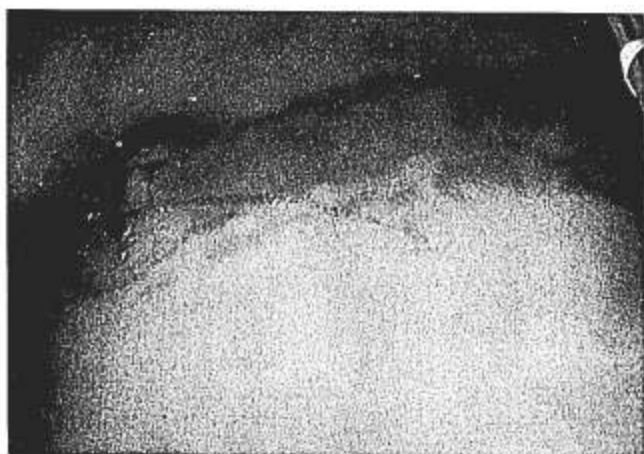

FIG. 1. Second-degree burn to the upper back following contact with bag of warmed intravenous fluid.

Anesthesiology
76:869–870, 1992

An Aid to the Performance of Interscalene Blocks

To the Editor:—Anesthesia for shoulder surgery at our institution is provided by means of an interscalene brachial plexus block. We follow the technique described by Winnie.¹ However, we do not elicit paresthesia to confirm the correct position of the needle in the interscalene sheath. We prefer identification of the brachial plexus in the interscalene sheath by means of a peripheral nerve stimulator and an insulated needle.^{2–4} An appropriate biceps and/or deltoid muscle twitch at or

below a current strength of 0.5 mA has resulted in a 95% success rate during the last 18 months (240 blocks).

Earlier this year, a 31-yr-old woman patient presented to us for a shoulder arthroscopy. She was extremely thin, and her anatomic landmarks were easily defined. Of interest to us was the fact that on examination the patient was found to have a bilateral absence of the clavicular head of her sternocleidomastoid muscle. Although uncom-

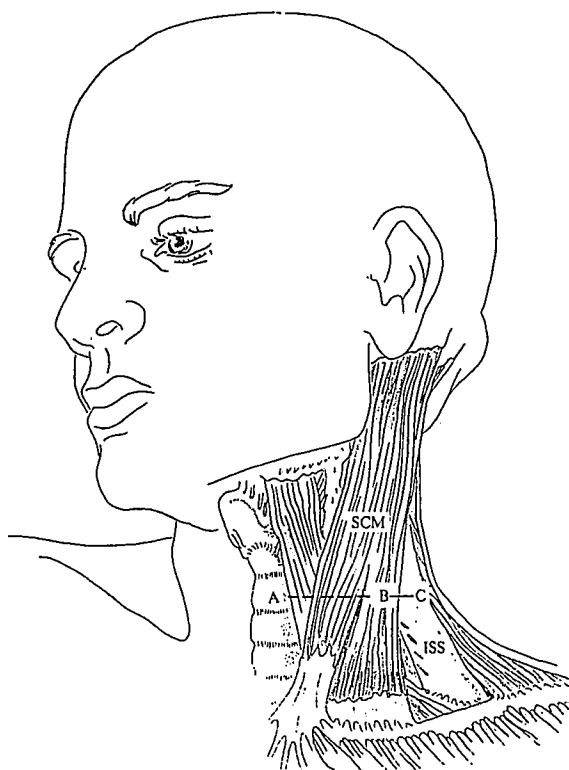


FIG. 1. Sternocleidomastoid muscle (SCM), interscalene sheath (ISS), level of C6 (A), posterior border of most palpable aspect of SCM (B), point of insertion of needle (C), and measured distance equal to 3.0 cm (B-C).

mon, this anatomic abnormality has been described previously.⁵ The patient's thinness made the anatomic abnormality quite obvious. In addition, the rest of the landmarks (*i.e.*, anterior and middle scalene muscles as well as the interscalene groove) were easily defined, and the patient underwent surgery with a successful interscalene block.

Out of curiosity, we measured the distance between the most obviously palpable portion of the belly of the sternocleidomastoid muscle and the interscalene groove at the level of the cricoid cartilage and found this to be 2.75 cm. We subsequently measured the same distance in the ensuing ten patients presenting for interscalene blocks (all of whom had normal anatomy) and found that the distance (line B-C in fig. 1) varied between 2.75 and 3.0 cm. Our reason for documenting this measurement was that had the above patient not had easily defined landmarks, we may well have been misled by the abnormal anatomy and would have had difficulty in identifying the interscalene groove and performing a successful interscalene block.

We have subsequently used this measurement as an aid to performing successful blocks on two separate occasions. In both cases the patients presented with poorly defined landmarks as a result of obesity. The

first patient was a 168-cm, 33-yr-old man who weighed 129 kg. The second patient was a 170-cm, 59-yr-old man who weighed 109 kg. In both cases, the position of the sternocleidomastoid muscle could be determined by palpation when the head was turned to the opposite side and raised from the operating room table against a resistance. However, it was impossible to define the scalene muscles or the interscalene groove, even during deep inspiration.⁶ In addition, in neither case were we able to identify the external jugular vein as a landmark to guide us to the position of the interscalene groove.⁷ Therefore, we marked the most prominent portion of the belly of the sternocleidomastoid muscle (B in fig. 1) and the level of the cricoid cartilage (A). We then extended a line laterally from the sternocleidomastoid muscle for 3.0 cm and inserted the needle at right angles to the skin at this point (C). In both cases we were able to perform a successful interscalene block without much difficulty.

Successful regional anesthesia is very much dependent on a thorough knowledge of anatomy. Occasionally, situations arise in which the anatomy is either abnormal or difficult to identify, particularly as a result of obesity. Under these circumstances, the success rate of regional blocks decreases, or the block is abandoned and general anesthesia administered. We report the above method as an aid to the usual technique of performing an interscalene block in patients in whom a block may otherwise be difficult, if not impossible.

ANTHONY R. BROWN, M.B. CH.B., F.F.A.
Associate Clinical Professor of Anesthesiology

EDWARD BROCCOLI, M.D.
Resident, Anesthesiology
Department of Anesthesiology
College of Physicians and Surgeons of Columbia University
West 168th Street
New York, New York 10032

REFERENCES

1. Winnie AP: Interscalene brachial plexus block. *Anesth Analg* 49: 455-466, 1970
2. Raj PP, Rosenblatt R, Montgomery SJ: Use of the peripheral nerve stimulator for peripheral nerve blocks. *Reg Anesth* 5:14-21, 1980
3. Bashein G, Haschke RH, Ready LB: Electrical nerve stimulation: Numerical and electrophoretic comparison of insulated vs uninsulated needles. *Anesth Analg* 63:919-924, 1984
4. Ford DJ, Pither C, Raj PP: Comparison of insulated and uninsulated needles for locating peripheral nerves with a peripheral nerve stimulator. *Anesth Analg* 63:925-928, 1984
5. Jackson CS: *Morris's Human Anatomy*. 5th Edition. Philadelphia, P Blakiston & Son, 1914, pp 349
6. Sharrock NE, Bruce G: An improved technique for locating the interscalene groove. *ANESTHESIOLOGY* 44:431-433, 1976
7. Winnie AP: *Plexus Anesthesia*. Volume 1, second printing (revised). Philadelphia, WB Saunders, 1990, pp 169

(Accepted for publication February 21, 1992.)