

intraspinal pressure) certainly must be considered. Our patient had no further diagnostic work-up (*i.e.*, magnetic resonance imaging, computed tomography–myelogram, cerebral-spine x-ray) because his symptoms never returned. We would concur with Vandam that if the patient's symptoms recurred, further diagnostic work-up would be indicated.

JAMES B. KELLY, JR., M.D.
Resident in Anesthesiology

GWEN BOYD, M.D.
Professor of Anesthesiology

Anesthesiology
76:322, 1992

JEFFREY PLAGENHOEF, M.D.

*Department of Anesthesiology
The University of Alabama at Birmingham
845 Jefferson Tower
619 South 19th Street, UAB Station
Birmingham, Alabama 35233-1924*

(Accepted for publication November 12, 1991.)

Airway Management with a Special Tube in an Infant with Bronchial Obstruction

To the Editor:—In the case of increased pulmonary blood flow associated with congenital cardiac defects, dilation of pulmonary artery may compress the airway, causing airway stenosis.¹⁻³ In such a case, positive pressure ventilation may lead to hyperinflation of the lung beyond the stenosis.¹ We present a case of an infant in whom bronchial stenosis was successfully managed by use of a specially configured tube that served as a stent for a segment of collapsed bronchi.

Our male patient was delivered vaginally at 39 weeks gestational age, with a birth weight of 3,000 g. Immediately after delivery, he presented with severe respiratory distress and cyanosis, and his trachea was intubated. Echocardiography resulted in a diagnosis of corrected transposition of the great arteries, pulmonary atresia, ventricular septal defect, patent ductus arteriosus, and right aortic arch. Fiberoptic bronchoscopy (FB) indicated stenosis of the right main bronchus (RMB), with compression by the dilated aorta possibly contributing to the stenosis.

When the child was 8 days old, aortosternotomy and left modified Blalock-Taussig shunt were performed, but they failed to relieve stenosis of RMB and hyperinflation of the right lung. An endotracheal tube tried as a stent⁴ was unsatisfactory because it did not permit ventilation of the left lung and obstructed the orifice of the right upper lobe bronchus. We therefore created two elliptical openings in the lateral wall of a 3-mm tube. The orifice for ventilating the left lung was located 1.5–4 cm from the distal tip of the endotracheal tube. A second orifice for ventilation of the right upper lobe bronchus was created on the contralateral side of wall of the tube. It was at the distal tip of the tube with a long axis of 1 cm and short axis of 2 mm. This modified tube was positioned with the distal tip within the RMB. Correct positioning was confirmed with FB and chest x-ray.⁵ Hyperinflation of the right lung was reduced and PaCO_2 could be maintained within normal range with lower inspiratory pressures than possible with tracheal intubation.

The risk of using a customized tube included the possibility of airway damage due to roughened surface of the tube where the added orifices were located. We smoothed the cut area using very fine sand paper and then tetrahydrofuran.

In conclusion, we treated a case of bronchial compression caused by a dilated aorta. The airway management was difficult and positive inspiratory pressure led to hyperinflation of the distal lung. Various

therapies failed to improve the condition, and a customized tube, which could stent the compression, enabled us to manage ventilation successfully.

MASAJI NISHIMURA, M.D.
SONOKO NAKANO, M.D.
HIROSHI UYEYAMA, M.D.
CHIKARA TASHIRO, M.D.
Department of Anesthesiology

HIROSHI KATOH, M.D.
TAKESHI NAKATA, M.D.
*Department of Cardiovascular Surgery
Osaka Medical Center and Research
Institute for Maternal and Child
Health*

840 Murodo-cho,
Izumi, Osaka 590-02, Japan

REFERENCES

1. Hosking MP, Beynen F: Anesthetic management of tetralogy of Fallot with absent pulmonary valve. *ANESTHESIOLOGY* 70:863–865, 1989
2. Corno A, Picardo S, Ballerini L, Gugliantini P, Marcelletti C: Bronchial compression by dilated pulmonary artery: Surgical treatment. *J Thorac Cardiovasc Surg* 90:706–710, 1985
3. Clevenger FW, Othersen HB Jr, Smith CD: Relief of tracheal compression by aortopexy. *Ann Thorac Surg* 50:524–529, 1990
4. Lobe TE, Hayden CK, Nicolas D, Richardson CJ: Successful management of congenital tracheal stenosis in infancy. *J Pediatr Surg* 22:1137–1142, 1987
5. Benumof JL: Separation of the two lungs (double-lumen tube intubation). *Anesthesia for Thoracic Surgery*. Philadelphia, WB Saunders Co., 1987, pp 223–259

(Accepted for publication November 20, 1991.)

Anesthesiology
76:322–323, 1992

Spontaneous Ventilation Through Transtracheal Access

To the Editor:—We read with interest the article by Dallen *et al.*¹ We encountered a similar case more than 27 yr ago that was successfully

treated by using two 14-G thin-wall intravenous needles. Subsequently we constructed two types of trocar (9- and 12-G) (fig. 1), which remain

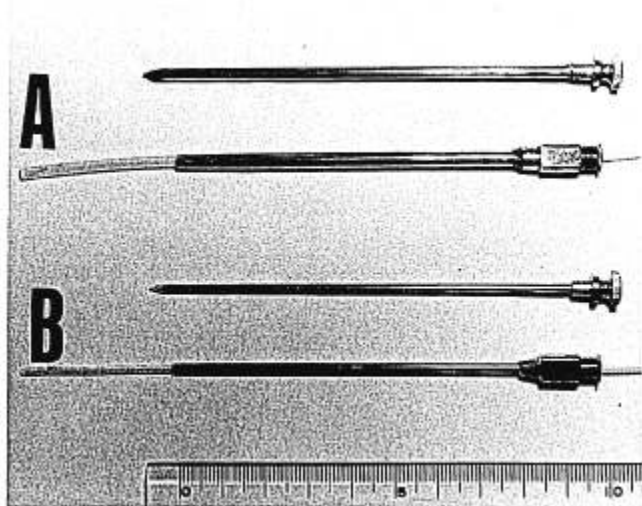


FIG. 1. Transtracheal trocars. A: 8-Fr suction catheter passing through a 9-G trocar (3.96 mm OD, 3 mm ID). B: 5-Fr suction catheter passing through a 12-G trocar (2.5 mm OD, 2 mm ID).

available in anesthesia carts and in emergency kits at our hospital and have been used successfully to treat two cases similar to that described by Dallen *et al.*

The most important factors in treatment of upper airway obstruction in the emergency setting are 1) to establish a patent airway and 2) to ensure the possibility of suctioning of secretions *via* the transtracheal access. Thus, it is necessary to provide transtracheal access with large-

bore devices that permit the passage of a suction catheter, as shown in figure 1. An additional issue of importance is to prevent kinking of the intravenous catheter and narrowing of the lumen following warming to body temperature. We have witnessed such accidents with the use of an intravenous catheter in the treatment of pneumothorax.

We therefore recommend that large-bore intravenous catheters or metal trocars and appropriate-sized suction catheters be included in anesthesia carts and emergency kits for treatment of upper airway obstruction.

YUKIO KUBOTA, M.D.
Chief

YOSHIRO TOYODA, M.D.
Associate Chief

HIROSHI KUBOTA, M.D.
Staff

Department of Anesthesia
Osaka Kohseinenkin Hospital
4-2-78, Fukushima
Fukushima-Ku, Osaka 553
Japan

REFERENCE

1. Dallen LT, Wine R, Benumof JL: Spontaneous ventilation *via* transtracheal large-bore intravenous catheters is possible. *ANESTHESIOLOGY* 75:531-533, 1991

(Accepted for publication November 25, 1991.)

The Work of Breathing Through Large-bore Intravascular Catheters

To the Editor:—We were fascinated by the case report of Dallen *et al.*¹ illustrating that spontaneous ventilation is possible *via* a large-bore intravascular catheter. They point out that there are few studies of spontaneous ventilation through such small-diameter devices. We recently undertook a study assessing such devices measuring the impact to respiration in terms of the additional work of inspiration. The study involved a lung model with a sinusoidal wave pattern, simulating spontaneous ventilation as described by Chan *et al.*² Using simultaneous measurements of airway pressure and respiratory gas flow at the proximal end of the artificial airway, the additional work (W) was derived using the algorithm described by Engstrom and Norlander³:

$$W = \int P \cdot \dot{V} dt$$

where P = airway pressure monitored in the mouth (kPa) and \dot{V} = instantaneous respiratory flow rate (L/s).

Table 1 summarizes some of our findings. Assuming the normal work of inspiration of a resting adult is on the order of 400–500 mJ/l, the results suggest that the patient ventilating through the 14- and 12-G catheters would need to sustain an additional inspiratory burden of 350–400% and 250–350% of the normal work of inspiration, respectively. The extra inspiratory workload may be more significant in acute rather than chronic obstruction. However, the findings from the

lung model must be extrapolated with caution to the clinical population, and must be interpreted in the context of the degree of upper airway obstruction, to its onset (acute or chronic) and change in pattern of ventilation as a consequence of adaptation. We agree with Dallen *et al.* that there are no studies looking at the flow characteristics or ventilatory parameters for adults breathing through such devices.

TABLE 1. The Effect of Catheter Diameter on the Additional Work of Breathing

	T ₈	T ₆	T ₄	12-G	14-G
W (mJ/l)	20	69	316	1349	1658
\dot{P} (kPa)*	-0.03	-0.11	-0.46	-1.72	-2.101

Work (W) expressed as additional inspiratory work per breath per liter of total ventilation. Simulated spontaneous respiration at 16 breaths per min with a tidal volume of 350 ml. T₈ = adult 8.0-mm internal diameter (ID) and T₆ and T₄ = 6.0- and 4.0-mm ID pediatric tracheostomy tubes, respectively. 14-G (Abbocath) and 12-G (Medicut) refer to the sizes of the intravascular catheter respectively. \dot{P} = the maximum pressure change attained during the inspiratory cycle.

* kPa = 7.5 mmHg.