

## When the Endotracheal Tube Will Not Pass over the Flexible Fiberoptic Bronchoscope

*To the Editor:*—Despite successful placement of the fiberoptic bronchoscope through the vocal cords and identification of the tracheal carina, difficulty may still be encountered in threading the endotracheal tube (ETT), even in routine situations.

To evaluate this problem and to find a solution, we studied fiberoptic intubation on the intubating mannequin (Ambu, Denmark). In this model, the left side of the "patient's" head and neck is absent, allowing observation of laryngeal structures. Oral flexible fiberoptic laryngoscopy was performed using an Olympus LF-1 fiberoptic bronchoscope. After insertion of the tip of the bronchoscope into the trachea and identification of the tracheal carina, a disposable plastic ETT (Rusch, 7.5 mm ID) was advanced over the bronchoscope, with the natural curve of the tube aligned vertically with respect to the "patient." When resistance was encountered, we examined the point of obstruction. In the overwhelming majority of cases, the distal end of the bevel (Murphy tip) of the ETT was caught on the right arytenoid, despite correct placement of the bronchoscope in the trachea (fig. 1).

The same point of obstruction was encountered on advancing the ETT in actual patients and was confirmed by direct rigid laryngoscopy. The Murphy tip of the ETT was often resting on the right arytenoid, which hindered smooth advancement into the trachea. Simple manipulation of the tube to place the Murphy tip under the epiglottis resolved the problem.

Most available ETTs have a radiopaque stripe on the convex surface. These stripes are found along the Murphy eye of the Portex, Curity, and Mallinkrodt tubes and across the eye in the Rusch tube. After identification of the tracheal carina, and before attempting to advance

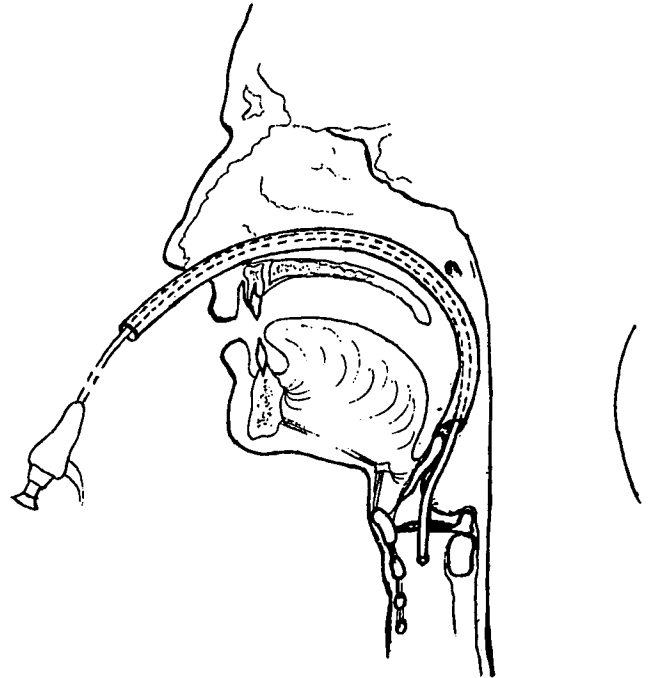


FIG. 2. Nasotracheal tube "hanging up" on the epiglottis cannot pass into the trachea.

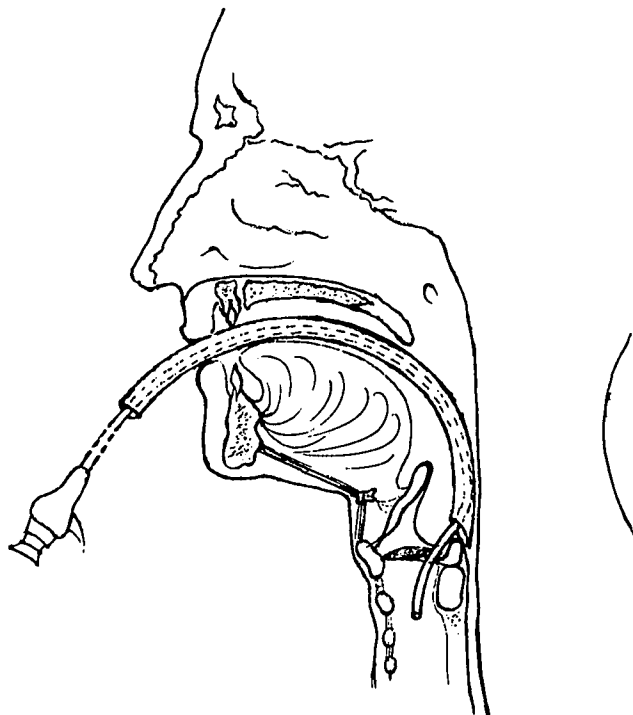


FIG. 1. Orotracheal tube "hanging up" on the right arytenoid prevents smooth passage of the ETT into the trachea.

the ETT, we positioned the stripe on the patient's right side (at approximately the one o'clock position). This maneuver placed the Murphy tip under the epiglottis and allowed smooth passage of the ETT over the bronchoscope into the trachea.

In cases of nasotracheal fiberoptic intubation, the obstruction occasionally encountered was usually due to "hanging-up" of the Murphy tip on the epiglottis (fig. 2). Positioning of the radiopaque stripe to the patient's left and put the Murphy tip of the ETT posteriorly and facilitated passage.

Our observations confirm earlier studies in which Ovassapian *et al.* described a similar hanging-up of the ETT and suggested that the point of obstruction was the epiglottis.<sup>1</sup> Schwartz *et al.*,<sup>2</sup> Dellinger,<sup>3</sup> and Roberts<sup>4</sup> postulated that the obstruction was due to the impingement of the ETT on the right arytenoid.

We believe that the different mechanisms of obstruction are due to different alignments of the oral, pharyngeal, and laryngeal axes<sup>5</sup> in oro- and nasotracheal intubation. Smooth, correct placement of the ETT is achieved by positioning the stripe to the patient's left in nasotracheal intubation to place the Murphy tip of the ETT posteriorly. During orotracheal intubation, positioning the stripe to the patient's right and slightly anterior allows the ETT to pass under the epiglottis.

TATYANA KATSNELSON, M.D.  
ELIZABETH A. M. FROST, M.D.  
ERLINA FARCON, M.D.  
PAUL L. GOLDINER, M.D.

*Department of Anesthesiology  
Albert Einstein College of Medicine  
1300 Morris Park Avenue  
Bronx, New York 10461-1602*

## REFERENCES

1. Ovassapian A, Yelich SJ, Dykes MHM, Brunner EE: Fiberoptic nasotracheal intubation: Incidence and causes of failure. *Anesth Analg* 62:692-695, 1983
2. Schwartz D, Johnson C, Roberts J: A maneuver to facilitate flexible fiberoptic intubation. *ANESTHESIOLOGY* 71:470-471, 1989
3. Dellinger RP: Fiberoptic bronchoscopy in adult airway management. *Crit Care Med* 18:882-887, 1990
4. Roberts JT: Preparing to use flexible fiberoptic laryngoscope. *J Clin Anesth* 3:64-74, 1991
5. Stoelting RK: Endotracheal intubation, Anesthesia. 2nd edition. Edited by Miller RD. New York, Churchill Livingstone, 1986, pp 523-552

(Accepted for publication September 23, 1991.)

Anesthesiology  
76:152, 1992

## Burn Associated with Temperature Monitoring during Magnetic Resonance Imaging

*To the Editor:*—In a recent letter, Bashein and Syrový described two cases of burns associated with the use of a pulse oximeter during magnetic resonance imaging (MRI) under general anesthesia.<sup>1</sup> We have had a similar case in which a patient suffered a second-degree burn from the use of a temperature probe specifically designed for use during MRI.

A 10-yr-old patient underwent MRI of the lumbosacral spine during general anesthesia. Monitoring included an axillary skin probe that is part of the Omni-Trak Vital Signs Monitoring System (Invivo Research Inc., Winter Park, FL). At the end of the 2-h procedure, examination of the axillary area revealed a large second-degree burn. Conservative therapy resulted in resolution of the burn without scarring. Examination of the probe by both the personnel present and the institution's biomedical engineers did not detect any faults in the probe.

Although equipment specifically designed for the MRI setting has been constructed to minimize both interference with the image and interference of the MRI on the monitor's signal,<sup>2</sup> it is still possible for enough heat to build up to generate a skin burn, especially if the monitor shielding is inadequate or the monitor cable is looped.<sup>3</sup> Neither fraying nor looping was observed in this case, although the bed was moved in and out of the scanner, with consequent movement of the cable. Because of this problem, we have switched to intermittent sampling between scanning sessions as a reasonable alternative to constant sampling. Also, all monitor cables are examined after each change in patient position to prevent inadvertent cable-heating from coiling.

STEVEN C. HALL, M.D.  
*Associate Professor of Clinical Anesthesia*  
G. W. STEVENSON, M.D.  
*Assistant Professor of Clinical Anesthesia*  
SANTHANAM SURESH, M.D.  
*Instructor of Clinical Anesthesia*  
*Children's Memorial Hospital  
Northwestern University Medical School  
2300 Children's Plaza  
Chicago, Illinois 60614*

## REFERENCES

1. Bashein G, Syrový G: Burns associated with pulse oximetry during magnetic resonance imaging (correspondence). *ANESTHESIOLOGY* 75:382-383, 1991
2. Karlik SJ, Heatherley T, Pavan F, Stein J, Lebron F, Rutt B, Carey L, Wexler R, Gelb A: Patient anesthesia and monitoring at a 1.5-T MRI installation. *Magn Reson Med* 7:210-221, 1988
3. Kanal E, Shellock FG, Talagala L: Safety considerations in MR imaging. *Radiology* 176:593-606, 1990

(Accepted for publication September 30, 1991.)

Anesthesiology  
76:152, 1992

*In Reply:*—The authors correctly point out that "looping" of conductors within the magnetic resonance imaging (MRI) bore can increase burn risk. These loops permit better coupling of the radiofrequency excitation pulses onto the conductors by essentially forming efficient antennae. We also suspect a cross-coupling effect between essentially straight, but multiple, conductors used within the MRI bore.

Specifically addressing burn from surface temperature sensors, Invivo Research Inc. would also like to point out that, in addition to the need for careful patient preparation of monitoring lead wires and constant user vigilance, the directions for use of the temperature monitoring feature given in our users' manual and reference card advise

setting the upper temperature alarm limit to provide warning of probe tip heating. This precaution might have eliminated the occurrence of this unfortunate event.

ROGER SUSI  
*President*  
*Invivo Research Inc.*  
*4420 Metric Drive, Suite A*  
*Winter Park, Florida 32792*

(Accepted for publication September 30, 1991.)