MEDICAL INTELLIGENCE ARTICLE

Julien F. Biebuyck, M.B., D.Phil., Editor

Anesthesiology
75:1087–1110, 1991

Management of the Difficult Adult Airway

With Special Emphasis on Awake Tracheal Intubation

Jonathan L. Benumof, M.D.[*]

CONTENTS

- I. Introduction
  - A. Definition and Classification of Airway Difficulty
  - B. Incidence of Each Degree of Airway Difficulty
  - C. Incidence of Complications with Each Degree of Airway Difficulty
- II. Specific Management of the Difficult Airway
  - A. Recognition of the Difficult Airway
    - 1. Pathologic Disorders Commonly Associated with Airway Difficulty
    - 2. Anatomic Causes of Airway Difficulty
      - a. Relative Tongue/Pharyngeal Size
      - b. Atlanto-occipital Joint Extension
      - c. Mandibular Space
    - 3. Difficult Airway Recognition Plan
  - B. Awake Tracheal Intubation
    - 1. Proper Preparation of the Patient for Awake Tracheal Intubation
    - 2. Choice of Tracheal Intubation Technique
      - a. Conventional (Direct) Laryngoscopy
      - b. Flexible Fiberoptic Endoscopy
        - i. Positioning the Patient
        - ii. Aids to Fiberscope Insertion
        - iii. Passage of the Endotracheal Tube over the Fiberscope
      - c. Retrograde Techniques (Translaryngeal-guided Intubation)
      - d. Combinations of Conventional, Fiberoptic, and Retrograde Techniques
      - e. Other Recently Introduced Awake Tracheal Intubation Techniques
        - i. New Laryngoscopy/Retraction Blades
        - ii. New Illuminating Intubating Stylets
      - f. Tracheostomy
  - C. The Anesthetized Patient Whose Trachea Is Difficult to Intubate
    - 1. Preparation of the Patient with a Full Stomach for the Induction of General Anesthesia
    - 2. Choice of Intubation Technique
    - 3. Management of Regurgitation or Vomiting in the Anesthetized Patient
  - D. The Patient Whose Lungs Cannot be Ventilated by Mask and Whose Trachea Cannot Be Intubated
    - 1. The Combitube
    - 2. The Laryngeal Mask Airway
    - 3. Transtracheal Jet Ventilation
  - E. Tracheal Extubation of a Patient with a Difficult Airway
    - 1. The Jet Stylet
    - 2. Connection of the Jet Stylet to the Jet Ventilator
    - 3. Gas Flows Through the Various Jet Stylet Connection Systems
    - 4. Jet Stylet Extubation Technique
      - a. General Routine Measures
      - b. Preserving the Intratracheal Location of the Jet Stylet while Determining the Location of the Reintubation Tracheal Tube
    - 5. Use of a Fiberoptic Bronchoscope as a Jet Stylet
- III. Summary

Footnotes are indicated by superscript letters. Complete citations follow the References.

I. Introduction

The fundamental responsibility of an anesthesiologist is to maintain adequate gas exchange. In order to do this, the airway must be managed in such a way that it is almost continuously patent. Failure to maintain a patent airway for more than a few minutes results in brain damage or death. Thus, it is not surprising that more than 85% of all respiratory-related closed malpractice claims involve a

---

[*] Professor of Anesthesiology.

Received from the Department of Anesthesia, University of California, San Diego School of Medicine, San Diego, California. Accepted for publication August 7, 1991.

Address reprint requests to Dr. Benumof: Anesthesia Research Laboratory, T-001, University of California, San Diego School of Medicine, La Jolla, California 92093.

Key words: Aspiration. Cricothyroidotomy. Equipment: Combitube; fiberoptic bronchoscope; illuminating stylet; jet stylet; laryngeal mask airway; nasopharyngeal airway; oropharyngeal airway. Extubation. Jet stylet. Laryngoscopes. Laryngoscopy. Local anesthesia: airway. Management: airway. Neck: extension; flexion. Tracheal intubation: awake; direct vision; fiberoptic; retrograde. Tracheostomy. Ventilation: mask; jet.

brain-damaged or dead patient,[1] and it has been estimated that inability to successfully manage very difficult airways has been responsible for as many as 30% of deaths totally attributable to anesthesia.[2,3]

In any patient, the greater the degree of "difficulty" in maintaining airway patency, the greater the risk of brain damage or death. Before discussing the specific management of a "difficult airway", we must 1) define what is meant by a "difficult airway"; 2) classify the degrees of difficulty experienced in maintaining a patent airway; 3) determine the incidence of each degree of airway difficulty; and 4) determine the incidence of major and minor complications as a function of the degree of airway difficulty. The main body of this review will discuss an ASA Task Force[a] difficult airway management algorithm; the algorithm is concerned with the maintenance of airway patency at all times. Special emphasis will be placed on awake tracheal intubation, on new information and/or concepts, and on an operating room setting (although most of the paper can be extrapolated to the intensive care unit and the ward). It is always assumed that a fully trained anesthesiologist is attempting to maintain airway patency. Adherence to the principles of the difficult airway management algorithm and the widespread adoption of a precise plan for management of airway difficulties should result in reduction of respiratory catastrophes and a decrease in anesthesia morbidity and mortality.

A. DEFINITION AND CLASSIFICATION OF AIRWAY DIFFICULTY

There are two common ways of maintaining airway patency and gas exchange. First, inspired gas is delivered to the face *via* a mask that is sealed to the patient's face while the natural airway from the face to the vocal cords is kept patent with or without external jaw thrust maneuvers or internal upper airway devices (mask ventilation). Second, the airway is kept open to the inspired gas by some sort of tube passed from the environment to some point below the vocal cords (endotracheal intubation).

In terms of degree of difficulty, mask ventilation can range from zero to infinite (fig. 1, top). Zero degree of mask ventilation difficulty means that no external effort and/or internal upper airway device is required to maintain airway patency; that is, mask ventilation is extremely easy and occurs *via* the natural airway. Next, there are several specific, reproducible, and progressive degrees of mask ventilation difficulty: these consist of one-person jaw thrust/mask seal, insertion of an oro- or nasopharyngeal airway, one-person jaw thrust and insertion of one or both airway(s), and two-person jaw thrust/mask seal and both airways. Whenever an airway is used, it is likely that jaw thrust will also be used, and therefore these indices of difficulty are shown in figure 1 as occurring together. Infinite degree of mask ventilation difficulty means that despite maximal external effort and full use of oro- and nasopharyngeal airways, adequate airway patency cannot be maintained; that is, mask ventilation is impossible. Of course, in any given patient the degree of difficulty with mask ventilation may change with time.

The difficulty of intubation under direct vision can also range from zero to infinity (fig. 1, bottom panel). Zero degree of difficulty with intubation means that an endotracheal tube (ETT) can be inserted into a fully visualized laryngeal aperture (grade I laryngoscopic view[4,5]; fig. 2) with little effort. Next, there are several specific, reproducible, and progressive degrees of intubation difficulty; these consist of visualization of progressively less of the

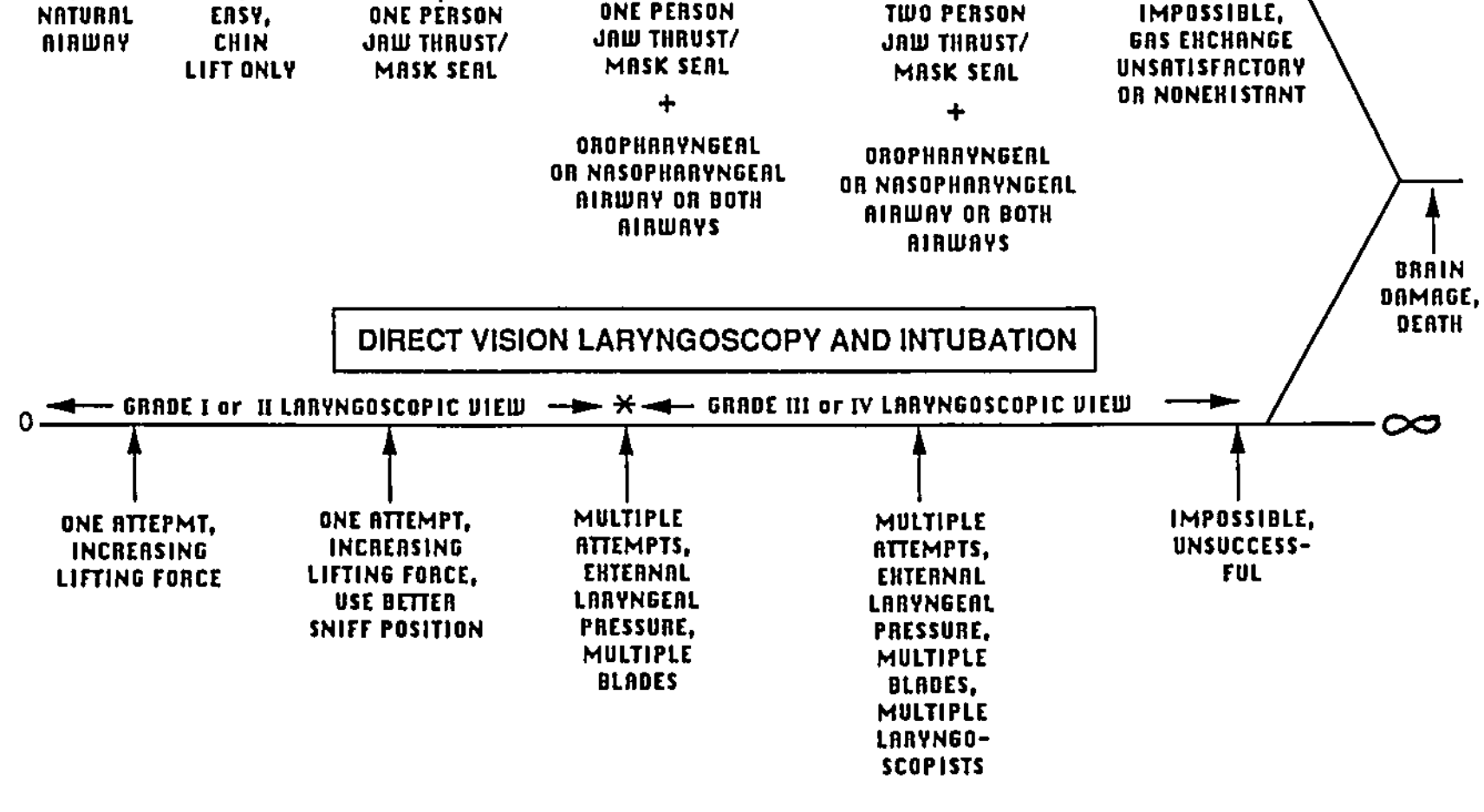
MASK VENTILATION
0
∞
NATURAL AIRWAY
EASY, CHIN LIFT ONLY
ONE PERSON JAW THRUST/ MASK SEAL
ONE PERSON JAW THRUST/ MASK SEAL + OROPHARYNGEAL OR NASOPHARYNGEAL AIRWAY OR BOTH AIRWAYS
TWO PERSON JAW THRUST/ MASK SEAL + OROPHARYNGEAL OR NASOPHARYNGEAL AIRWAY OR BOTH AIRWAYS
IMPOSSIBLE, GAS EXCHANGE UNSATISFACTORY OR NONEXISTANT
BRAIN DAMAGE, DEATH
DIRECT VISION LARYNGOSCOPY AND INTUBATION
GRADE I or II LARYNGOSCOPIC VIEW
*
GRADE III or IV LARYNGOSCOPIC VIEW
0
∞
ONE ATTEPMT, INCREASING LIFTING FORCE
ONE ATTEMPT, INCREASING LIFTING FORCE, USE BETTER SNIFF POSITION
MULTIPLE ATTEMPTS, EXTERNAL LARYNGEAL PRESSURE, MULTIPLE BLADES
MULTIPLE ATTEMPTS, EXTERNAL LARYNGEAL PRESSURE, MULTIPLE BLADES, MULTIPLE LARYNGOSCOPISTS
IMPOSSIBLE, UNSUCCESSFUL

FIG. 1. Definition of a difficult airway. Airway refers to either mask ventilation or endotracheal tube (ETT) intubation by direct vision laryngoscope. The degree of difficulty can range from zero, which is extremely easy, to infinite, which is impossible. When both mask ventilation and direct vision laryngoscopy are impossible, and no other maneuver is successful, brain damage and/or death will ensue. In between these extremes there are several well-defined, commonly encountered degrees of difficulty. The grade of laryngoscopic view refers to figure 2 and is represented as an approximate continuum above the discrete progressive indicies of laryngoscopic difficulty.

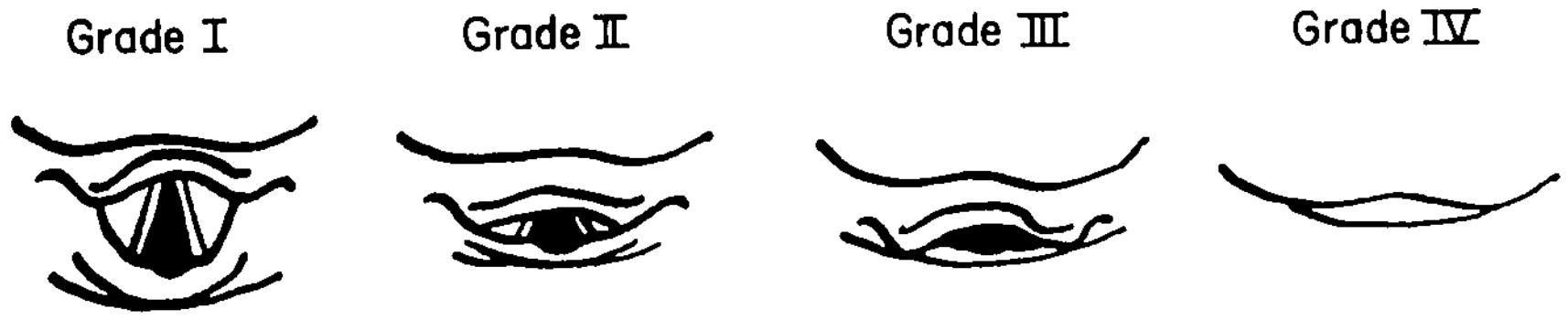

FIG. 2. The four grades of laryngoscopic view, as defined by Cormack and Lehane.[5] Grade I is visualization of the entire laryngeal aperture; grade II is visualization of just the posterior portion of the laryngeal aperture; grade III is visualization of only the epiglottis; and grade IV is the visualization of just the soft palate. Reproduced with permission from Cormack and Lehane.[5]

laryngeal aperture (grades II and III laryngoscopic views[4,5]; figs. 1 and 2). As the view worsens, increasing anterior lifting force with the laryngoscope blade, optimal sniff position, multiple attempts, external laryngeal pressure, multiple blades, and laryngoscopists may be required to achieve intubation. External laryngeal pressure may be required to push the larynx more posteriorly and cephalad into better view (thereby decreasing the laryngoscopic view from a higher to a lower grade). Similarly, it should be recognized that anatomy that results in a high-grade laryngoscopic view for one individual with a given laryngoscope blade may result in a lower laryngoscopic grade for a more experienced or skillful individual with perhaps a different blade. Whenever multiple attempts are required, it is likely that external laryngeal pressure will also be applied; therefore, these indices of difficulty are shown occurring together. Although a severe grade III (tip epiglottis) and a grade IV (just soft palate; figs. 1 and 2) laryngoscopic view[4,5] may result in a successful "blind" intubation, these views will often result in an impossible intubation. An infinitely difficult intubation means that the trachea cannot be intubated under direct vision despite optimal head and neck positioning, very forceful anterior elevation of the laryngoscope blade, use of multiple attempts, laryngoscope blades and laryngoscopists, external posterior and cephalad displacement of the larynx, and full paralysis; that is, tracheal intubation through a nonvisualized larynx is impossible. Of course, in any given patient, the degree of tracheal intubation difficulty can be independent of the degree of mask ventilation difficulty and can progressively increase and approach the impossible extreme.

B. INCIDENCE OF EACH DEGREE OF AIRWAY DIFFICULTY

The incidence of airway difficulty in the general surgical population varies greatly depending on its degree (table 1). A grade II or III laryngoscopic view requiring multiple attempts and/or blades (and presumably external laryngeal pressure) is relatively common and occurs in 100–1,800 of 10,000 patients or 1–18%.[5-10] As the degree of difficulty increases to a definite grade III laryngoscopic view, then the incidence is generally slightly less and ranges 100–400 of 10,000 patients or 1–4%.[4,b] The incidence of failed endotracheal intubation (presumably a severe grade III or grade IV view) is still less and ranges 5–35 of 10,000 patients or 0.05–0.35%[4,5,11-14]; the high and low ends of this range are associated with obstetric and other surgical patients, respectively. There are no data available regarding the incidence of difficulty with mask ventilation alone. However, the incidence of completely failed mask ventilation *and* ETT intubation can be estimated, because such an airway failure combination heretofore frequently resulted in brain damage or death and has ranged 0.01–2.0 of 10,000 patients.[2,3,15]

C. INCIDENCE OF COMPLICATIONS WITH EACH DEGREE OF AIRWAY DIFFICULTY

Anesthesia in a patient with a difficult airway can lead to both direct airway trauma and morbidity from hypoxia and hypercarbia. Direct airway trauma occurs because the management of the difficult airway often involves the application of more physical force to the patient's airway than is normally used. The most common consequence is

TABLE 1. Incidence of Difficult Intubation According to Degree of Difficulty

Degree of Difficulty with Intubation (see fig. 1)	Range of Incidence		Reference
	Per 10,000	%	
ETT intubation successful but multiple attempts and/or blades may be required; probable grade II or III	100–1800	1–18	5–10
ETT intubation successful but multiple attempts and/or blades and/or laryngoscopists required; grade III	100–400	1–4	4
ETT intubation not successful; Grade III or IV	5–35	0.05–0.35	4, 5, 11–14
Cannot ventilate by mask plus cannot intubate; transtracheal jet ventilation, tracheostomy, brain damage, or death	0.01–2.0	0.0001–0.02	2, 3, 15

probably a chipped or broken tooth. Direct trauma may involve any part of the face, teeth, and upper airway, resulting in hemorrhage, lacerations, and subsequent tissue emphysema and infection, fracture-subluxation of the cervical spine, and trauma to the eye. Much of the morbidity specifically attributable to managing a difficult airway comes from an interruption of gas exchange (hypoxia and hypercapnia), which may then cause brain damage and cardiovascular activation or depression. Directly mediated reflexes (laryngovagal [airway spasm, apnea, bradycardia, arrhythmia, or hypotension], laryngosympathetic [tachycardia, tachyarrhythmia, or hypertension], and laryngospinal [coughing, vomiting, or bucking]) provide the final source of morbidity. Both direct trauma and morbidity from airway obstruction can range from minor (trivial or nuisance value) to major (life-threatening or death).

It is reasonable to postulate that the more difficult the airway is to manage, the greater will be the use of physical force, the number of attempts to establish the airway, and the incidence of complications. Only one study[b] has directly addressed this question, and its data strongly support this contention. In this study, the incidence of relatively minor upper airway complications (posterior pharyngeal and lip lacerations and bruises) with laryngoscopy and intubation under direct vision in patients with normal airways was 5%.[b] In patients in whom tracheal intubation was anticipated to be difficult, the incidence of minor trauma to the upper airway increased to 17%.[b] In patients in whom tracheal intubation was actually found to be difficult (multiple attempts at laryngoscopy but ultimately successful), the incidence of upper airway complications was 63%. Of course, when it has been impossible to manage the airway, the incidence of complications may further increase because of the inclusion of some cases of brain damage or death.[1,3,15]

II. Specific Management of the Difficult Airway

The management of the difficult airway will follow the algorithm shown in figure 3. The algorithm begins with the most basic question of whether or not the presence of a difficult airway is recognized.

Most airway catastrophes have occurred when possible difficulty with the airway was not recognized.[4,16,17,18,c,d] In 1988, Sia and Eden estimated that 90% of cases of difficult intubation should be anticipated.[18] However, in a prospective study of 1,200 patients from Cardiff at approximately the same time, 22 of 43 difficult intubations (51%) were anticipated and 21 (49%) were not.[19] In this latter study, although difficult intubation was expected in 84 patients, only in 22 (25%) was intubation actually difficult.[19] Thus, it is clear that unexpected airway difficulty occurs commonly, that some cases of anticipated difficulty are simple to manage, and that better routine predictors of airway difficulty are needed.

A. Recognition of the Difficult Airway

1. *Pathologic Disorders Commonly Associated with Airway Difficulty*

An airway may be easily recognized as being difficult, or the potential difficulty may be very subtle and require careful examination of the patient. The pathologic causes

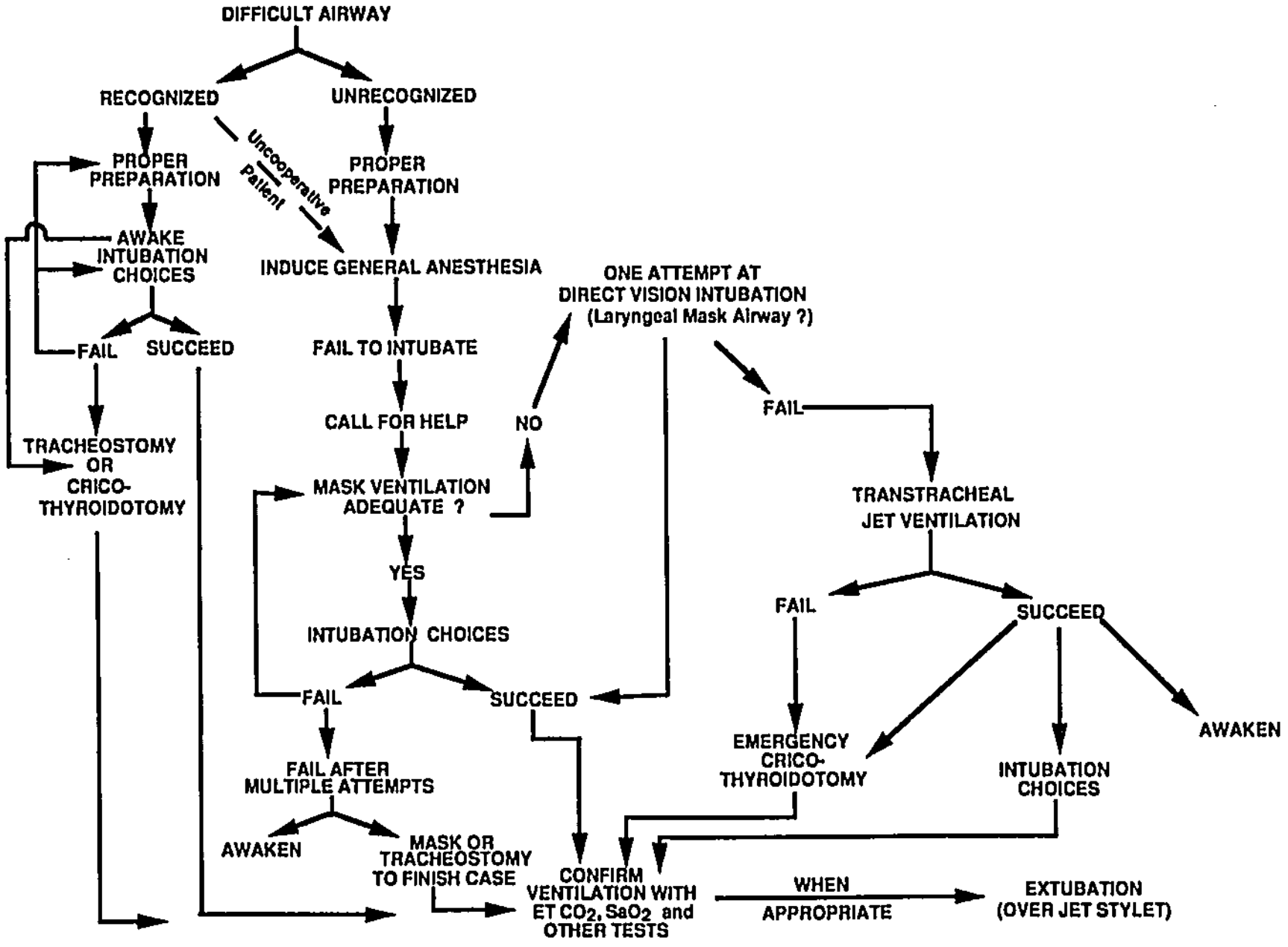
DIFFICULT AIRWAY
RECOGNIZED
UNRECOGNIZED
PROPER PREPARATION
Uncooperative Patient
PROPER PREPARATION
AWAKE INTUBATION CHOICES
INDUCE GENERAL ANESTHESIA
ONE ATTEMPT AT DIRECT VISION INTUBATION (Laryngeal Mask Airway ?)
FAIL
SUCCEED
FAIL TO INTUBATE
CALL FOR HELP
NO
FAIL
TRACHEOSTOMY OR CRICO-THYROIDOTOMY
MASK VENTILATION ADEQUATE ?
TRANSTRACHEAL JET VENTILATION
YES
FAIL
SUCCEED
INTUBATION CHOICES
FAIL
SUCCEED
EMERGENCY CRICO-THYROIDOTOMY
INTUBATION CHOICES
AWAKEN
FAIL AFTER MULTIPLE ATTEMPTS
AWAKEN
MASK OR TRACHEOSTOMY TO FINISH CASE
CONFIRM VENTILATION WITH ET CO2, SaO2 and OTHER TESTS
WHEN APPROPRIATE
EXTUBATION (OVER JET STYLET)

FIG. 3. Difficult airway management algorithm.

of difficulties with the airway are very numerous and have been extensively detailed elsewhere.[17,20-23] They include a host of congenital facial and upper airway deformities (including severe maxillary overbite), maxillofacial and airway trauma, airway tumors and abscesses, the requirement for cervical spine immobility, fibrosis of the face and neck (burns or radiation), surgically induced deformities, and some systemic diseases. Special facial characteristics that make mask ventilation more difficult include a thick beard, massive jaw, lack of teeth, extreme sensitivity of skin to friction (burns, skin grafts, or epidermolysis bullosa), and the presence of massive facial dressings. Since these conditions are typically recognized before anesthetic induction, they have not been responsible for many anesthesia-related airway catastrophes (brain damage or death).[4,16-18,b-d]

2. *Anatomic Causes of Airway Difficulty*

Fortunately, three recent, extremely easy-to-perform, no-cost, preoperative examinations appear to be much more accurate predictors of subtle anatomic causes of intubation difficulty than any criteria used in the past.

a. RELATIVE TONGUE/PHARYNGEAL SIZE: The size of the tongue in relation to the size of the oral cavity can be very simply and visually graded by how much of the pharynx is obscured by the tongue. When this test is performed, the patient sits upright with the head in a neutral position and is asked to open the mouth as widely as possible and to protrude the tongue as far as possible. The observer then classifies the airway according to the pharyngeal structures seen as follows (fig. 4):

Class I = Soft palate, fauces, uvula, anterior and posterior tonsillar pillars
Class II = Soft palate, fauces, uvula
Class III = Soft palate, base of uvula
Class IV = Soft palate not visible at all

A significant correlation has been noted between the ability to visualize the faucial pillars, soft palate, and uvula and the ease of laryngoscopy.[4,7] In patients with a class I airway, the laryngoscopic view is grade I 99–100% of the time,[4,7,24] and in those with a class IV airway, the laryngoscopic view is grade III or IV 100% of the time.[7,25] Indeed, one group of investigators have been so impressed by this positive correlation between the extremes in classification of tongue size (I and IV) and the grade of laryngoscopic view (I and III or IV, respectively), that in their obstetric department they encourage early use of epidural analgesia in patients with tongue size classes of III and IV in the hope that general anesthesia may be avoided.[4] However, patients with intermediate tongue/pharynx size classifications of II and III were found to have a relatively uniform distribution of all grades of laryngoscopic view (I–IV).[7,24] Indeed, in a subset of 10% of patients with a class II airway only a grade IV laryngoscopic view could be obtained with a Macintosh blade.[7] Limitations of the tongue/pharyngeal size classification and laryngoscopic grade include failure of the tongue/pharyngeal size classification to consider neck mobility, the size of the mandibular space, and significant interobserver variability in classification.[26] Sources of interobserver variability include use of the test in patients in the supine position, patient phonation (says "Ah") during the test (which falsely improves the view), and patients' arching of their tongue (which obscures the uvula). Thus, despite widespread general agreement with the usefulness of the original findings,[4,7,20,24,25] the so-called "Mallampati" test has significant false-negative[26,27] and false-positive rates[26] and cannot be considered to be entirely predictive of severe intubation difficulty.

b. ATLANTO-OCCIPITAL JOINT EXTENSION: It has long been well appreciated that when the neck is moderately flexed on the chest (25–35°) and the atlanto-occipital joint is well extended (head extended on the neck), the oral, pharyngeal, and laryngeal axes are brought more nearly into a straight line (otherwise known as the "sniff" or Magill position).[28-30] In this position less of the tongue will obscure the view of the larynx, and consequently there will be much less need for strenuous effort to displace the tongue anteriorly. Thirty-five degrees of extension are possible at the normal atlanto-occipital joint.[31] Bedside

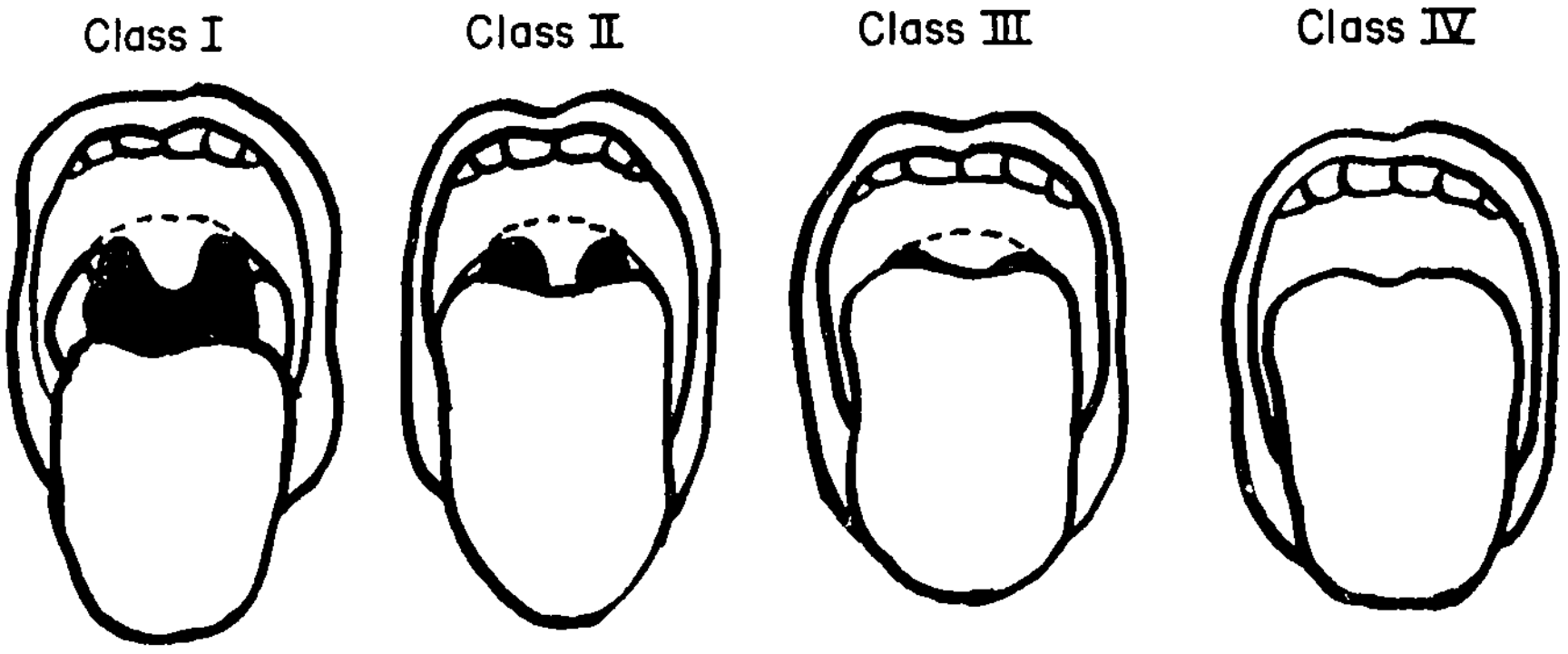

FIG. 4. Classification of the upper airway in terms of the size of the tongue and pharyngeal structures visible upon mouth opening. In class I patients, the soft palate, fauces, uvula, and anterior and posterior tonsillar pillars can be seen; in class II patients, all of the above can be seen except the tonsillar pillars, which are hidden by the tongue; in class III patients, just the base of the uvula can be seen; and in class IV patients not even the uvula can be visualized. Reproduced with permission from Mallampati *et al.*[7]

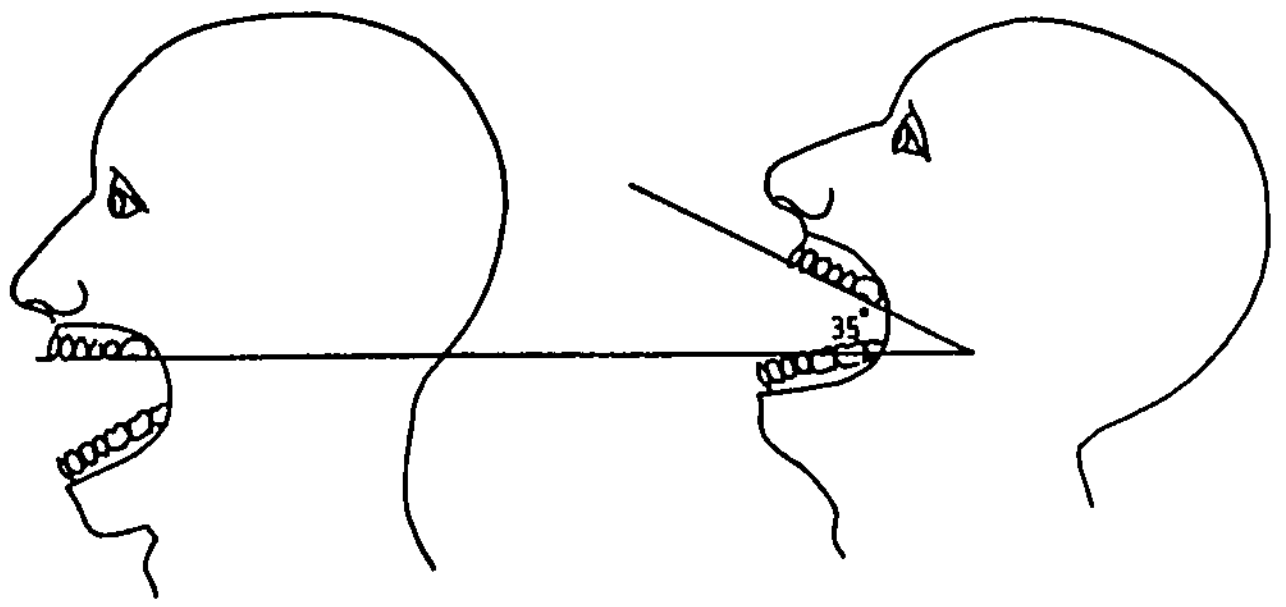

FIG. 5. Clinical method for quantitating atlantooccipital joint extension. When the head is held erect and facing directly to the front, the plane of the occlusal surface of the upper teeth is horizontal and parallel to the ground. When the atlantooccipital joint is extended, the occlusal surface of the upper teeth will form an angle with the plane parallel to the ground. The angle between the erect and extended planes of the occlusal surface of the upper teeth quantitates the degree of atlantooccipital joint extension. A normal person can produce 35° of atlantooccipital joint extension. Reproduced with permission from Bellhouse and Doré.[3]

TABLE 3. Bivariable Prediction of Difficulty of Endotracheal Tube Intubation

Reduction of Extension of Head on Neck (Grade)	Class of "Tongue Size" According to Samsoon and Young[4] *			
	4	3	2	1
1	D	A	A	A
2	E	B	B	A
3	E	C	B	B
4	E	D	C	B

* Different classes of "tongue size" according to the structures seen when the seated observer inspects the illuminated pharynx of a seated patient protruding his tongue maximally from a widely opened mouth and with the head in a neutral position. The classification is as follows: class 1 = soft palate, fauces, uvula, pillars seen; class 2 = soft palate, fauces, uvula seen; class 3 = soft palate and base of uvula seen; class 4= soft palate not visible at all.[4] The likelihood of difficult endotracheal intubation can be read from the table after allocating the patient to his or her particular tongue-size class and estimating the grade of reduction in head extension (see table 2). A = likelihood of difficulty (LOD) negligible (possibly 1%); B = LOD discernible (possibly 5%); C = LOD noteworthy (possibly 20%); D = LOD likely (possibly 50%); and E = LOD highly probable (possibly 95%).

Reproduced with modification with permission from Bellhouse and Doré.

evaluation of the atlanto-occipital extension may be performed by having the patient sit straight with head held erect and facing directly to the front. In this position, the occlusal surface of the upper teeth is horizontal and parallel to the ground. The patient then extends the atlanto-occipital joint as much as possible, and the examiner estimates the angle traversed by the occlusal surface of the upper teeth (fig. 5). For great accuracy a goniometer may be used to measure the angle traversed by the upper teeth, but most practitioners have confidence in their ability to make a simple visual estimate. Any reduction in extension can be expressed as a fraction of the normal and graded accordingly (table 2).[3] When the atlanto-occipital joint cannot be extended (as might be caused by a very small occipital–C1 gap), vigorous attempts to do so will cause the convexity of the cervical spine to bulge further anteriorly, which will push the larynx anteriorly and compromise a conventional laryngoscopic view.[32–34]

Based on the degree of atlanto-occipital extension (grades I–IV)[3] and class of tongue size (classes I–IV),[4] a two-variable analysis of intubation difficulty has been proposed.[3] Construction of table 3 allows prediction of the likelihood of difficult intubation based on these two anatomic factors. Although this table was prepared empirically from one individual's experience with 900 patients[3] and has not been subjected to statistical analysis, it is most likely that this analysis is qualitatively correct (*i.e.*, the two factors additively interact).

TABLE 2. Grading and Reduction of Atlantooccipital Extension

Grade*	Reduction of Atlantooccipital Extension†
1	None
2	One-third
3	Two-thirds
4	Complete

* Grade 1 = no appreciable reduction of extension; grade 2 = approximately one-third reduction; grade 3 = approximately two-thirds reduction; grade 4 = no appreciable extension.

† Reduction of atlantooccipital extension is from a normal of 35° (see fig. 5).

Reproduced with modification with permission from Bellhouse and Doré.

c. MANDIBULAR SPACE: The space anterior to the larynx has been easy to measure by ruler or by number of finger breadths and has been expressed as the thyromental or hyomental distance and/or the horizontal length of the mandible. The space anterior to the larynx determines how easily the laryngeal axis will fall in line with the pharyngeal axis when the atlanto-occipital joint is extended. If the thyromental distance is very short, the laryngeal axis will make a more acute angle with the pharyngeal axis, and it will be more difficult for atlanto-occipital extension to bring these two axes into line. The thyromental distance and horizontal length of the mandible have been found to inversely correlate well with the class of pharynx described above.[25,35] A thyromental distance greater than 6 cm and a horizontal length of the mandible greater than 9 cm are correlated with low tongue/pharyngeal size classification and strongly suggest that direct laryngoscopy will be relatively easy.[17,25,35]

The concept of the mandibular space helps to explain why a combination of tongue/pharynx size class and thyromental distance is also a very good two-variable predictor of difficult intubation. At laryngoscopy the line of

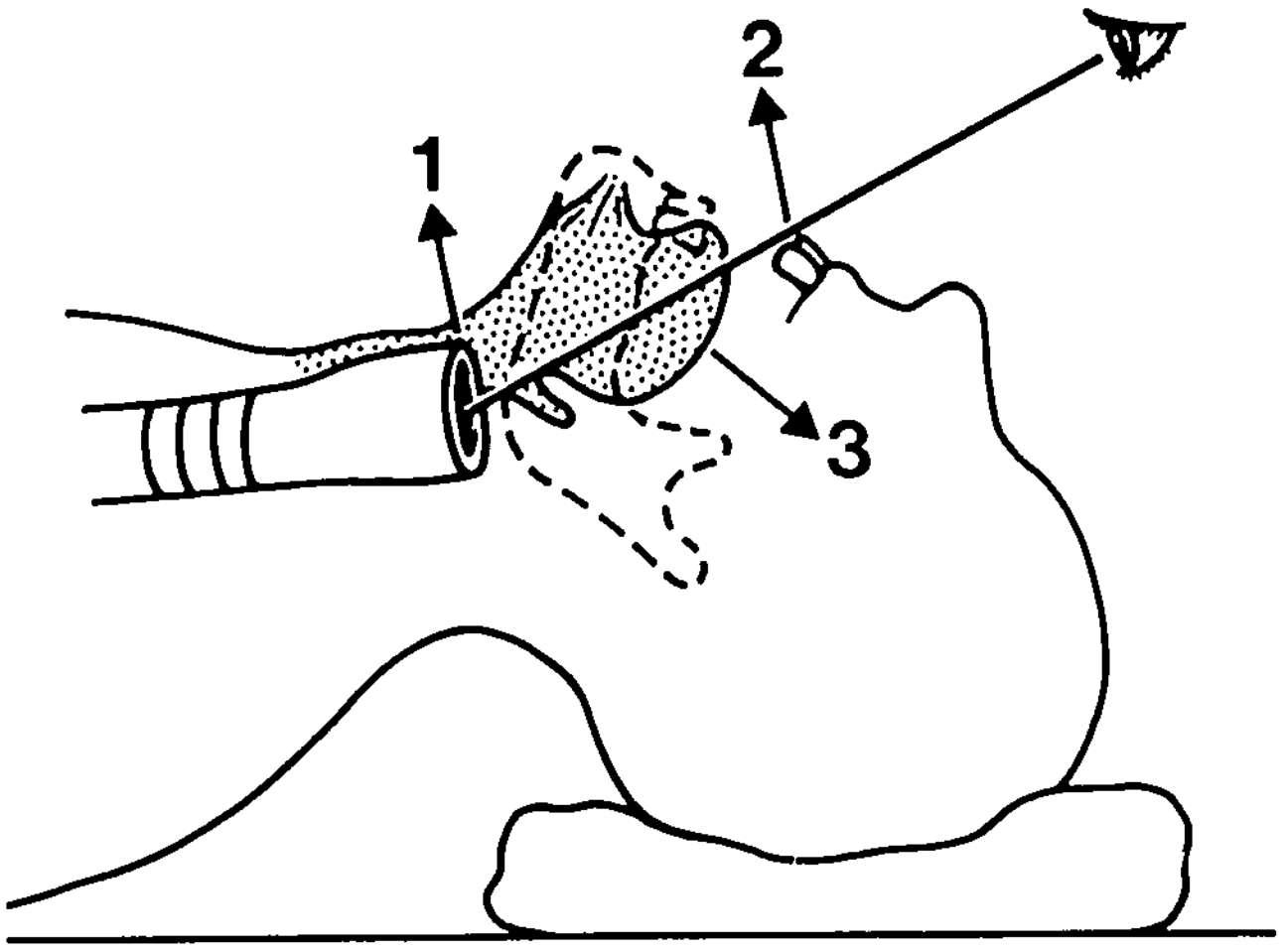

FIG. 6. The direct line of sight to the vocal cords may be blocked by a relatively anterior larynx (1), prominent upper incisors (2), and a large and posteriorly located tongue (3). Reproduced with permission from Cormack and Lehane.[5]

vision from the mouth to the vocal cords must be clear; figure 6 shows that difficulty may occur if the vocal cords, the upper teeth, or the tongue are displaced in the direction of the arrows.[5] Figure 7 shows a schematic view of the mandible, the plane of the line of vision to the vocal cords, the mandibular space (shaded), and the position of larynx. The mandibular space is the area bounded by the plane of the line of vision and the part of the mandibular arch in front of this plane.[3] When there is a large mandibular space (larynx is relatively posterior), the tongue is easily compressed into a large compartment and does not have to be pulled maximally forward in order to reveal the larynx. However, when there is a very small mandibular space (larynx is relatively anterior), the tongue has to be compressed into a much smaller compartment and must be pulled maximally forward in order to view the larynx.

These three tests (tongue *vs.* pharyngeal size, atlanto-occipital extension, and anterior mandibular space) have great appeal as routine preoperative airway evaluation tests because they are so simple and quick to perform and hold promise for identifying patients who are at risk for getting into potentially life-threatening situations. Although there have been no studies using all three of these predictors of difficult intubation, it seems logical that use of multiple predictors together would have much more power and accuracy than use of any one predictor alone.[3,10] Indeed, 100% accuracy has been found by one pair of investigators using all three predictors.[3] Future careful studies are needed to document the value of predicting intubation difficulty based on these three variables in patients with no airway disease.

A number of studies have attempted to use radiologic measurements to diagnose a difficult airway.[3,32,33,36] In these studies, the only measurements that were found to predict difficult intubation were those that in some way related to tongue/pharyngeal size, atlanto-occipital extension, or anterior mandibular space. However, there was considerable disagreement among these authors regarding which measurements were most valuable. In view of this disagreement, no single radiologic measurement can be used alone to determine the ease of intubation. Just as with the clinical tests discussed above, a combination of measurements would be a much more powerful predictive tool.[37] Since clinical tests of difficult intubation can be measured directly, quickly, simply, at no cost, and at any time, radiologic examination should only be rarely indicated in the preoperative evaluation of the airway.

5. *Difficult Airway Recognition Plan*

These observations suggest the following plan for routine evaluation of a patient's airway, assuming that the patient has no pathologic airway problem. 1) The medical record should be examined for a history of previous difficulty with managing the patient's airway. 2) Patients should be asked to open their mouth as widely as possible and extend their tongue. The mandibular opening (measured by ruler if there is doubt about limitation) and pharyngeal anatomy (uvula, tonsillar pillars, *etc.*) are observed. 3) The length of the submental space (mandible to hyoid bone) should be noted (measured by ruler, if there is a doubt). 4) Patients should be viewed from the side to see their ability to assume the sniff position (flexion of the neck on chest and extension of the head on the neck). The lateral view should also reveal any degree of maxillary overbite. 5) The patency of the nostrils must be assessed. 6) Systemic diseases, such as respiratory failure and coronary artery disease, that might place limits on, or require

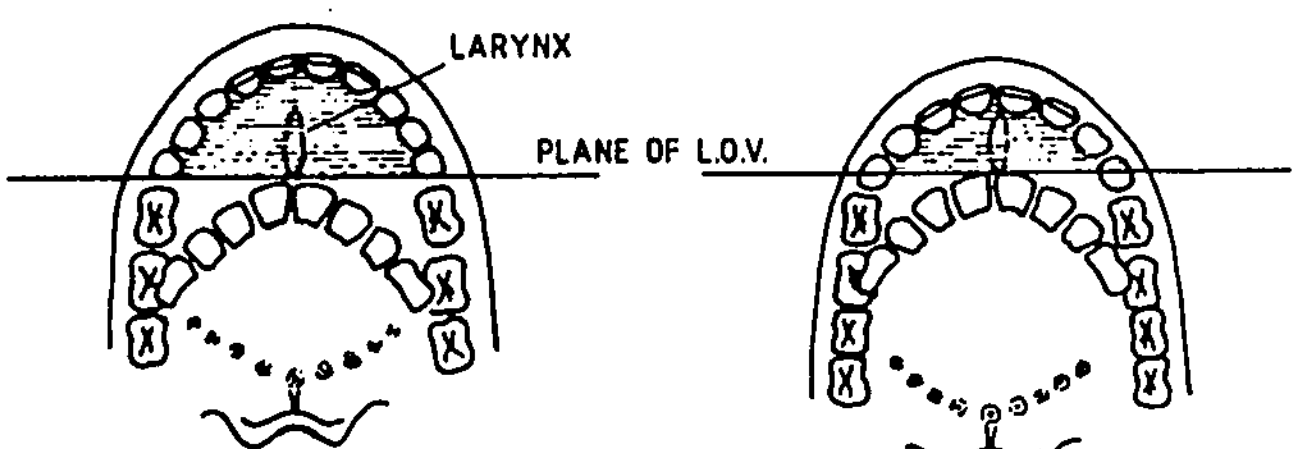

FIG. 7. The mandibular space. If the line of vision (LOV) to the larynx depicted in figure 6 were made perfectly horizontal and the observer was standing behind the top of the patient's head, then the most posterior structure along the line of vision would be the upper teeth, the most anterior structure would be the lower incisors, and the tongue and larynx would be between the upper and lower incisors. The mandibular space (the shaded area) is the area bounded by the plane of the line of vision and the part of the mandibular arch in front of this plane. Reproduced with permission from Bellhouse and Doré.[3]

special attention during an awake intubation, such as increased fraction of inspired oxygen ($F_{I_{O_2}}$) and prevention of sympathetic nervous system stimulation, respectively, should be noted. 7) In a few patients, an awake direct laryngoscopy (after adequate preparation; see below) may be indicated to help determine intubation difficulty. If the epiglottis and vocal cords can be seen, it is likely, but not certain,[38] that direct laryngoscopy will reveal the vocal cords and permit successful intubation during anesthesia and paralysis.

If it is recognized that the intubation or mask ventilation is going to be difficult, because of the presence of a pathologic factor(s) or a combination of anatomic factors (large tongue size, small mandibular space, or restricted atlanto-occipital extension), then airway patency should be secured and guaranteed (usually by intubation) while the patient remains awake.

B. AWAKE TRACHEAL INTUBATION

When management of the airway is expected to be difficult, either because of the presence of a pathologic factor(s) and/or a combination of anatomic factors, an endotracheal airway should be guaranteed while the patient is awake. Although awake intubation is generally much more time-consuming for the anesthesiologist and a more unpleasant experience for the patient, there are several compelling reasons why intubation should be done while a patient with a recognized difficult airway is still awake. First, and most important, the natural airway will be better maintained in most patients when they are awake ("no bridges are burned"). Second, in the awake patient enough muscle tone is maintained to keep the relevant upper airway structures (the base of the tongue, vallecula, epiglottis, larynx, esophagus, and posterior pharyngeal wall) separated from one another and much easier to identify. In the anesthetized and paralyzed patient, loss of muscle tone tends to cause these structures to collapse toward one another (*e.g.*, the tongue moves posteriorly), which distorts the anatomy.[39,40] Third, the larynx moves to a more anterior position with the induction of anesthesia and paralysis, which makes conventional intubation more difficult.[38] Thus, if a difficult intubation is anticipated, awake tracheal intubation is often indicated.

Crucial to the success of an awake tracheal intubation is proper preparation of the patient; most techniques will work well in most patients when they are quiet and cooperative and have a larynx that is nonreactive to physical stimuli.

1. Proper Preparation of the Patient for Awake Tracheal Intubation

Proper preparation begins with psychological preparation; awake intubation will proceed more easily in the patient who knows and agrees with what is going to happen. The patient should be monitored by electrocardiogram, automatic blood pressure, and pulse oximetry. Whenever hypoxemia and/or hypercapnia is present or may develop during awake intubation (*e.g.*, in the patient with a large upper airway mass and/or constriction, concurrent pulmonary parenchymal disease, sleep apnea, *etc.*), steps to augment $F_{I_{O_2}}$ and minute ventilation must be taken before beginning to anesthetize the airway and administer sedation. Although there are many ways to augment $F_{I_{O_2}}$, perhaps the best when using a fiberoptic bronchoscope (FOB) is to insufflate oxygen *via* the suction port while actually using the FOB. The oxygen flow increases the $F_{I_{O_2}}$, prevents fogging of the FOB tip, and blows secretions away from the tip of the FOB. On rare occasions it may be most prudent and safe for the patient to have minute ventilation (and oxygenation) assured before beginning an awake intubation by passing an intravenous catheter through the cricothyroid membrane and instituting transtracheal jet ventilation.[2,41,42] Finally, an anticholinergic drying agent allows better application of local anesthetic spray to the mucosa, improves visualization, and prevents laryngovagal reflexes.

Topical anesthesia is the primary anesthetic for awake intubation; if it is correctly performed it may be all that is needed in many patients. However, no matter what local anesthetic is applied to the mucosa, sufficient time must be allowed to anesthetize *all* of the relevant portions of the airway. If nasotracheal intubation is planned, both topical vasoconstrictors and local anesthetics should be applied to the nose. However, even careful topical anesthesia may be inadequate for awake laryngoscopy in all patients because the pressure receptors at the root of the tongue that cause the gag reflex are submucosal and are not blocked topically[43]; in this circumstance a bilateral block of the lingual branch of the glossopharyngeal nerve (IX) is required (see below).

There are two nerve blocks that are easy to perform, have a low risk of complication, and have a high degree of potential benefit. The first is bilateral blockage of the lingual branch of the nerve IX.[e] This easily performed block is effective in eliminating the gag reflex and hemodynamic response to a laryngoscopy. The patient's tongue is gently retracted laterally (by pulling the tip of the tongue with gauze and by pushing it with a tongue blade), exposing the palatoglossal arch (also called the anterior tonsillar pillar) (fig. 8). The base of the palatoglossal arch forms a U- or J-shaped band of tissue or bridge starting from the soft palate, running along the lateral pharyngeal wall to the lateral margin of the base of the tongue. The palatoglossal arch is pierced approximately 0.5 cm from the lateral margin of the root of the tongue at the point at which it joins the floor of the mouth (at the trough of the U- or J-shaped band of tissue) using a 25-G spinal

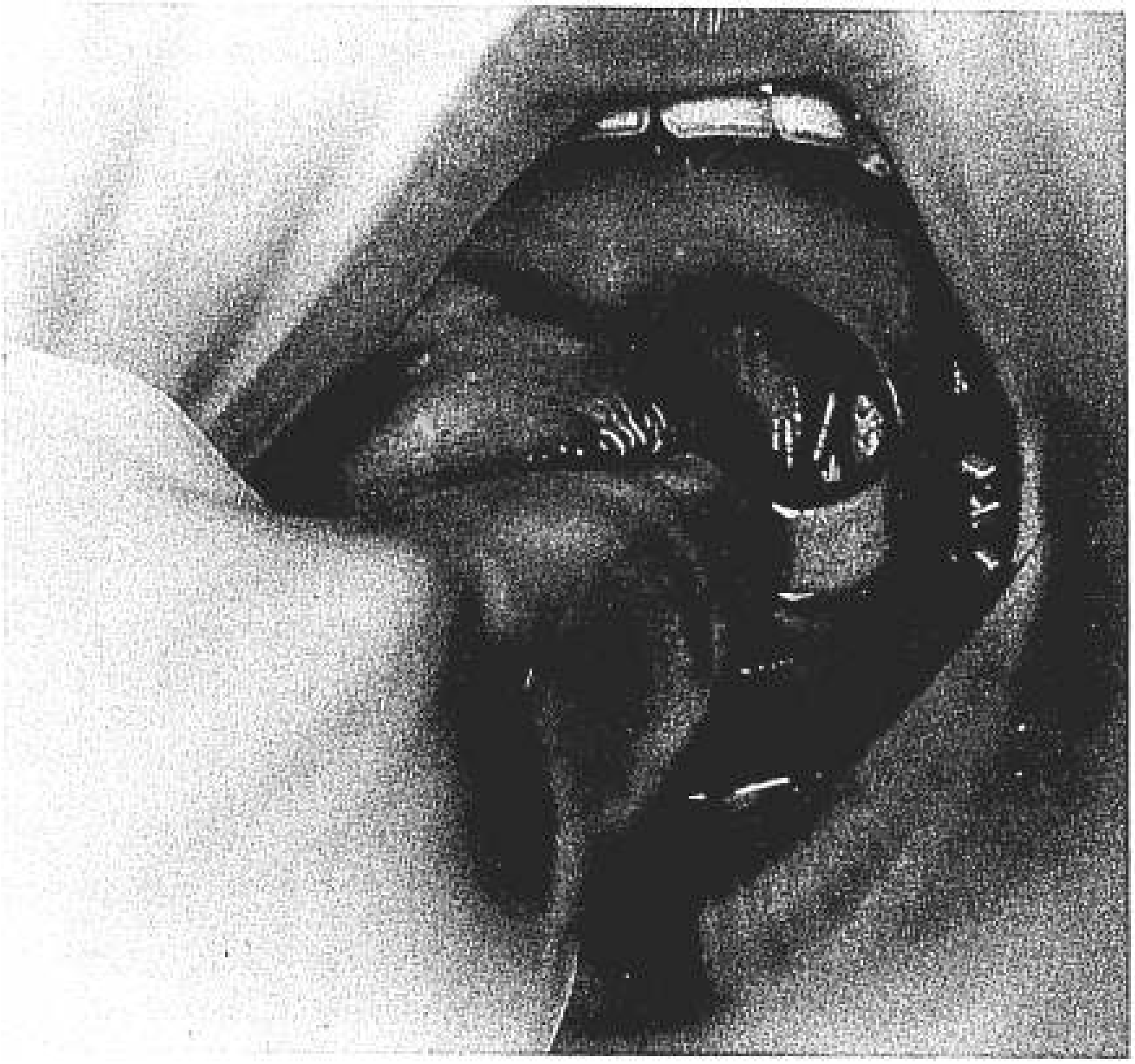

FIG. 8. The lingual branch of the glossopharyngeal nerve (IX) can be blocked by instilling 1–2 ml of a local anesthetic at the trough of the glossopalatal arch (this band of tissue sweeps upward from the lateral base of the tongue to the palate; it is commonly called the anterior pillar). The trough of the glossopalatal arch may be best visualized by retracting the tongue with a tongue blade (in this example a gloved finger is being used).

needle. The length of the spinal needle allows the local anesthetic syringe to be outside of the mouth and therefore not in the line of vision. The needle is inserted 0.5 cm and an aspiration test is performed. Air will enter the syringe if needle placement is too deep, causing the tip of the needle to exit from the posterior aspect of the palatoglossal arch and enter the oropharynx. An aspiration test is also helpful in reducing the possibility of an intravascular injection. Two milliliters of 2% lidocaine are slowly injected. The procedure is then repeated on the opposite side. Since the injection is made into loose sublingual tissue, there should be minimal resistance to injection. Within a few minutes the posterior third of the tongue and the pharyngeal side of the epiglottis (vallecula) should be adequately anesthetized to allow direct laryngoscopy with a Macintosh blade with minimal discomfort or gagging.

Although this block is directed primarily at the terminal portion of the glossopharyngeal nerve (lingual branch), studies using lidocaine and methylene blue dye have shown retrograde submucosal tracking of the agent and contact with proximal branches (pharyngeal and tonsillar). The larynx or laryngeal aspect of the epiglottis should not be touched since these areas are innervated by the superior laryngeal nerve, which remains fully intact, along with all other protective airway reflexes, if only a block of the lingual branch of nerve IX is performed. The ease and safety of this block greatly increase the use and success rate of awake laryngoscopy. Coupled with topical anesthesia of the larynx and upper trachea, it allows laryngoscopy and intubation to be performed with minimal hemodynamic consequences and without profound levels of central nervous system depression.

The second upper airway nerve block with a very favorable risk/benefit ratio is that of the internal branch of the superior laryngeal nerve. The superior laryngeal nerve block consists of application of local anesthetic superficial and/or deep to the thyrohyoid membrane between the superior lateral cornu of the thyroid cartilage and the inferior lateral margin of the cornu of the hyoid bone (the nerve pierces the membrane at this point and can be blocked on either side of the membrane).[44,45] An internal (within the mouth) superior laryngeal nerve block technique consists of painting the pyriform fossa with sponges that are soaked with local anesthetic. Superior laryngeal nerve block anesthetizes the lower pharynx, laryngeal epiglottis, vallecula, vestibule, aryepiglottic fold, and posterior rima glottis. Consequently, superior laryngeal nerve block in conjunction with lingual nerve block most often allows laryngoscopy with a Miller blade. Transtracheal block through the cricothyroid membrane may ordinarily be performed easily but the serious risk of bleeding, albeit low, from an aberrant thyroid vessel still exists,[2] and the block is unnecessary if topical anesthesia has been administered correctly.

Intravenous sedation can help the awake patient tolerate airway anesthesia and intubation by relieving anxiety and increasing the pain threshold. However, it is extremely important that the sedation be administered by titration to desired effect and that, when the patient is sedated, meaningful contact always be maintained between the anesthesiologist and the patient; meaningful contact means that the patient remains rational and oriented and obeys commands appropriately. The maintenance of meaningful contact is important for two reasons. First, respiratory depression will not be likely during the various local anesthetic procedures. Second, an awake, rational, oriented, and responsive patient will have a low likelihood of aspirating stomach contents even if the stomach is full. If the patient is not overly sedated, lower esophageal tone will be maintained (low likelihood of passive regurgitation), and the patient may be aware of the impending act of vomiting and can assist in turning the head and body to the side, opening the mouths for suctioning, delaying the next inhalation, and perhaps coughing (especially if the trachea is not well anesthetized).[16,46,47] In managing a patient with a difficult airway and a full stomach, management priorities must be set, and considering the low risk of aspiration in an awake patient (even if the upper airway is well anesthetized), tracheal intubation should be the top priority. Nevertheless, the risk of, and damage from, aspiration can be minimized by administration of sodium bicitra, ranitidine, metoclopramide, and nasogastric tube decompression prior to intubation (see section II.C.1).

2. *Choice of Tracheal Intubation Technique*

There are numerous ways to intubate the trachea. Although some anesthesiologists may have a strong preference for one of several specialized techniques, in the following discussion commonly used intubation techniques are arranged roughly in the order of greatest likelihood of success for the large majority of anesthesiologists for the large majority of patients.

a. CONVENTIONAL (DIRECT) LARYNGOSCOPY: Of all the intubation techniques, direct laryngoscopy of the awake patient is perhaps the most stimulating and requires by far the best patient preparation. In the properly and well prepared patient, direct laryngoscopy as a test (as well as the primary intubation technique) can be well tolerated. Blind nasotracheal intubation in a spontaneously breathing awake patient may certainly be worth a try before direct laryngoscopy if the nasotracheal route is acceptable, because blind nasotracheal intubation has a good chance of success and does not require the profound stimulation of laryngoscopy. However, the risk of causing upper airway bleeding and compromising subsequent fiberoptic efforts with an initial blind nasotracheal attempt must be considered. Similarly, blind orotracheal intubation through an airway intubator (see next section) may be tried (without laryngoscopy), since a 90% success rate with this intubation aid has been reported.[48,f]

Several aides to intubation under direct vision have been described for patients in whom the larynx is poorly visualized (even with posterior displacement of the larynx by external pressure on the anterior neck over the larynx and/or further flexion of the neck on the chest).[34] A small guiding stylet may be placed blindly around the epiglottis into the trachea. After the guiding stylet has been placed in the trachea, the ETT may be threaded over it and the stylet removed. The Eschmann stylet (gum elastic bougie) has been classically used for this purpose because it is malleable and the tip can be curved as desired.[15] More recently, use of a Laryngeal Tracheal Anesthesia kit® has been recommended for this purpose.[49] The long plastic spray end of the kit is first threaded through the Murphy eye of the ETT and then placed in the trachea. When an ETT is passed over either of these guiding stylets, the ETT should be oriented so that the Murphy eye and the tip of the ETT are at 12 o'clock (see Retrograde and Fiberoptic Techniques Sections, below).[49–51]

b. FLEXIBLE FIBEROPTIC ENDOSCOPY: A flexible FOB/laryngoscope is the most useful general purpose aid to awake intubation in the patient with a known difficult airway.[40,52] Fiberoptic-aided intubation can be performed by the oral or nasal route and is a less stimulating method of intubation than direct laryngoscopy. The only major impediment to the successful use of fiberoptic endoscopy–aided intubation in a properly prepared patient is the presence of significant amounts of blood and/or various types of secretions. Minimal amounts of secretions can be suctioned through the endoscope, although a better method for clearing secretions, for the purpose of visualization, is to blow the secretions away from the tip of the fiberoptic instrument by insufflating oxygen through the suction port of the instrument. Oxygen flow also serves as a defogging mechanism and increases the $F_{I_{O_2}}$. However, fogging of the tip of the FOB may be prevented by immersing the tip of the FOB in warm saline (37° C) a minute prior to insertion, which eliminates condensation of airway moisture upon a colder surface, and by applying antifog solution.

i. Positioning the Patient: The optimal position for fiberoptic laryngoscopy is provided by extension of the cervical spine, rather than cervical flexion as required for direct laryngoscopy, because extension tilts the larynx anteriorly and lifts the epiglottis off the posterior pharyngeal wall.[34]

ii. Aids to Fiberscope Insertion: Insertion of a rigid hollow conduit to bring the fiberoptic device close to the laryngeal aperture without requiring any manipulation on the part of the endoscopist can greatly facilitate fiberoptic intubation. For nasotracheal intubation, this conduit is most logically a nasotracheal tube passed into the oropharynx; at 15 cm in an average adult, the tip of the nasotracheal tube is only 1–2 cm proximal to the epiglottis. This distance still allows room for redirection of the tip of the FOB if necessary.[40] When passing the FOB through the nasotracheal tube, however, one must be careful not to pass the FOB through the Murphy eye of the nasotracheal tube.[53] For orotracheal intubation, numerous plastic oropharyngeal fiberoptic intubating aids have been described (Williams [the Airway Intubator],[40] Berman,[54] Patil *et al.*,[55] and Ovassapian and Dykes[56]). All of these oral fiberoptic intubation guides are designed to bring the tip of the FOB close to the laryngeal aperture without requiring much endoscopic skill (fig. 9).

iii. Passage of the Endotracheal Tube over the Fiberscope: Before its insertion, the FOB should be well lubricated and an appropriately sized ETT threaded over its proximal end (the range of ODs for FOBs is 1.8–6.7 mm, and the corresponding range of IDs of ETTs is 3.0–10.0 mm). Once the FOB has been passed into the trachea, the ETT can be passed over the FOB into the trachea and the FOB then withdrawn, the ETT adapter inserted, and the ETT connected to the breathing circuit. There are three reasons why an ETT may not follow a FOB guide into the trachea. First, if a relatively large, stiff ETT is aligned quite posteriorly, the ETT may carry a relatively thin flexible FOB into the esophagus even though the tip of the FOB is in the trachea.[57] An important clue to this problem is difficulty in removing the FOB from the ETT. Second, when the concavity of the ETT is facing anteriorly (defined as 12 o'clock), the Murphy eye and the tip of the ETT are at 90° to the right (at 3 o'clock). Consequently, passage of the tip of the ETT may be blocked by the right arytenoid cartilage and/or vocal cord; a 90° counterclockwise shift (Murphy eye and bevel tip now at 12 o'clock) will allow the tube to pass through the triangular upper part of the laryngeal opening into the trachea without impinging upon the right vocal cord.[49–51] Third, if the FOB exits the ETT *via* the Murphy eye (a nasal ETT is used as an intubation conduit), the FOB may enter the trachea, but it will be impossible to slide the ETT tube over the FOB into the trachea.[53] This problem may be prevented by loading the ETT onto the FOB prior to endoscopy or advancement of the FOB through the ETT only under direct vision.[53] After the ETT has been passed over the FOB into the trachea, the FOB is withdrawn and should be used to determine that the ETT has indeed entered the trachea and the carina-to-ETT distance. When the ETT is connected to the breathing circuit, capnography should also be used to confirm tracheal placement.

C. RETROGRADE TECHNIQUES (TRANSLARYNGEAL-GUIDED INTUBATION): Retrograde intubation techniques, in contrast to fiberoptic techniques, have been in use for several decades.[58,59] The indications for use of a retrograde intubation technique include trismus,[51] upper airway masses,[58,59] ankylosis of the jaw,[60,61] cervical arthritis,[60] and maxillofacial trauma.[62] Perhaps the best testimony to the efficacy of the retrograde intubation technique has been the impressive success rate found with severe maxillofacial trauma. Barriot and Riou[62] described 13 patients with maxillofacial fractures whose trachea could not be intubated after an average of six attempts over a duration of 18 min using antegrade techniques. In each of these initial 13 patients the trachea was successfully intubated with a retrograde intubation technique on the first attempt in less than 5 min.[62] As a result of this impressive success rate, in the next 6 patients with maxillofacial trauma, the initial intubation choice was a retrograde technique, and all of these 6 patients were successfully intubated on the first attempt in less than 5 min. The authors concluded that for maxillofacial trauma patients the retrograde technique was a safe, easy, rapid, dependable intubation method that required no special equipment. Despite this impressive literature,[51,58–62] retrograde intubation seems to be an underused elective or emergency intubation technique in the management of a difficult airway.

After properly preparing the patient (which in this instance may include local infiltration of the skin and subcutaneous tissue over the cricothyroid membrane with local anesthetic), the cricothyroid membrane is punctured with a suitably large thin-wall needle aligned with the airway and pointed approximately 30° cephalad from the perpendicular at the level of the cricothyroid membrane. After the tracheal lumen has been identified by aspirating air, a thin guide is passed through the needle until it spontaneously emerges out of the mouth or sometimes one of the nares. The retrograde guide may be either a guidewire or any type of a small-diameter luminal catheter that has a standard hub on the end of it. A guidewire is the author's first choice because a guidewire can subsequently be passed up the suction port of a FOB (see below). Occasionally the long thin guide will not spontaneously appear out the mouth, and one must look for it in the oropharynx by gentle retraction of the tongue with either a tongue blade or a laryngoscope. The guide is then pulled from the oropharynx with a clamp.

Once the guide is brought out of the mouth, both ends (the distal end emerging from the neck and the proximal end emerging from the mouth) should be pulled tight, so that the guide serves as a tightrope over which to sling or pass the ETT into the larynx. There are a number of ways of passing the guide into the ETT, including passing the guide 1) into the end hole and either straight up the lumen or to the outside of the lumen through the side hole (inside-out) and 2) into the side hole and up the lumen (outside-in).[61] The ETT may also be pulled into the trachea by tying the proximal end of the retrograde guide to one end of a long silk suture and the other end of the silk suture to the tip of the ETT; when the retrograde guide is pulled out from the neck the silk suture will pull the ETT into the trachea. The silk suture may be left attached to the ETT for use as a possible reintubation mechanism.[8]

No studies have been done to quantitate the exact incidence of successful passage of the ETT over the retrograde guide with the above techniques. However, most reports indicate that a large majority of ETTs will pass through the laryngeal aperture.[51,58–62] However, since the discrepancy between the OD of the guide and the ID of the ETT may be large, there is plenty of room inside the ETT for the ETT to move (railroad) in any direction around the guide and encounter an obstruction. There are three principal sites of obstruction. First, the tip of the ETT may impact on the right vocal cord and not enter the trachea. In this situation, a 90° counterclockwise rotation is necessary.[49–51] Second, since both ends of the guide are being pulled tight, the guide is forced to pass through the most anterior and narrow part of the glottis; therefore, the passage of the ETT may be blocked by the epiglottis/vallecula and not enter the trachea. With both of these sites of obstruction, the ETT will not be in the trachea upon removal of the guide. Third, even if the ETT passes through the laryngeal aperture, the tip or the side hole of the ETT, depending on the technique used, must stop at the point where the guide enters the trachea from the neck, which is only 1.0–2.0 cm caudad from the vocal cords. Since the ETT is in the trachea only a very short distance, it may be displaced from the trachea when the guide is removed. One suggested solution to the displacement problem has been to pass an appropriately sized FOB through the lumen of the ETT, well past the entry point of the guide into the trachea, removing the guide, and then passing the ETT over the much larger FOB.[64]

The bigger the OD of the guide in relation to the ID of the ETT, the less the chance the ETT can move off the track of the guide and the greater the chance the ETT will follow the retrograde guide into the trachea. In an attempt to decrease the discrepancy between the ID of the ETT and the OD of the retrograde guide, there have been several attempts[65–67] to stiffen and enlarge the retrograde guide by passing another slightly larger-ID guide antegrade over the retrograde guide. In other words, the primary retrograde guide is enlarged by a secondary antegrade guide in a one-step Seldinger type technique. Catheters used as antegrade guides over the retrograde guides have consisted of suction catheters, nasogastric tubes, Eschmann stylets,[65] tube changers,[66] and the plastic housing of central venous and arterial guidewires.[67] However, all of these antegrade guides over the retrograde guide suffer from the disadvantages that they are passed blindly and that they must stop at the point where the retrograde guide enters the trachea from the neck.

A FOB with a suction and/or biopsy port makes an excellent antegrade guide over a retrograde guide for several reasons.[68–70] First, if the retrograde guide is a long (125 cm or longer) guidewire, it can be passed up the suction port of the FOB and out the control head of the FOB (usually 70 cm in length). The rubber casing around the proximal end of the suction port must be removed in order for the guidewire to pass out the proximal end of the FOB. The OD of the guidewire is very close to the ID of the suction port, and therefore the FOB cannot railroad or ricochet off the retrograde guidewire track. Second, the suction and/or biopsy ports of most FOBs occupy a central position within the FOB, thereby further eliminating the chance that the antegrade guide can take a path different from the retrograde guide. Third, if the OD of the FOB is large (since a choice may be available), the ETT will much more likely follow the FOB into the trachea. Fourth, and most importantly, the anesthesiologist can see the FOB enter the trachea as the retrograde guide is being followed back through the laryngeal aperture; when the position of the FOB within the trachea is confirmed by viewing the tracheal cartilages, carina, and the entrance of the guidewire into the suction port of FOB, the FOB can be advanced a few centimeters further (beyond the point of entry of the retrograde guide into the trachea) by slackening the guidewire at the exterior insertion point. The retrograde guidewire can then be removed by pulling it out from the proximal suction port of the FOB, which avoids contaminating the tracheal wound with mouth contents, while the anesthesiologist remains assured of continued intratracheal location of the FOB by viewing the trachea. The FOB can then be inserted further into the trachea (closer to the carina) and the preloaded ETT passed over the FOB. Thus, this technique allows one directly to visualize entry into the trachea. In addition, the central position of the suction port within the FOB and the close approximation of the OD of the retrograde guidewire to the ID of the suction port of the FOB forces the FOB to follow faithfully the guidewire into the trachea.

If retrograde nasotracheal intubation is required, a small lubricated hollow catheter (many types are acceptable for this purpose) is passed through the nose, into the oropharynx, and, after the tip is grasped with a clamp, out the mouth.[59] The tip of the nasal–os catheter is then tied to the cricothyroid membrane–os guide (catheter or wire) and the nasal–os catheter pulled tight out the nasal opening; the nasal–os to cricothyroid membrane–os loop out the mouth will straighten in the oropharynx, and a resultant nasal-cricothyroid membrane guiding catheter is created. The ETT may now be threaded over the nasotracheal guide into the trachea.

d. COMBINATIONS OF CONVENTIONAL, FIBEROPTIC, AND RETROGRADE TECHNIQUES: This review has already described combining retrograde with fiberoptic techniques.[64,68–70] In a properly prepared patient, direct laryngoscopy can be combined with retrograde technique.[h] The retrograde guide is used either to identify the laryngeal aperture or to simply lift a potentially obstructing epiglottis or tongue out of the way.[h] Similarly, direct laryngoscopy can facilitate placing the tip of a FOB near the laryngeal aperture in order to minimize the amount of manipulation required.

e. OTHER RECENTLY INTRODUCED AWAKE INTUBATION TECHNIQUES: *i. New Laryngoscope/Retraction Blades:* Since the oral, pharyngeal, and laryngeal axes form a C-shaped curve around the tongue and epiglottis, and the purpose of a laryngoscope blade is to retract the tongue and epiglottis so that the radius of curvature becomes very large (*i.e.*, the C-shaped curve becomes very shallow and/or a straight line), it is not surprising that there have been continued efforts to develop a laryngoscope or retraction blade that will facilitate getting the tongue and epiglottis out of the line of vision. Laryngoscope blades that were introduced prior to 1986 and that are[71] and are not[72] commercially available have been recently reviewed and will not be mentioned here. Since 1986 several new commercially available laryngoscope blades have been described in the literature. Two of these new laryngoscope blades angle the blade in a new way in an effort to more easily get around the C-shaped curve. Another new blade carries a fiberoptic bundle that essentially places the endoscopist's eye near the tip of the blade. Another new blade is tubular and is designed for dealing with a compressed edematous upper airway. Finally, one new blade carries a large suction port to the tip of the blade.

The first of the new angled laryngoscope blades is essentially a straight blade modified by bending the blade forward through 45° at the midpoint so that from the side the blade has a broad V shape (The Belscope, Avulunga Pty. Ltd., N.S.W., Australia).[11] While the view provided by the angled laryngoscope is framed by the laryngoscope and the right side of the patient's mouth, which is similar to the view obtained with the Macintosh blade, the angle and the horizontal distal component (half) on this new blade does not obscure the anterior part of the view as much as the curve on the Macintosh blade does. The blade is inserted from the right corner of the mouth and, as with a Macintosh blade, the blade follows an anatomic C-shaped arc from teeth to larynx. However, as with a straight blade, the tip is alternately advanced and the handle rotated backward until the tip is posterior to the epiglottis so that the epiglottis can be lifted anteriorly. The use of a single angle, rather than a continuous curve, requires less compression and anterior displacement of the tongue into the mandibular space. In addition, since the epiglottis is lifted directly by the tip of the blade, the epiglottis does not obstruct the view of the larynx. In the rare situation where the proximal anterior curvature of the tongue or the angle on the blade cannot be retracted out of the line of vision, a prism mechanism is provided that permits a view around such an obstruction. The reader is referred to the original report for further details of use.[11] Thus, this new angled laryngoscope appears to combine the attractive features of both straight- and curve-bladed laryngoscopes in addition to the refraction that is possible when a prism is used.

There are several potential drawbacks to this blade. First, it has not been widely evaluated, and therefore newcomers may not share the enthusiasm that the inventor and his colleagues have for the blade. Since the angled blade feels different than other blades, practice is essential and depending on the degree of practice required, many anesthesiologists may not be willing to commit the time and money to developing the necessary skill with this blade. Third, since a prism may be necessary in the most difficult of cases, which may arise unexpectedly, fogging of the prism may become a problem precisely in a situation and at a time when it is most undesirable. Clearly, this new angled laryngoscope will require further evaluation.

The second newly developed angled laryngoscope blade is a double-angled blade (Anesthesia Medical Specialties, Cerritos, CA) that incorporates two incremental curves (20° and 30°) and a wide, flat blade shaft.[73] This laryngoscope blade is also designed to combine the advantages of the curved and straight blades and to eliminate their disadvantages. The blade reportedly provides excellent visualization of the glottis, good control of the tongue and epiglottis, and minimal risk of damaging the teeth. The high point (posteriorly projecting) of the arc of the curved blade is eliminated with the double-angled blade. The incremental angles on the double-angled blade fit the anatomy of the pharynx and allow the hyoid bone and epiglottis to be lifted effectively, using the tip as one would with either a straight or curved blade. Since there is no flange on the blade (the tongue and epiglottis are controlled by the wide shaft of the blade), there is much more room to pass the ETT than there is with a straight blade. Again, much wider experience with this blade is necessary before it can be generally recommended.

Another new laryngoscope blade, the Bullard® laryngoscope (Circon ACMI, Stamford, CT), carries along the posterior aspect of the blade a fiberoptic bundle, which essentially places the endoscopist's eye near the tip of the blade and makes visualization of the larynx much easier.[74,75,i] The Bullard blade is very broad and shaped as a curved L or hockey stick. Once the blade has been rotated around the tongue, so that the tip of the blade is at the base of the tongue, upward movement exerted along the axis of the laryngoscope handle is required in order to visualize the larynx. The tip of the laryngoscope blade can also be used as a Miller blade (to lift the epiglottis) or a Macintosh-type blade (placed in the vallecula), and these maneuvers are sometimes necessary. Since the excellent visualization of the larynx is based on the presence of a fiberoptic bundle at the tip of the blade, positioning the head in the usual sniff position is unnecessary. Thus, the greatest advantage of the Bullard intubating laryngoscope seems to be in situations where one would not want to move the head at all, such as cervical spine fractures.

In most patients, the view with the Bullard blade is, in the author's experience, very good and easy to obtain. However, the L-shaped curvature is so broad and the blade so wide that there is little room posteriorly and laterally in which to correctly align the distal end of the ETT with the long axis of the trachea to allow easy passage of the ETT into the trachea. The manufacturer originally proposed three ways to align the tip of the ETT with the axis of the trachea: use of a curved stylet in the ETT that is independent of (unattached to) the blade; use of a ETT with a directional tip; and use of an intubating forceps system that is incorporated within the blade. Now, however, the manufacturer has abandoned the use of the intubating forceps and instead recommends an intubating stylet that is an integral part of the blade and hugs the posterior and lateral aspects of the blade.[j] In the author's experience, the intubating stylet correctly aligns the ETT, and intubation with this new intubating mechanism has been made much easier. Currently, research is underway to take advantage of the Bullard fiberoptic concept by placing a fiberoptic bundle on a blade (Augustine Medical, Inc.) that is shaped in such a way as to create even more room in which to better align and pass an ETT.[k] The tip of this new blade encircles the hyoid-epiglottic ligament, which lifts the epiglottis out of the way and allows the ETT to pass under the epiglottis.

Standard laryngoscope blades are sometimes unable to open sufficient viewing space in the presence of massive upper airway edema or inflammatory/scar tissue, since bulging mucosa or redundant tissue typically envelops the blade and thereby obliterates both the viewing space and the light source of the standard open-sided laryngoscope blade. A two-piece tubular pharyngolaryngoscope that is now available (model 52-2220, Pilling Instruments, Ft. Washington, PA), if modified, can create a larger field of view within the laryngopharynx by not allowing surrounding and compressing edematous mucosa, masses, or scar tissue to obstruct the view.[76,77] In addition, this tubular laryngoscope has a dual fiberoptic intraluminal light source (each half has its own light source) that is protected from obstruction by surrounding edematous mucosa, blood or secretions, intraoral masses, or scar tissue. An orotracheal tube is placed through the lumen of the tubular laryngoscope and into the glottis during direct suspension laryngoscopy with fiberoptic illumination, and then the tubular scope is divided in half along the long axis of the scope, and the two halves are removed from around the ETT. The tubular laryngoscope has been successfully used in patients with edematous upper airways, acquired microstomia (thermal or lye injury), and intraoral cystic hygroma. Disadvantages of tubular laryngoscopy for tracheal intubation include a temporarily obstructed view of the patient's larynx and glottis as the ETT is advanced into the trachea and difficulty in stabilizing an ETT as the two pieces of the tubular laryngoscope are dismantled for removal. In addition, the two-piece laryngoscope requires an external fiberoptic light source. As with the other new blades described above, a much wider experience will be necessary before the exact utility of this blade can be determined.

Finally, laryngoscope blades that have a suction port at the tip of the blade are a logical advance.[78] Profuse oral secretions, oropharyngeal bleeding, and regurgitation can block the laryngoscopic view at any time and require suctioning by an independent mechanism. In addition, a suction port allows insufflation of oxygen and, in some cases, blowing of the secretions out of the way, rather than trying to pull them out with suction, to clear the view. It should be noted that the Bullard and Augustine laryngoscopes already have a suction port built into the tip.

ii. New Illuminating Intubating Stylets: A malleable illuminating stylet for intubation is different from all other intubating techniques in that entry into the trachea is indicated by a jack-o'-lantern effect observed externally in the anterior neck, which does not appear if the lighted stylet is anywhere else. A study using preplaced tubes in adult cadavers demonstrated 96–98% accuracy in determination of tube position (trachea *vs.* esophagus *vs.* upper airway) by emergency room physicians and paramedics in an average time of less than 5 s.[79] For extremes of physical habitus, such as the very thin or young (false positive) and the morbidly obese (false negative) or patients with very thick necks (false negative), a question may arise as to the location of the illuminating stylet.

The TUBE-STAT™ (Xomed-treace, Jacksonville, FL) should be used rather than the Flexi-lum™ because the former has a brighter light and the bulb is within the plastic covering sleeve whereas, the latter is a dimmer surgical light, the bulb of which can become disconnected.[80] The illuminating stylet should be lightly lubricated and then inserted into the ETT, size 5.0 mm or larger (bulb diameter is 3.8 mm), until the bulb is just within the end of the tube lumen. The end of the stylet and ETT are then flexed through an approximate 90° arc (hockey stick shape), beginning just proximal to the proximal end of the tube cuff. After the patient has been appropriately prepared for awake intubation, the patient should then be asked to protrude the tongue. As the anesthesiologist inserts the ETT around the tongue, the transillumination will appear abruptly as the bulb passes the bulk of the tongue and epiglottis, just superior to the thyroid cartilage. When the light and the ETT enter the larynx itself, a jack-o'-lantern effect is produced, which is quite prominent if the room lights are dimmed.[81] The transilluminated glow from within the trachea is bright and circumscribed at the level of the larynx or sternal notch, whereas that from the esophagus is very dull and diffuse. In very thin patients a light can sometimes be seen at the sternal notch when the stylet is intraesophageal, but it is weak, even in total darkness, and it cannot be seen at all in bright, ambient lighting. If the stylet is deviated laterally within the oropharynx, the light appears well off the midline. When the light position indicates that the tube has passed the glottis, the tube can be slipped off the stylet and advanced further into the trachea. As the ETT is advanced into the trachea, the light in the neck may seem to separate and form an expanding illuminated dumbbell shape as the ETT enters the thorax. The usual steps to confirm bilateral gas exchange through the ETT should then follow. A variation of this process using the Airway Intubator, which prevents lateral and posterior (into the esophagus) movement of the stylet and ETT, has been suggested.[82]

The illuminating stylet has been found to be just as efficient as direct laryngoscopy in routine intubations,[83] in children with abnormal airways,[84] and for difficult intubation in adults,[85,86] and was faster and required significantly less attempts than blind nasotracheal intubation in awake patients with spinal column problems.[87] Since use of the illuminating intubating stylet does not necessarily require the sniff position (although it may be easier to use in the sniff position[82]), it may be uniquely suited for awake intubations in patients with spinal cord and mandibular/face disorders.[83–87] Application of cricoid pressure and the use of a nasogastric tube does not decrease the success rate of this technique.[85] It is clear that the technique may be useful as a backup intubation method when direct laryngoscopy has failed. Anything that interferes with transmission of the light from the neck, such as severe anterior neck scarring, flexion contractions, excess cervical adipose tissue, cervical masses, covering of the bulb with blood and/or secretions, and inability to darken the room lights, decreases the effectiveness of the technique.

f. TRACHEOSTOMY: Occasionally all attempts at intubation fail. Prior to abandoning the awake intubation procedure, cancelling surgery, or performing an elective tracheostomy, three responses seem reasonable in most patients. First, the patient may need to be better prepared for an awake intubation. This may mean repeating topical local anesthesia, local nerve block, or intravenous sedation/analgesia. Second, it may be prudent to change the intubation technique. For example, if any one of the several techniques discussed in this paper has not been successful, any one of the remaining techniques may be successful. Third, combining several intubation techniques may increase the success rate. However, when all of the above fail and cancellation of surgery is not appropriate, tracheostomy is indicated.

Elective tracheostomy is often the best first intubation choice in conditions such as 1) laryngeal fracture or disruption, 2) upper airway abscesses located along, and distorting, the route of intubation,[88] and 3) basilar skull fractures with cerebrospinal fluid leak and/or nasal fractures or deformity that contraindicate a nasotracheal tube, as well as a requirement for arch bars and jaw wiring that contraindicate an orotracheal tube.[1] While the tracheostomy is performed by a surgeon, the anesthesiologist must obviously maintain oxygenation and ventilation as well as he or she can. Although surgeons have recently reported using a percutaneous Seldinger-type tracheostomy technique (minitracheostomy),[89] the procedure has had high rates of hemorrhage, misplacement, surgical emphysema, and pneumothorax.[90]

C. THE ANESTHETIZED PATIENT WHOSE TRACHEA IS DIFFICULT TO INTUBATE

There are three general situations in which an anesthesiologist will be required to intubate the trachea of an unconscious or anesthetized patient whose airway is difficult to manage. First, the patient may already be unconscious (*e.g.*, posttrauma) or anesthetized (*e.g.*, drug overdose). Second, the patient may absolutely refuse or not tolerate awake intubation (*e.g.*, a child, a mentally retarded patient, or an intoxicated combative patient [see dashed line, fig. 3]). Third, and perhaps most commonly, the anesthesiologist may fail to recognize intubation difficulty on the preoperative evaluation. Of course, even in the first two situations above, the preoperative airway evaluation is very important because the findings may dictate the choice of intubation technique. In all of the situations above, the patient may in addition have a full stomach.

1. Preparation of the Patient With a Full Stomach for the Induction of General Anesthesia

There are several treatments that can be used prior to induction to decrease the risk of, or damage from, aspiration of gastric contents in patients suspected of having a full stomach. First, sodium bicitra immediately, and ranitidine after 30 min, will increase the *p*H of gastric fluid. Second, gastric emptying may be enhanced immediately by decompression of the stomach with a nasogastric tube (a nasogastric tube should be withdrawn prior to induction so as to not disrupt esophageal sphincters and serve as a wick for regurgitation) and by intravenous metoclopramide within 3 min (patients with severe gastrointestinal problems [obstruction, perforation, or peritonitis] may have increased emptying time with metoclopramide). Third, the administration of induction drugs should be done in rapid sequence. Fourth, cricoid pressure should be applied. When cricoid pressure is applied, the head must be held in extension; otherwise, the head will flex at the atlanto-occipital joint, making the intubation more difficult.[16] Fifth, the position of the head, which is controversial, may be either slightly (15°) reverse Trendelberg (which prevents regurgitation but promotes aspiration of mouth contents) or Trendelberg (which promotes regurgitation but prevents aspiration of mouth contents), but once the mouth contains gastric contents the patient should be put in the Trendelberg position (see section II.C.3).

2. Choice of Intubation Technique

All of the intubation techniques that were described for the awake patient can be used in the unconscious or anesthetized patient without modification. However, direct and fiberoptic laryngoscopy may be slightly more difficult in the paralyzed anesthetized patient compared to the awake patient because the larynx may become more anterior relative to other structures because of relaxation of oral and pharyngeal muscles.[38] In addition, the upper airway structures may coalesce into a horizontal plane instead of separating out in a vertical plane.[39,40]

In the anesthetized patient whose trachea has proven to be difficult to intubate, it is necessary to try to maintain gas exchange between intubation attempts by mask ventilation and also during intubation attempts whenever possible. Ventilation *via* mask must be interrupted when intubation is attempted by direct laryngoscopy with any of the new laryngoscopy/retraction blades and when the illuminating stylet is used. With a retrograde technique, it is necessary to interrupt ventilation only when bringing the retrograde guide out of the mouth and when the antegrade guide (including a FOB) and/or ETT is being passed over the retrograde guide. Ventilation of the anesthetized patient's lungs may be maintained during a nasal fiberoptic intubation by placing an ETT adapter into an oral airway (Nosworthy chimney),[91] or Airway Intubator[47] or soft nasopharyngeal airway in the other nares and connecting the ETT adapter to the anesthesia circle system. Whenever ventilation is interrupted during any intubation method (*i.e.*, the patient is apneic), the onset of arterial oxygen desaturation can be significantly delayed by insufflating 3 l/min oxygen through a naso- or oropharyngeal catheter.[92]

Positive pressure ventilation may be continuously maintained during fiberoptic endoscopy-aided orotracheal intubation by using an anesthesia mask that has a special fiberoptic instrument port that is covered by a self-sealing diaphragm (instead of standard mask) along with an airway intubator (instead of the standard oropharyngeal airway).[40,93] While a positive pressure seal is continuously maintained with the anesthesia mask with fiberoptic dia-

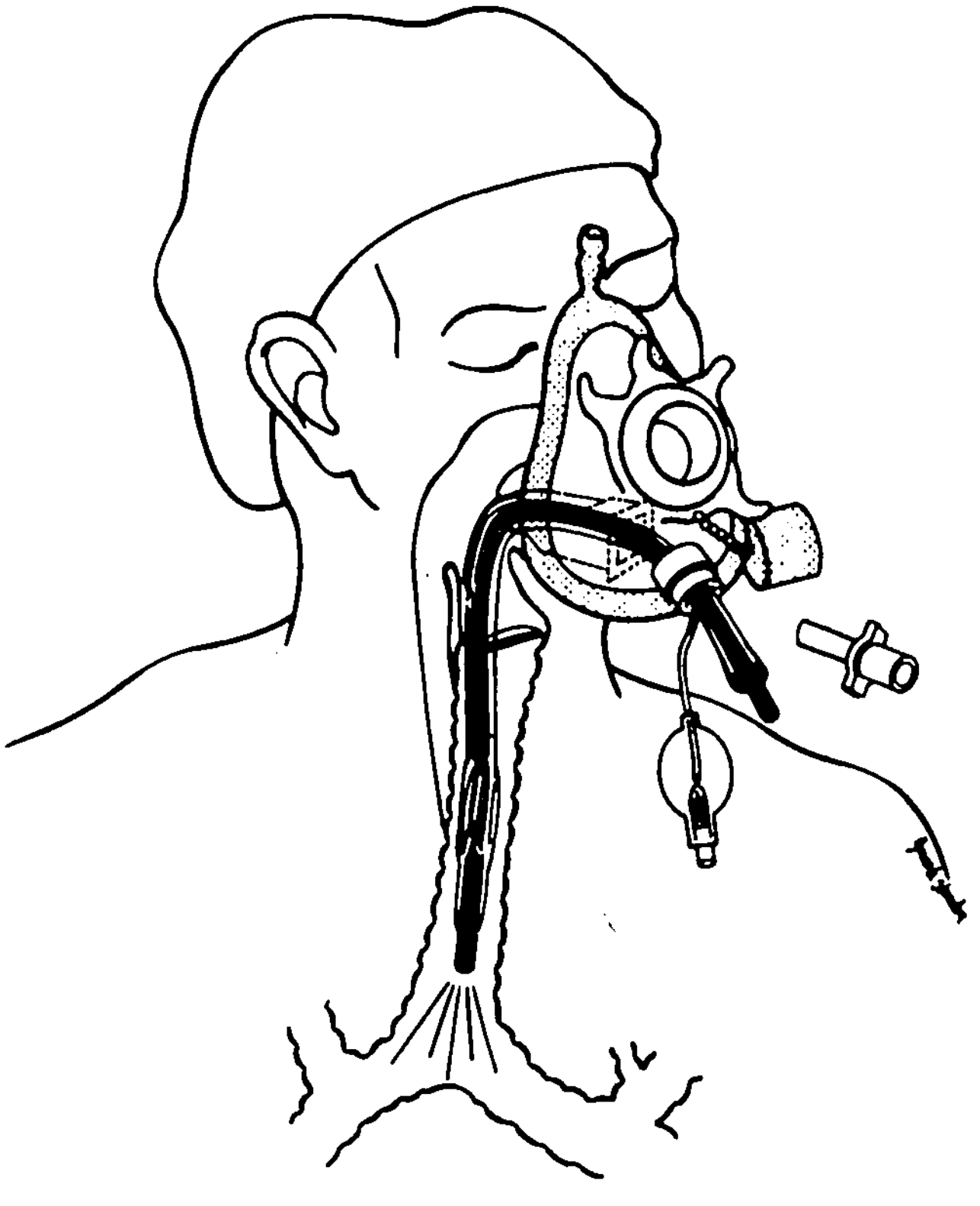

FIG. 9. Use of the anesthesia mask with diaphragm and oral airway intubator as aids to fiberoptic tracheal intubation in an anesthetized (and paralyzed) patient. Reproduced with permission from Rogers and Benumof.[40]

phragm, the fiberoptic instrument is passed through the self-sealing port, then through the airway intubator, and finally into the trachea. The ETT is pushed over the fiberoptic stylet (fig. 9). Since ventilation can be continuously maintained around the fiberoptic instrument throughout this intubation procedure, it is the author's choice in the anesthetized patient whose trachea cannot be intubated conventionally.

It is extremely important to realize that the amount of laryngeal edema and bleeding will very likely increase after every intubation attempt. Although laryngeal edema and bleeding can occur with any intubation method it is most common after use of a laryngoscope or retraction blade. Consequently, if there does not appear to be anything really new or different that can be atraumatically and quickly tried (better sniff position, new blade, new technique, much more experienced laryngoscopist, *etc.*)[16] after a few failed intubation attempts, and ventilation by mask can still be maintained, it is prudent to cease attempting to intubate the trachea and to awaken the patient, continue anesthesia *via* mask ventilation, or perform a tracheostomy or cricothyrotomy before the ability to ventilate the lungs *via* mask is lost (fig. 3). In fact, the most common scenario in the respiratory catastrophes in the ASA Closed Claim Study was the development of progressive difficulty in ventilating *via* mask in between persistent and prolonged failed intubation attempts; the final result was inability to ventilate *via* mask and provide gas exchange.[2] If the surgical procedure is not urgent, awakening the patient and doing the procedure another day will allow for better planning. Still many other cases may be done (and may have to be done) *via* mask ventilation (*e.g.*, caesarean section) if it is reasonably easy. Finally, in some cases the trachea will have to be intubated by tracheostomy or cricothyrotomy (*e.g.*, thoracotomy, intracranial/head/neck cases, and cases in the prone position).

3. Management of Regurgitation or Vomiting in the Anesthetized Patient

If regurgitation or vomiting occur at any time during attempts at ETT intubation in an anesthetized patient, then there are a number of therapeutic steps that must be taken. First, the patient must be put in the Trendelberg position, and the head, and perhaps the body, turned to the left. Second, the mouth and pharynx should be suctioned with a large bore catheter. Tracheal intubation may then be tried with the patient on his or her left side; the advantage of this maneuver is that the tongue may be more out of the way, but the disadvantage is that this intubating position may be unfamiliar to most anesthesiologists. If the ETT has been passed into the esophagus it may be left there; the advantage is that the ETT may decompress the stomach and perhaps guide (by negative example) future intubation attempts. However, the disadvantage is that it may be harder to obtain a satisfactory mask seal between intubation attempts even if the esophageal ETT is sharply bent off to the side by the rim of the mask. Once the airway is secured and aspiration of gastric contents is believed to have occurred, standard treatment consists of suctioning, mechanical ventilation, positive end-expiratory pressure, fiberoptic guided saline lavage, and suction, and perhaps steroids and appropriate antibiotics after specific cultures and sensitivities are available.

D. THE PATIENT WHOSE LUNGS CANNOT BE VENTILATED BY MASK AND WHOSE TRACHEA CANNOT BE INTUBATED

In rare cases, it is impossible either to ventilate the lungs of a patient *via* mask or to intubate the trachea (table 1). Under these circumstances, unless there is an alternative ventilation method immediately available, death will rapidly ensue. In the past few years, three alternative ventilation methods have been described that can be instituted blindly and quickly and that appear to have a low risk/benefit ratio; these are the esophageal tracheal Combitube (ETC), Laryngeal Mask Airway (LMA), and transtracheal jet ventilation (TTJV). Use of the ETC in anesthesia and intensive care is based on only a few case reports. The LMA is reasonably effective (90%) but will not be approved by the United States Food and Drug Administration until at least late 1991. TTJV is extremely effective and well tested and was the subject of a recent review.[2]

1. The Combitube

The ETC (Sheridan Catheter Corporation, Argyle, NY) is a plastic twin-lumen tube with an OD of 13 mm (fig. 10). One lumen resembles an ETT, and the other lumen resembles an esophageal obturator airway (EOA) (with the distal end stoppered or closed). A special 100-ml proximal pharyngeal balloon is located on the ETC so that when the ETC is properly positioned, the pharyngeal balloon will fill the space between the root of the tongue and the soft palate. The inflated proximal balloon serves to seal the mouth and nose cavities. Just distal to the pharyngeal balloon, but proximal to the level of the larynx, there are perforations in the esophageal lumen. A distal smaller (10-ml) cuff, similar to an ETT cuff, serves to seal either the esophagus or trachea when inflated. The ETC is inserted blindly, and, in terms of ability to ventilate the patient, it does not matter whether the ETC enters the trachea or esophagus: if the ETC enters the esophagus

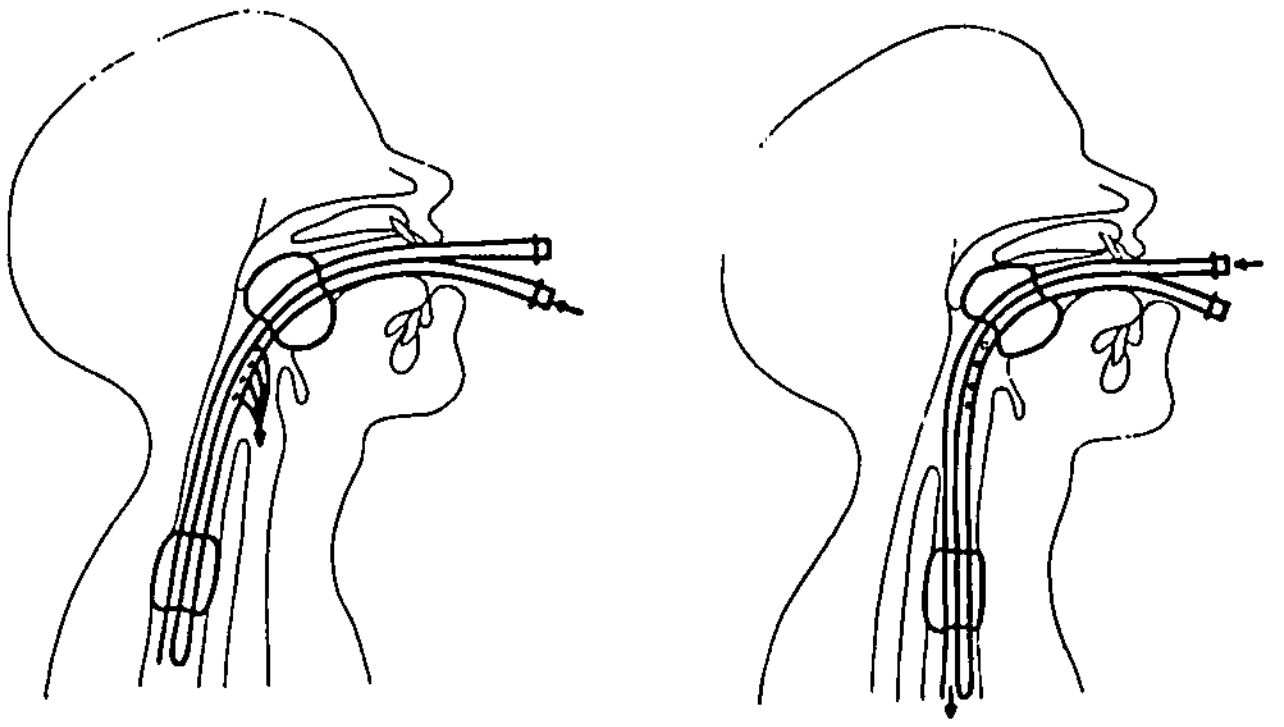

FIG. 10. *Left:* The esophageal tracheal combitube in the esophageal obturator position. Air enters the lungs through the holes in the esophageal lumen. *Right:* Esophageal tracheal combitube in the endotracheal position. Air enters the trachea directly through the tracheal lumen. Reproduced with permission from Frass *et al.*[97]

(most likely) the patient can be ventilated *via* the esophageal lumen perforations, and if the ETC enters the trachea, the patient can be ventilated directly *via* the tracheal lumen. In contrast, if the EOA enters the trachea, ventilation is not possible, and extubation of an EOA from a tracheal position leaves the airway unprotected. The reader is referred to the reports by Frass *et al.* for further details ETC use.[94–98]

The ETC allows for adequate ventilation while preventing aspiration of gastric contents. In all patients in whom it has been tried, ventilation *via* the ETC has been shown to be adequate when compared to endotracheal intubation during cardiopulmonary resuscitation,[94,95] during surgery,[94–96] and in the intensive care unit.[97] In the esophageal position, the unused tracheal lumen can be connected to a suction device to aspirate gastric fluids (aspiration of gastric fluids is not possible with the EOA). In most reports, the ETC has been inserted and adequate ventilation begun within 15–30 s. However, disadvantages of the ETC are the impossibility of suctioning the lungs when the ETC is in the esophageal position and, at present, the unavailability of pediatric sizes.

Recently, the ETC has been used in emergencies to adequately ventilate the lungs of a few patients who were in severe respiratory failure, whose lungs could not be adequately ventilated *via* mask, and whose trachea could not be intubated during surgery[98] and/or intensive care.[97,98] In addition, the ETC may prove valuable in the prehospital care of critically ill patients, and it may prove especially valuable in the management of patients with limited cervical spine movement.

2. *The Laryngeal Mask Airway*

The LMA (Intavent, Ltd., Berkshire, England) is a new device that is intermediate in design and function between a mask/oropharyngeal airway and an ETT. A 12-mm-ID tube connects to an oval mask that has an open center and an inflatable rim. After the patient is adequately anesthetized, the head is put into the sniff position, and the mask is completely deflated and lubricated and then inserted into the mouth with the aperture of the mask facing the tongue and the back of the mask against the roof of the mouth. The LMA is blindly pushed in with one smooth movement until resistance is felt, which usually means the tip of the mask is in the esophagus, and a black line on the tube shaft is opposite the upper lip. The cuff rim of the mask is now inflated and usually provides a good seal around the larynx. The tube part of the LMA is connected to the breathing circuit, and tidal gas goes in and out of the lungs through the tube shaft and the opening in the center of the mask. The LMA is available in four sizes that cover all ranges of patient age and size.

The LMA was first developed as a device to provide an airway for anesthesia.[99–104] Indeed, the LMA may be of particular benefit in permitting light general anesthesia through a relatively nonstimulating airway[105] to pediatric patients undergoing radiotherapy,[106] which is a situation where access to the child's head may be very restricted and where it may be necessary to leave the radiology room. However, since the LMA can be inserted quickly and blindly and works well in approximately 90% of cases, the most important use may be that of an alternative airway in the patient whose trachea cannot be intubated with an endotracheal tube.[107–112]

Although the LMA works well most of the time, there are several major limitations to the use of the airway. First, ventilation may be poor because the inflatable cuff does not seal the larynx and causes an unacceptably large air leak, or because the tongue has been pushed back over the larynx, or because the epiglottis has been pushed or flipped back over the laryngeal aperture.[102–104,113] Second, if the LMA is inserted or removed during inadequate anesthesia, laryngospasm may occur.[104,114,115] Third, since the inflatable rim of the LMA can never guarantee an air-tight seal around the larynx and the inflatable rim may actually seal both the esophagus and larynx together within the opening in the mask,[113] aspiration is always a possibility.[116–118] However, since the LMA has a reasonably low risk/benefit ratio and can be instituted easily, rapidly and blindly, it may be a reasonable airway to try one time prior to TTJV (fig. 3), with the provision that it may have a 10% failure rate and will not protect against aspiration. The LMA received Food and Drug Administration approval in August, 1991.

3. *Transtracheal Jet Ventilation*

Percutaneous TTJV using a large-bore intravenous catheter inserted through the cricothyroid membrane is a simple, relatively safe, extremely effective treatment of choice for the desperate situation in which the patient cannot be intubated or ventilated by mask.[2] Performing a very hurried surgical cricothyroidotomy and tracheotomy under these very suboptimal conditions is questionable and may be dangerous[89,90,119,120]; the patient may not be well positioned, the right instruments may not be immediately available, the anatomy may not be normal, and it may simply take too long.[16] Provided that an appropriate, high-pressure (50 psi) oxygen source and connections are immediately available, establishment of percutaneous TTJV is much quicker, simpler, and safer. TTJV and the appropriate high-pressure oxygen source and connections should be immediately available at every anesthetizing location.[2] New and easy-to-assemble systems for delivering emergency TTJV have been described.[121,122]

E. TRACHEAL EXTUBATION OF A PATIENT WITH A DIFFICULT AIRWAY

If tracheal extubation of a patient with a known difficult airway is followed by respiratory distress, then reintubation and ventilation may be difficult or impossible. Thus, the ideal method of extubation is one that permits a withdrawal from the airway that is controlled, gradual, step-by-step, and reversible at any time. Extubation over a jet stylet closely approximates this ideal.

1. *The Jet Stylet*

Recently the concept and use of a jet stylet during extubation of patients in whom subsequent ventilation and/or reintubation may be difficult has been described.[2,123] A jet stylet is a small-ID, hollow, semirigid catheter that is inserted into an *in situ* ETT prior to extubation. After the ETT is withdrawn over the jet stylet, the small-ID hollow catheter may then be used as a means of ventilation (*i.e.*, the jet function) and/or as an intratracheal guide for reintubation (*i.e.*, the stylet function) (fig. 11). The jet function may safely allow additional time to assess the need for the reintubation stylet function.

2. *Connection of the Jet Stylet to the Jet Ventilator*

A commercial tube exchanger makes an ideal jet stylet. The tube exchanger maybe connected to the jet injector in two ways; the reader is referred to the original articles for a detailed description[2,124,m] and to the next section (II.E.3) for a brief description of these connections. One method requires less preuse preparation, and the other method is easier to use if it is prepared beforehand.

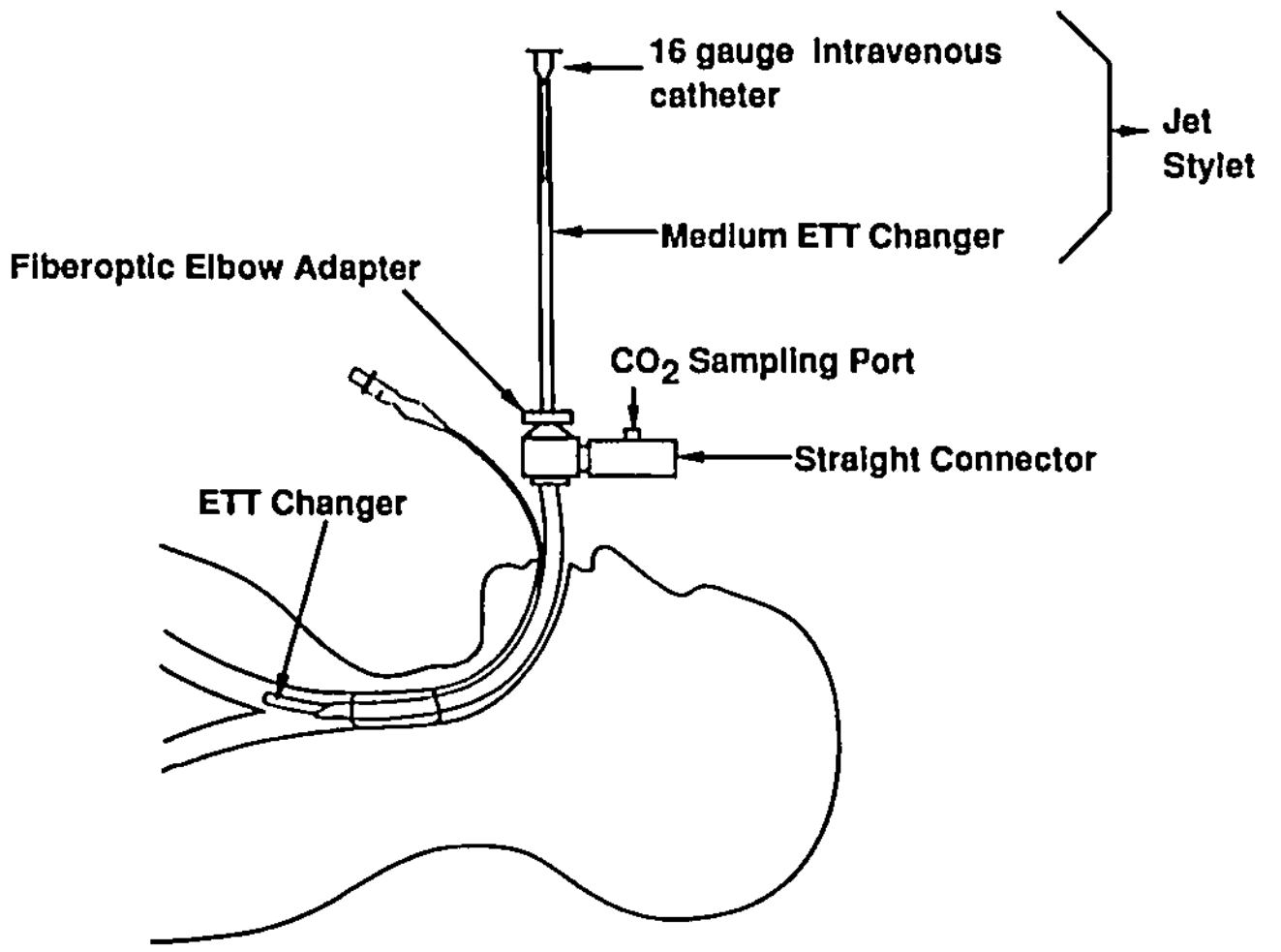

FIG. 11. A method to preserve the intratracheal location of the tracheal tube exchanger during confirmation of intratracheal placement of a tracheal tube. The tracheal tube exchanger is passed through a self-sealing diaphragm in a fiberoptic elbow adapter. With this method, positive pressure ventilation and carbon dioxide sampling may be around the tracheal tube exchanger but within the tracheal tube. ETT = endotracheal tube.

3. *Gas Flows Through the Various Jet Stylet Connection Systems*

The absolute flow rates ($\dot{V}$) and tidal volumes (TV) have been measured through the various jet stylet connection systems referenced above.[125] In table 4, system A is 14-, 16-, and 18-G intravenous catheters alone (reference system); system B is wedging 14-, 16-, and 18-G intravenous catheters into large, medium, or small Sheridan tube exchangers, respectively; and system C is inserting a female Luer-lock barbed cone adapter into the proximal ends of 4.0-cm lengths of 5.0-, 4.0-, and 3.0-ID ETTs. The distal ends of the ETTs fit snugly over large, medium, and small Sheridan tube exchangers, respectively. Table 4 shows that with wall-pressure oxygen (approximately 50 psi), the $\dot{V}$ and the one second TV through system A and system B were not significantly different. However, there was a 31, 47, and 14% increase for the large, medium and small tube exchangers, respectively, in the $\dot{V}$, TV, and minute ventilation ($\dot{V}_E$) with System C compared to System B. The smallest $\dot{V}_E$ for any of the test systems was 13.2 l/min (system B, smallest size), and the largest $\dot{V}_E$ was 50.4 l/min (system C, largest size). However, these absolute $\dot{V}$, TV, $\dot{V}_E$ generated by wall pressure must be interpreted with caution, for three reasons: first, the data was generated without respiratory impedance (increased resistance and decreased compliance); second, the data must be interpreted according to whether the goal of jet stylet ventilation is total or partial ventilatory support; and third, the oxygen pressure re-

TABLE 4. Jet Stylet Connection Systems and the Flow, 1-s Tidal Volume, and Minute Ventilation at a Respiratory Rate of 30 breaths per min through the Various Systems

Test System (Letter Code*)	Test System			Flow (l/min)	TV (ml)	$\dot{V}_E$ (l/min)	Test System		Flow (l/min)	TV (ml)	$\dot{V}_E$ (l/min)	Test System		Flow (l/min)	TV (ml)	$\dot{V}_E$ (l/min)
	Letter Code*	Intravenous Gauge	Tube Exchanger				Intravenous Gauge	Tube Exchanger				Intravenous Gauge	Tube Exchanger			
*A. 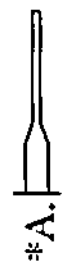 Intravenous catheter only	*A	14		67	1280	38.4	16		36	760	22.8	18		22	480	14.4
*B. 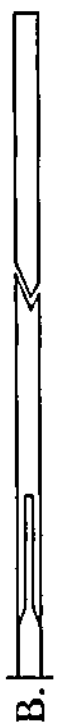 Intravenous catheter inside tube exchanger	*B	14	Large	67	1280	38.4	16	Medium	36	760	22.8	18	Small	20	440	13.2
*C. 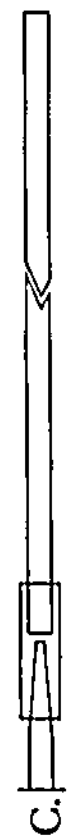 Female luer cone adapter connected to tube exchanger with a section of endotracheal tube	*C		Large	89	1680	50.4		Medium	58	1120	33.6		Small	26	500	15.0

TV = tidal volume; $\dot{V}_E$ = minute ventilation.

leased by the flush valve of modern anesthesia machines, when used for jet ventilation through a stylet, may not be as great as wall pressure.

4. *Jet Stylet Extubation Technique*

a. GENERAL ROUTINE MEASURES: First, several general routine measures (to be performed for any extubation) should be used. All relevant catheters and orifices (mouth, pharynx, nose, ETT, and nasogastric tube) should be suctioned. The patient should breath 100% oxygen for 2–5 min (preoxygenation). Just prior to extubation, the patient should be given a large sustained inflation, and while the lung is near total capacity, the ETT cuff should be deflated and the ETT pulled simultaneously. This sequence forces the very first event postextubation to be a forceful cough; *i.e.*, the forceful elastic recoil of the lung from total lung capacity generates a high expiratory $\dot{V}$. The cough clears the airway and vocal cords of secretions and should reduce the incidence of postextubation laryngospasm and breath holding. The total–lung-capacity breath can be given through a bronchoscopy elbow even if a jet stylet is in place (see section II.E.4.b and fig. 11).

b. PRESERVING THE INTRATRACHEAL LOCATION OF THE JET STYLET WHILE DETERMINING THE LOCATION OF THE REINTUBATION TRACHEAL TUBE: It has previously been believed that when using the reintubation stylet function of the jet stylet (if necessary), the jet stylet would have to be removed after the new tracheal tube has been inserted over the jet stylet, in order to allow connection of the new tracheal tube to the breathing circuit and confirmation of intratracheal placement of the tracheal tube (by capnography, breath sounds, *etc.*). However, removal of the jet stylet to confirm proper tracheal tube placement results in the loss of future use of both the jet and stylet functions. Thus, a method for preserving the intratracheal location of the jet stylet while concurrently confirming intratracheal placement of the reintubation tracheal tube is highly desirable.[126,127]

A standard anesthesia circle system is modified by replacing the existing elbow connector with a connector incorporating a self-sealing diaphragm such as the type used for bronchoscopy. In addition, the connection of the proximal end of the lumen of an appropriately sized tracheal tube exchanger to a jet ventilator is made immediately available as described above. When the new tracheal tube is passed over the tracheal tube changer, the new tracheal tube is connected to the anesthesia circuit *via* the bronchoscopy elbow by passing the proximal end of the tracheal tube changer retrograde through the self-sealing diaphragm of the bronchoscopy elbow connector (fig. 11). After conclusively establishing the intratracheal position and patency of the new tracheal tube by capnography and auscultation of bilateral breath sounds, the tracheal tube exchanger is removed by pulling it through the self-sealing diaphragm of the bronchoscopy elbow connector.

5. *Use of a Fiberoptic Bronchoscope as a Jet Stylet*

A FOB may be used as a jet stylet.[n] After the patient is extubated (by withdrawing the ETT to the proximal end of the FOB), the FOB allows for jet ventilation (*via* the suction port), serves as a reintubation stylet, and has the additional advantages of allowing for airway suctioning, continuous insufflation of oxygen, and visualization of the entire airway during withdrawal of the FOB. This extubation method should be particularly useful in patients in whom access to the upper airway is very limited (*e.g.*, patients in halo traction) and in whom the risk of airway edema is increased (*e.g.*, patients who have undergone an anterior approach to repair a cervical fracture).

III. Summary

Difficulty in managing the airway is the single most important cause of major anesthesia-related morbidity and mortality. Successful management of a difficult airway begins with recognizing the potential problem. All patients should be examined for their ability to open their mouth widely and for the structures visible upon mouth opening, the size of the mandibular space, and ability to assume the sniff position. If there is a good possibility that intubation and/or ventilation by mask will be difficult, then the airway should be secured while the patient is still awake. In order for an awake intubation to be successful, it is absolutely essential that the patient be properly prepared; otherwise, the anesthesiologist will simply fulfill a self-defeating prophecy. Once the patient is properly prepared, it is likely that any one of a number of intubation techniques will be successful. If the patient is already anesthetized and/or paralyzed and intubation is found to be difficult, many repeated attempts at intubation should be avoided because progressive development of laryngeal edema and hemorrhage will develop and the ability to ventilate the lungs *via* mask consequently may be lost. After several attempts at intubation, it may be best to awaken the patient, do a semielective tracheostomy, or proceed with the case using mask ventilation. In the event that the ability to ventilate *via* mask is lost and the patient's lungs still cannot be ventilated, TTJV should be instituted immediately. Tracheal extubation of a patient with a difficult airway over a jet stylet permits a controlled, gradual, and reversible (in that ventilation and reintubation is possible at any time) withdrawal from the airway.

Significant advances in the management of the difficult airway have occurred in recent years. Eighty percent of the 127 references in this article were published after 1985. However, there is much more to learn with regard to recognition of the difficult airway, preparation of the patient for an awake intubation, new techniques of endotracheal intubation, and establishment of gas exchange in patients who cannot be intubated or ventilated by mask. As the anesthesiologist's ability to manage the difficult airway significantly improves, respiratory-related morbidity and mortality will decrease.

The author gratefully acknowledges the editorial assistance of J. F. Biebuyck, M.B., D.Phil.; L. J. Saidman, M.D.; and S. D. Gaughan, M.D.; and the typing assistance of Ms. R. Reece.

References

1. Caplan RA, Posner KL, Ward RJ, Cheney FW: Adverse respiratory events in anesthesia: A closed claims analysis. ANESTHESIOLOGY 72:828–833, 1990
2. Benumof JL, Scheller MS: The importance of transtracheal jet ventilation in the management of the difficult airway. ANESTHESIOLOGY 71:769–778, 1989
3. Bellhouse CP, Doré C: Criteria for estimating likelihood of difficulty of endotracheal intubation with Macintosh laryngoscope. Anaes Intensive Care 16:329–337, 1988
4. Samsoon GLT, Young JRB: Difficult tracheal intubation: A retrospective study. Anaesthesia 42:487–490, 1987
5. Cormack RS, Lehane J: Difficult tracheal intubation in obstetrics. Anaesthesia 39:1105–1111, 1984
6. Aro L, Takki S, Aromaa U: Technique for Difficult Intubation. Br J Anaesth: 43:1081–1083, 1971
7. Mallampati SR, Gatt SP, Gugino LD, Desai SP, Waraksa B, Freiberger D, Liu PL: A clinical sign to predict difficult tracheal intubation: A prospective study. Can J Anaesth 32:429–434, 1985
8. Phillips OC, Duerksen RL: Endotracheal intubation: A new blade for direct laryngoscopy. Anesth and Analg 52:691–698, 1973
9. Finucane BT, Santora AH: Difficult intubation, Principles of Airway Management. Philadelphia, Davis Co, 1988, p 147
10. Deller A, Schreiber MN, Gromer J, Ahnefeld FW: Difficult intubation: Incidence and predictability: A prospective study of 8,284 adult patients (abstract). ANESTHESIOLOGY 73:A1054, 1990
11. Bellhouse CP: An angulated laryngoscope for routine and difficult tracheal intubation. ANESTHESIOLOGY 69:126–129, 1988
12. Lyons G: Failed intubation. Anaesthesia 40:759–762, 1985
13. Lyons G, MacDonald R: Difficult intubation in obstetrics (letter). Anaesthesia 40:1016, 1985
14. Glassenburg R, Vaisrub N, Albright G: The incidence of failed intubation in obstetrics: Is there an irreducible minimum? (abstract). ANESTHESIOLOGY 73:A1061, 1990
15. Tunstall ME: Failed intubation in the parturient (editorial). Can J Anaesth 36:611–613, 1989
16. King TA, Adams AP: Failed tracheal intubation. Br J Anaesth 65:400–414, 1990
17. Finucane BT, Santora AH: Evaluation of the airway prior to intubation, Principles of Airway Management. Philadelphia, FA Norris Co., 1988, pp 69–83
18. Sia RL, Eden ET: How to avoid problems when using the fiberoptic bronchoscope for difficult intubations (letter). Anaesthesia 36:74–75, 1988
19. Latto IP, Rosen M: Management of difficult intubation, Difficulties in Tracheal Intubation. London, Bailliere Tindall, 1985, pp 99–141
20. McIntyre JRW: The difficult intubation. Can J Anaesth 34:204–213, 1987
21. Latto IP, Rosen M: Intubation procedures and causes of difficult intubation, Difficulties in Tracheal Intubation. London, Bailliere Tindall, 1985, pp 76–89

22. Steward DJ: Anesthetic implications of syndromes and unusual disorders (appendix I), Manual of Pediatric Anesthesia. 2nd edition. New York, Churchill Livingstone, 1985, pp 289–343
23. Jones AEP, Pelton DA: An index of syndromes and their anesthetic implications. Can Anaesth Soc J 23:207–226, 1976
24. Cohen SM, Zaurito CE, Segil LJ: Oral exam to predict difficult intubations: A large prospective study (abstract). ANESTHESIOLOGY 71:A937, 1989
25. Mathew M, Hanna LS, Aldrete JA: Preoperative indices to anticipate a difficult tracheal intubation. Anaesth Analg 68:S187, 1989
26. Wilson ME, John R: Problems with the Mallampati sign. Anaesthesia 45:486–487, 1990
27. Charters P, Perera S, Horton WA: Visibility of pharyngeal structures as a predictor of difficult intubation (letter). Anaesthesia 42:1115, 1987
28. Horton WA, Fahy L, Charters P: Defining a standard intubation position using "angle finder." Br J Anaesth 62:6–12, 1989
29. McGill IW: Technique in endotracheal anaesthesia. Br Med J 2: 817–820, 1930
30. Salem MR, Methrubhutham M, Bennett EJ: Difficult intubation. N Engl J Med 295:879–881, 1976
31. Brechner VL: Unusual problems in the management of airways: I. Flexion-extension mobility of the cervical spine. Anesth Analg 47:362–373, 1968
32. White A, Kander PL: Anatomical factors in difficult direct laryngoscopy. Br J Anaesth 47:488, 1975
33. Nichol HL, Zuck B: Difficult laryngoscopy: The "anterior" larynx and the atlanto-occipital gap. Br J Anaesth 55:141–144, 1983
34. Roberts JT, Ali HH, Shorten GD, Gorback MS: Why cervical flexion facilitates laryngoscopy with a Macintosh laryngoscope but hinders it with a flexible fiberscope (abstract). ANESTHESIOLOGY 73:A1012, 1990
35. Patil VU, Stehling LC, Zauder HL: Techniques of endotracheal intubation, Fiberoptic Endoscopy in Anaesthesia. Chicago, Year Book Medical Publishers, Inc., 1983, pp 79
36. Cass NM, James NR, Lines V: Difficult direct laryngoscopy complicating intubation for anaesthesia Br J Med 1:488–489, 1956
37. Van der Linde JC, Revelopa JA, Steenkamp ED: Anatomical factors relating to difficult intubation. S Afr Med J 63:976–977, 1983
38. Sivarajan M, Fink RB: The position and the state of the larynx during general anesthesia and muscle paralysis. ANESTHESIOLOGY 72:439–442, 1990
39. Fink RB: Respiration, The Human Larynx: A Functional Study. New York, Raven Press, 1975, pp 56–84
40. Rogers S, Benumof JL: New and easy fiberoptic endoscopy-aided tracheal intubation. ANESTHESIOLOGY 59:569–572, 1983
41. McLellan J, Gordon P, Khawaja S, Thomas A: Percutaneous transtracheal high frequency jet ventilation as an aid to difficult intubation. Can J Anaesth 35:404–405, 1988
42. Baraka A: Transtracheal jet ventilation during fiberoptic intubation under general anesthesia. Anesth Analg 65:1091–1092, 1986
43. Barton S, Williams JD: Glossopharyngeal nerve block. Arch Otolaryngol 93:186–188, 1971
44. Cooper M, Watson RL: An improved regional anesthetic technique for perioral endoscopy. ANESTHESIOLOGY 42:273–374, 1975
45. Gotta AW, Sullivan KCA: Anaesthesia of the upper airway using topical anaesthetic and superior laryngeal nerve block. Br J Anaesth 53:1055–1057, 1983
46. Kopriva CJ, Eltringham RJ, Siebert PE: A comparison of the effects of innovar and topical spray on the laryngeal closure reflex. ANESTHESIOLOGY 40:596–598, 1974
47. Ovassapian A, Krejcie TC, Yelich SJ, Dykes MHM: Awake fiberoptic intubation in the patient at high risk of aspiration. Br J Anaesth 62:13–16, 1989
48. Williams RT, Maltby JR: Airway intubator (letter). Anesth Analg 61:309, 1982
49. Cahen CR: An aid in cases of difficult tracheal intubation (letter). ANESTHESIOLOGY 74:197, 1991
50. Dogra S, Falconer R, Latto IP: Successful difficult intubation: Tracheal tube placement over a gum-elastic bougie. Anaesthesia 45:774–776, 1990
51. Schwartz KD, Johnson C, Roberts J: A maneuver to facilitate flexible fiberoptic intubation. ANESTHESIOLOGY 71:470–471, 1989
52. Ovassapian A: Fiberoptic Airway Endoscopy in Anesthesia and Critical Care. New York, Raven Press, 1990
53. Nichols KP, Zornow MH: A potential complication of fiberoptic intubation. ANESTHESIOLOGY 70:562–563, 1989
54. Berman RA: A method for blind oral intubation of the trachea or the esophagus. Anesth Analg 56:866–867, 1977
55. Patil V, Stehling LC, Zauder HL, Koch JP: Mechanical aids for fiberoptic endoscopy. ANESTHESIOLOGY 57:69–70, 1982
56. Ovassapian A, Dykes MHM: The role of fiberoptic endoscopy for airway management. Semin Anesth 6:93–104, 1987
57. Moorthy SS, Dierdorf SF: An unusual difficulty in fiberoptic intubation (letter). ANESTHESIOLOGY 63:229, 1985
58. Waters DJ: Guided blind endotracheal intubation. Anaesthesia 18:159, 1963
59. Butler FS, Circillo AA: Retrograde tracheal intubation. Anesth Analg 39:333, 1960
60. Powell WF, Ozdil T: A translaryngeal guide for tracheal intubation. Anesth Analg 46:231–234, 1967
61. Akinyemi OO: Complications of guided blind endotracheal intubation. Anaesthesia 34:590–592, 1979
62. Barriot P, Riou B: Retrograde technique for tracheal intubation in trauma patients. Crit Care Med 16:712–713, 1988
63. Bourke B, Levesque PR: Modification of retrograde guide for endotracheal intubation. Anesth Analg 53:1013–1014, 1974
64. Tobias R: Increased success with retrograde guide for endotracheal intubation. Anesth Analg 62:366–371, 1983
65. King H-K, Wang L-F, Khan AK, Wooten OJ: Translaryngeal guided intubation for difficult intubation. Crit Care Med 15: 869–871, 1987
66. Hines MH, Meredith JW: Modified retrograde intubation technique for rapid airway access. Am J Surg 159:597–599, 1990
67. Freund PA, Rooke A, Schwid H: Retrograde intubation with a modified Eschman stylet. Anesth Analg 67:605–606, 1988
68. Carlson CA, Perkins HM, Veltkamp PS: Solving a difficult intubation (letter). ANESTHESIOLOGY 64:537, 1986
69. Lechman MJ, Donahoo JS, Macvaugh H: Endotracheal intubation using percutaneous retrograde guidewire insertion followed by antegrade fiberoptic bronchoscopy. Crit Care Med 14:589–590, 1986
70. Gupta B, McDonald JS, Brooks JHJ, Mendenhall J: Oral fiberoptic intubation over a retrograde guidewire. Anesth Analg 68:517–519, 1989
71. McIntyre JWR: Laryngoscope design and the difficult adult tracheal intubation. Can J Anaesth 36:94–98, 1989
72. Dorsch JA, Dorsch SE: Laryngoscopes, Understanding Anesthesia Equipment. 2nd edition. Baltimore, Williams and Wilkins 1984, pp 338–352
73. Choi JJ: A new double-angled blade for direct laryngoscopy (letter). ANESTHESIOLOGY 72:576, 1990
74. Saunders PA, Geisecke AH: Clinical assessment of the adult Bullard® laryngoscope. Can J Anaesth 36:S118–S119, 1989
75. Borland LM, Casselbrant M. The Bullard laryngoscope: A new

indirect oral laryngoscope (pediatric version). Anaesth Analg 70:105–108, 1990

76. Bainton CR: A new laryngoscope blade to overcome pharyngeal obstruction. ANESTHESIOLOGY 67:767–770, 1987
77. Diaz JH, Guarisco JL, LeJeune FE: A modified tubular pharyngolaryngoscope for difficult pediatric laryngoscopy. ANESTHESIOLOGY 73:357–358, 1990
78. Khan AK: A controllable suctioning laryngoscope (letter). Anesth Analg 71:200, 1990
79. Stewart RD, LaRosee A, Stoy WA, Heller MB: Use of a lighted stylet to confirm correct endotracheal tube placement. Chest 92:900–903, 1987
80. Stewart RD, Ellis DG: Lighted stylet and endotracheal intubation (letter). ANESTHESIOLOGY 66:851, 1987
81. Mehta S: Transtracheal illumination for optimal tracheal tube placement: A clinical study. Anaesthesia 44:970–971, 1989
82. Williams RT, Stewart RD: Transillumination of the trachea with a lighted stylet. Anesth Analg 65:542–543, 1986
83. Ellis DG, Jakymec A, Kaplan RM, Stewart RD, Freeman JA, Bleyaert A, Berkebile PE: Guided orotracheal intubation in the operating room using a lighted stylet: A comparison with direct laryngoscopic technique. ANESTHESIOLOGY 64:823–826, 1986
84. Holzman RS, Nargozian CD, Florence FB: Lightwand intubation in children with abnormal upper airways. ANESTHESIOLOGY 69:784–787, 1988
85. Culling RD, Mongan P, Castro T: Lightwand guided rapid sequence orotracheal intubation (abstract). ANESTHESIOLOGY 71: A994, 1989
86. Robelen GT, Shulman MS: Use of the lighted stylet for difficult intubations in adult patients (abstract). ANESTHESIOLOGY 71: A439, 1989
87. Fox DJ, Castro T, Rastrelli AJ: Comparison of intubation techniques in the awake patient: The Flexi-lum® Surgical Light (Lightwand) *versus* blind nasal approach. ANESTHESIOLOGY 66: 69–71, 1987
88. Heindel DJ: Deep neck abscesses in adults: Management of a difficult airway. Anesth Analg 66:774–776, 1987
89. Griggs WM, Worthley LIG, Gilligan JE, Thomas PD, Myburg JA: A simple percutaneous tracheostomy technique. Surg Gynecol Obstet 170:543–545, 1990
90. Silk JM, Marsh AM: Pneumothorax caused by minitracheotomy. Anaesthesia 44:663–664, 1989
91. Coe PA, King TA, Towey RM: Teaching guided fiberoptic nasotracheal intubation. Anaesthesia 43:410–413, 1988
92. Teller LE, Alexander CM, Frumin MJ, Gross JB: Pharyngeal insufflation of oxygen prevents arterial desaturation during apnea. ANESTHESIOLOGY 69:980–982, 1982
93. Patil V, Stehling LC, Zauder HL, Koch JP: Mechanical aids for a fiberoptic endoscopy. ANESTHESIOLOGY 57:69–70, 1982
94. Frass M, Frenzer R, Rauscha F, Weber H, Pacher R, Leithner C: Evaluation of esophageal tracheal combitube in cardiopulmonary resuscitation. Crit Care Med 15:609–611, 1987
95. Frass M, Frenzer R, Zdrahal F, Hoflehner G, Porges P, Lackner F: The esophageal tracheal combitube: Preliminary results with a new airway for cardiopulmonary resuscitation. Ann Emerg Med 16:768–772, 1987
96. Frass M, Rodler S, Frenzer R, Ilias W, Leithner C, Lackner F: Esophageal tracheal combitube, endotracheal airway and mask: Comparison of ventilatory pressure curves. J Trauma 29:1476–1479, 1989
97. Frass M, Frenzer R, Mayer G, Popovic R, Leithner C: Mechanical ventilation with the esophageal tracheal combitube (ETC) in the intensive care unit. Arch Emerg Med 4:219–225, 1987
98. Frass M, Frenzer R, Zahler J, Llias W, Leithner C: Ventilation via the esophageal tracheal combitube in a case of difficult intubation. J Cardiothorac Anesth 1:565–568, 1987
99. Brain AIJ: The laryngeal mask: A new concept in airway management. Br J Anaesth 55:801–805, 1983
100. Brain AIJ, McGhee TD, McAteer EJ, Thomas A, Abu-Saad MAW, Bushman JA: The laryngeal mask airway: Development and preliminary trials of a new type of airway. Anaesthesia 40: 356–361, 1985
101. Alexander CA, Leach AB, Thompson AR, Lister JB: Use your Brain! (letter). Anaesthesia 43:893–894, 1988
102. Brodrick PM, Webster RN, Nunn JF: The laryngeal mask airway. A study of 100 patients during spontaneous breathing. Anaesthesia 44:238–241, 1989
103. Maltby JR, Loken RG, Watson NC: The laryngeal mask airway: Clinical appraisal in 150 patients. Can J Anaesth 37:509–513, 1990
104. Mason DG, Bingham RM: The laryngeal mask airway in children. Anaesthesia 45:760–763, 1990
105. Hickey S, Cameron AE, Asbury AJ: Cardiovascular response to insertion of Brain's laryngeal mask. Anaesthesia 45:629–633, 1990
106. Grebenik CR, Ferguson C, White A: The laryngeal mask airway in pediatric radiotherapy. ANESTHESIOLOGY 72:474–477, 1990
107. Brain AIJ: Three cases of difficult intubation overcome by the laryngeal mask airway. Anaesthesia 40:353–355, 1985
108. Smith BL: Brain airway in anaesthesia for patients with juvenile chronic arthritis (letter). Anaesthesia 43:421–422, 1988
109. Chadwick IS, Vohra A: Anaesthesia for emergency caesarean section using the Brain laryngeal airway. Anaesthesia 44:261–262, 1989
110. Calder I, Ordman AJ, Jackowski A, Crockard HA: The Brain laryngeal mask airway: An alternative to emergency tracheal intubation. Anaesthesia 45:137–139, 1990
111. DeMello WF, Kocan M: The laryngeal mask in failed intubation. Anaesthesia 45:689–690, 1990
112. Ravalia A, Goddard JM: The laryngeal mask and difficult tracheal intubation (letter). Anaesthesia 45:168, 1990
113. Payne J: The use of the fiberoptic laryngoscope to confirm the position of the laryngeal mask (letter). Anaesthesia 44:865, 1989
114. Wilkinson M: The laryngeal mask: Cautionary tales (letter). Anaesthesia 45:167, 1990
115. Dasey N, Mansour N: Coughing and laryngospasm with the laryngeal mask (letter). Anaesthesia 44:865, 1989
116. Cyna AM, MacLeod DM: The laryngeal mask: Cautionary tales (letter). Anaesthesia 45:167, 1990
117. Campbell J: The laryngeal mask: Cautionary tales (letter). Anaesthesia 45:167–168, 1990
118. Criswell J, John R: The laryngeal mask: Cautionary tales (letter). Anaesthesia 45:168, 1990
119. Toye FJ, Weinstein JD: Clinical experience with percutaneous tracheostomy and cricothyroidotomy in 100 patients. J Trauma 26:1034–1040, 1988
120. Wain JC, Wilson DJ, Mathisen DJ: Clinical experience with minitracheostomy. Ann Thorac Surg 49:881–886, 1990
121. Meyer PD: Emergency transtracheal jet ventilation system. ANESTHESIOLOGY 723:787–788, 1990
122. Sprague DH: Transtracheal jet oxygenation from capnographic monitoring components (letter). ANESTHESIOLOGY 73:788, 1990
123. Bedger RC, Chang JL: A jet stylet catheter for difficult airway management. ANESTHESIOLOGY 66:221–223, 1987
124. Benumof JL, Gaughan S, Ozaki GT, Rusk R: Connecting a jet stylet to a jet ventilator (letter). ANESTHESIOLOGY 74:963–964, 1991
125. Gaughan S, Benumof JL, Ozaki GT: Quantification of the jet function of a jet stylet (abstract). ANESTHESIOLOGY, 75:A119. 1991

126. Goskowicz R, Gaughan S, Benumof JL, Ozaki GT: It is not necessary to remove a jet stylet in order to determine tracheal tube location. J Clin Anesth, in press

127. Benumof JL: Additional safety measures when changing endotracheal tubes (letter). ANESTHESIOLOGY 75:921, 1991

Footnotes

[a] American Society of Anesthesiologists Task Force, consisting of J. Benumof, M. Bishop, C. Blitt, R. Caplan, F. Cheney, T. Davidson, D. Gaba, and E. Pierce, met on November 2, 1990 in San Francisco for the purpose of developing a conceptual framework for the American Society of Anesthesiologists Patient Safety Program video tape 15, titled "The Difficult Airway: Part I. Algorithm."

[b] Hirsch IA, Reagan JO, Sullivan N: Complications of direct laryngoscopy: A prospective analysis. Anesthesiology Review 17:34–40, 1990

[c] American Society of Anesthesiologists Committee on Professional Liability. Personal communication, March 1990.

[d] Norton ML, Wilton H, Brown A: The difficult airway clinic. Anesthesiology Review 25:25–28, 1988

[e] Woods AM, Lander CI: Abolition of gagging and the hemodynamic response to awake laryngoscopy (abstract). ANESTHESIOLOGY 57:A220, 1987

[f] Williams RT: Personal communication.

[g] Sanchez A: Personal communication.

[h] Schmidt SI, Hasewinkel JV: Retrograde catheter-guided direct laryngoscopy. Anesthesiology Review 16:49–50, 1989.

[i] Kingston HGG: Airway problems in pediatric patients, Problems in Anesthesia. Edited by Kirby RR, Brown DL (editors in chief) and Bishop MJ (guest editor). Philadelphia, JB Lippincott Co., 2(4):545–565, 1988

[j] Kilgus R: Personal communication.

[k] Augustine S: Personal communication.

[l] Daitch JS: Lesson 42: Preanesthetic assessment: The patient with maxillofacial injury, Anesthesiology News. Edited by Frost E (section editor). New York, McMahon Inc., July, 1988, p 13

[m] Benumof JL: Management of the difficult or impossible airway. Annual ASA Refresher Course 1990, Lecture 163, p 7

[n] Wheeler S, Fontenot R, Gaughan S, Benumof JL: Use of fiberoptic bronchoscope as a jet stylet. Anesthesiology Review, in press