

## DISCUSSION

Although Shulman *et al.* have reported that sevoflurane triggers MH in MH-susceptible swine,<sup>4</sup> there has been no report of MH during sevoflurane anesthesia in humans. It has been shown that the release of myoglobin and creatine phosphokinase from the muscle cells during sevoflurane anesthesia is less than that during halothane anesthesia,<sup>5</sup> and in MH-susceptible pigs halothane provokes more severe MH than does sevoflurane.<sup>4,5</sup> Vecuronium, which was used in this patient, is not a triggering agent for MH in susceptible pigs,<sup>6</sup> and thiopental and pancuronium have been shown to delay the onset of MH.<sup>7</sup> We used no anesthetics considered to be triggering agents for MH except sevoflurane.

During the preoperative evaluation, our attention was drawn to the patient's congenital ptosis—a clinical sign, like scoliosis, that has been observed in MH susceptible patients. However, neither the family history nor the preoperative laboratory studies suggested MH susceptibility. Therefore, a diagnostic contracture test was not performed, and dantrolene was not administered prior to anesthesia and surgery.

This case report demonstrates both that sevoflurane can trigger MH in susceptible patients and also that MH

triggered by sevoflurane can be successfully treated with intravenous dantrolene.

The authors thank Dr. Naoya Minami, Department of Neurology, Hokkaido University Hospital, for performing the muscle biopsy.

## REFERENCES

1. Adreth A: Advances in the diagnosis and treatment of malignant hyperthermia. *Acta Anaesth Scand* 25:477-483, 1981
2. Endo M, Yagi S, Ishizuka T, Horiuti K, Koga Y, Amaha Y: Changes in the Ca-induced Ca release mechanism in the sarcoplasmic reticulum of the muscle from a patient with malignant hyperthermia. *Biomed Res* 4:83-92, 1983
3. Brownell AKW: Malignant hyperthermia: Relationship to other diseases. *Br J Anaesth* 60:303-308, 1988
4. Shulman M, Braverman B, Ivankovich AD, Gronert G: Sevoflurane triggers malignant hyperthermia in swine. *ANESTHESIOLOGY* 54:259-260, 1981
5. Noguchi I, Suzuki G, Hiyama A, Morisaki H, Miyazawa N, Miura K, Amemiya Y, Kawamura H: Effects of sevoflurane anesthesia on serum levels of myoglobin and CPK in anesthetized children: A comparison with halothane (abstract in English). *Masui Japanese Journal of Anesthesiology* 37:421-427, 1988
6. Buzello W, Williams CH, Chandra P, Watkins ML, Dozier SE: Vecuronium and porcine malignant hyperthermia. *Anesth Analg* 64:515-519, 1985
7. Gronert GA, Milde JH: Variations in onset of porcine malignant hyperthermia. *Anesth Analg* 60:499-503, 1981

Anesthesiology  
75:701-704, 1991

## Intraoperative Use of Transesophageal Echocardiography with Pulsed-wave Doppler Evaluation of Ventricular Filling Dynamics during Pericardiotomy

CHARLES W. HOGUE, JR., M.D.,\* MITCHELL PLATIN, M.D.,†  
BENICO BARZILAI, M.D.,‡ LARRY R. KAISER, M.D.§

Transthoracic echocardiography is the most frequently used method for the diagnosis of pericardial effusions. In addition to detecting the presence of pericardial fluid, M-mode and two-dimensional echocardiography can establish the presence of tamponade.<sup>1-5</sup> Previous investigators have examined transthoracic M-mode, two-dimensional,

and pulsed-wave Doppler echocardiography in nonanesthetized patients undergoing pericardiocentesis.<sup>4-6</sup> We report a case in which transesophageal echocardiography proved clinically useful during pericardiotomy in a patient receiving general anesthesia.

## CASE REPORT

A 59-yr-old man with a history of controlled essential hypertension presented with a recent history of a flu-like illness and a pericardial effusion. Two weeks before admission the patient had had an episode of paroxysmal atrial fibrillation associated with severe shortness of breath and fatigue. The patient was treated with metoprolol, digoxin, and quinidine with successful conversion of the atrial fibrillation to sinus rhythm. Diagnostic evaluation included a transthoracic echocardiogram that showed a large pericardial effusion without tamponade. Because of increasing shortness of breath at rest, a pericardiotomy (pericardial window) was scheduled. Preoperative examination revealed an arterial blood pressure of 118/60 mmHg and no pulsus paradoxus or jugular venous distention, and the electrocardiogram revealed sinus rhythm at a rate of 90 beats per min.

\* Instructor, Department of Anesthesiology.

† Resident, Department of Anesthesiology.

‡ Assistant Professor, Department of Cardiology.

§ Associate Professor, Department of Surgery.

Received from the Departments of Anesthesiology, Cardiology and Surgery, Washington University School of Medicine, 660 South Euclid Avenue, Box 8054, St. Louis, Missouri. Accepted for publication June 25, 1991.

Address reprint requests to Dr. Hogue: Department of Anesthesiology, Washington University School of Medicine, 660 South Euclid Avenue, St. Louis, Missouri 63110.

Key words: Measurement techniques: echocardiography. Monitoring: pericardial effusion. Surgery: pericardiotomy.

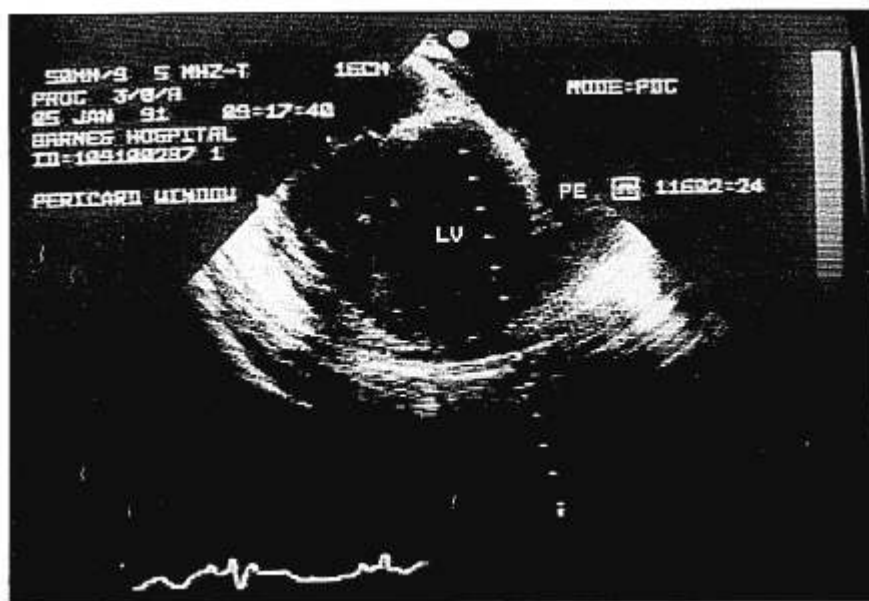


FIG. 1. Two-dimensional echocardiogram showing left ventricle (LV) and loculated pericardial effusion (PE).

After induction of anesthesia and tracheal intubation, a 5.0 MHz transesophageal echocardiographic probe was inserted and connected to a Hewlett-Packard 77020A ultrasound imaging system (Hewlett-Packard, Andover, MA). Multiple M-mode and two-dimensional echocardiographic images clearly demonstrated the pericardial effusion without signs of tamponade (*i.e.*, no atrial notching or right ventricular diastolic collapse). There was no echocardiographic evidence of left ventricular hypertrophy or regional wall motion abnormalities, and no mitral, aortic, or tricuspid regurgitation was apparent on color-flow Doppler examination. Pulsed-wave Doppler measurements of mitral and tricuspid blood-flow velocities were determined by placing the Doppler sample volume at the tips of the respective valve leaflets and orientating the Doppler beam parallel to the assumed pathway of ventricular blood inflow. Mechanical ventilation was continued during the Doppler measurement period. Pericardiotomy was performed with the initial drainage of 600 ml of bloody effusion.

At this point two-dimensional echocardiography revealed loculated fluid in the posterior-lateral pericardium that the surgeon had previously not detected (fig. 1). Further probing of the pericardial space by the surgeon yielded an additional 300 ml of fluid. After the drainage of the effusion the heart rate decreased to 80 beats per min, and the arterial blood pressure remained stable at 112/60 mmHg. Mitral and tricuspid pulsed-wave Doppler measurements were repeated, with the Doppler sample volume again placed at the tips of the respective valves.

No interventions that could alter ventricular filling were instituted between Doppler measurement periods; *i.e.*, the patient remained supine, and no fluid bolus or vasoconstrictor medication was administered. An M-mode echocardiographic image obtained from a cross section of the left ventricle at the mid-papillary level showed the left ventricular end-diastolic dimension to have increased from 1.5 to 2.5 cm with the drainage of the pericardial fluid. Emergence from anesthesia was uneventful, and the patient was transferred to the postanesthesia care unit awake and with stable vital signs.

Intraoperative echocardiographic images recorded on videotape were later analyzed with the Hewlett-Packard 77020A ultrasound imaging system. Pulsed-wave Doppler measurements made from the tricuspid and mitral valves included peak early filling velocity (E wave), peak atrial filling velocity (A wave), and the ratio of early to atrial peak velocity (E:A ratio), as well as early and atrial transvalvular velocity-time integrals. Five consecutive pulsed-wave Doppler samples were analyzed at each respective measurement period; the system was recalibrated between each analysis. One-way analysis of variance was used to compare the peak E wave, peak A wave, E:A ratio, and velocity-time integrals from both the tricuspid and mitral samples obtained before and after the pericardiotomy; *P* values < 0.05 were considered significant.

The blood-flow velocity results are shown in table 1. The peak E wave, A wave, E:A ratio, and peak E wave velocity-time integral of

TABLE 1. Comparison of Transvalvular Pulsed-wave Doppler Results Before and After Pericardiotomy

	E Wave (cm · s <sup>-1</sup> )	A Wave (cm · s <sup>-1</sup> )	E:A Ratio	TVI	
				E Wave (cm)	A Wave (cm)
Mitral					
Before	36.9 ± 1.3	44.6 ± 1.12	0.83 ± 0.32	4.43 ± 0.13	5.05 ± 0.24
After	67.5 ± 2.91*	60.4 ± 2.51*	1.12 ± 0.50*	9.76 ± 4.35*	5.76 ± 2.57
Tricuspid					
Before	55.0 ± 1.2	50.2 ± 2.39	1.12 ± 0.06	7.00 ± 0.21	4.33 ± 0.27
After	65.1 ± 1.02†	49.4 ± 4.69	1.36 ± 0.13	8.28 ± 0.35	4.16 ± 0.20

Values are mean ± SEM.

TVI = transvalvular time velocity integral.

\* *P* < 0.01 mitral valve before versus after pericardiotomy.

† *P* < 0.01 tricuspid before versus after pericardiotomy.

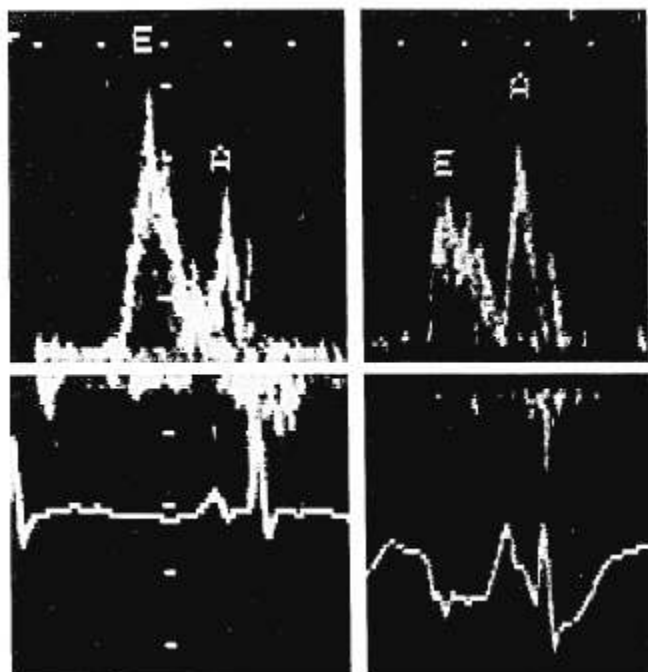


FIG 2. Representative transmitral Doppler recordings after drainage of pericardial fluid (left) compared to sample obtained prior to pericardiotomy (right). An increase in the height of the peak E wave compared to the A wave occurred immediately after pericardial effusion drainage.

the mitral valve blood-flow velocities increased after pericardiotomy compared with the values obtained before the pericardial fluid was drained. Representative transmitral Doppler samples obtained after drainage of the effusion compared to before pericardiotomy are shown in figure 2. Although the peak E wave blood-flow velocity of the tricuspid valve was different after the drainage of the pericardial effusion, the remaining transtricuspid blood flow velocities, including the E:A ratio, were no different after the pericardiotomy.

## DISCUSSION

Despite the absence of preoperative echocardiographic or clinical signs of pericardial tamponade in our patient, the intraoperative transvalvular blood-flow velocities (table 1) document a restriction to ventricular filling imposed by the large pericardial effusion. Pulsed-wave Doppler recordings across the atrioventricular valves are characterized by early and late diastolic components of flow. The peak early wave (E wave) represents peak blood-flow velocity occurring with passive, rapid ventricular filling, and the later peak (A wave) represents blood-flow velocity due to atrial contraction.<sup>7</sup> Comparison of the E wave to the A wave (E:A ratio) provides an estimate of the relative contribution of atrial contraction to ventricular filling; a normal E:A ratio is greater than 1.<sup>7</sup> Our data show (table 1) that in the presence of the pericardial effusion there was an increased contribution of atrial systole to left ven-

tricular diastole (E:A ratio  $0.83 \pm 0.32$ ) compared to immediately after effusion drainage (E:A ratio  $1.12 \pm 0.50$ ). In the absence of other interventions that could have influenced ventricular diastole,<sup>7</sup> the rapid reversal of the E:A ratio to the normal pattern with the pericardiotomy (fig. 2 and table 1) suggests that the abnormal left ventricular diastolic index before drainage can be attributed to the pericardial effusion.

The hemodynamic complications of pericardial effusion depend on a multitude of factors, including the rate of effusion formation in relation to pericardial compliance. When the pericardium reaches its limit of distensibility, further accumulation of fluid results in a marked increase in intrapericardial pressure that may exceed diastolic pressure of the heart chambers and result in atrial and ventricular compression. The increase in intrapericardial pressure in relation to intracavitary pressure is believed to produce the echocardiographic findings of diastolic collapse of the right atrium and ventricle seen with pericardial tamponade.<sup>2-5</sup> The compression of the atrium during pericardial tamponade may be particularly deleterious: it has been shown in an experimental model that the hemodynamic effects of pericardial tamponade are primarily the result of atrial compression and are not due to compression of either the right or left ventricle.<sup>8</sup>

As mentioned, our patient demonstrated an increased atrial contribution to diastole before pericardiotomy (fig. 2 and table 1) even in the absence of tamponade. The loss of an effective atrial contraction in the setting of this restriction to ventricular filling would be expected to significantly reduce stroke volume. Furthermore, a decrease in filling pressures, which may occur with venodilation or positive-pressure ventilation, could reduce atrial transmural pressure and limit cardiac output. We speculate that the increase in symptoms that our patient reported during the preoperative episode of atrial fibrillation may have resulted from the loss of the atrial systolic contribution to ventricular diastole.

Transesophageal echocardiography, therefore, seems to offer several unique diagnostic and monitoring capabilities for patients undergoing pericardiotomy under general anesthesia. First, as illustrated in this report (fig. 1), intraoperative transesophageal echocardiographic imaging may allow the identification of loculated pericardial fluid and thereby allow more complete effusion drainage. Second, because intrapericardial pressures are not routinely measured before pericardiotomy, traditional intravascular monitoring (*e.g.*, central venous, pulmonary arterial, and pulmonary occlusion pressures) may not detect imminent tamponade. Because atrial collapse as detected by echocardiography is sensitive in predicting cardiac tamponade,<sup>5</sup> the use of transesophageal echocardiography before pericardiotomy provides a method of visually evaluating the relationship between intrapericardial and in-

tracavitary pressures and may allow the detection of impending hemodynamic compromise.

## REFERENCES

1. Horowitz MS, Schultz CS, Stinson EB, Popp RL: Sensitivity and specificity of Echocardiographic diagnosis of pericardial effusion. *Circulation* 50:239-247, 1974
2. Martins JB, Kerber RE: Can cardiac tamponade be diagnosed by echocardiography? *Circulation* 60:737-742, 1979
3. Leimgruber PP, Klopfenstein HS, Wann LS, Brooks HL: The hemodynamic derangement associated with right ventricular diastolic collapse in cardiac tamponade: An experimental echocardiographic study. *Circulation* 68:612-620, 1983
4. Kronzon I, Cohen ML, Winer HE: Diastolic atrial compression: A sensitive echocardiographic sign of cardiac tamponade. *J Am Coll Cardiol* 2:770-775, 1983
5. Singh S, Wann S, Schuchard GH, Klopfenstein HS, Leimgruber PP, Keelan MH, Brooks HL: Right ventricular and right atrial collapse in patients with cardiac tamponade: A combined echocardiographic and hemodynamic study. *Circulation* 70:966-971, 1984
6. Appleton CP, Hatle LK, Popp RL: Cardiac tamponade and pericardial effusion: Respiratory variation in transvalvular flow velocities studied by Doppler echocardiography. *J Am Coll Cardiol* 11:1020-1030, 1988
7. Nishimura RA, Abel MD, Hatle LK, Tajik AJ: Assessment of diastolic function of the heart: background and current applications of Doppler echocardiography. *Mayo Clin Proc* 64:181-204, 1989
8. Fowler NO, Gabel M: The hemodynamic effects of cardiac tamponade: Mainly the result of atrial, not ventricular, compression. *Circulation* 71:154-157, 1985