

8. Evans DW, Stovin PG: Fatal heart block due to mesothelioma of the atrioventricular node. *Br Heart J* 56:572-574, 1986
9. Hess DC, Bache RJ: The transmural right ventricular myocardial blood flow during systole in the awake dog. *Circ Res* 45:88-94, 1979
10. Lowensohn HS, Khouri EM, Gregg DE, Pyle RL, Patterson RE: Phasic right coronary artery blood flow in conscious dogs with normal and elevated right ventricular pressures. *Circ Res* 39:760-766, 1976
11. Loeb JM, De Tarnowsky JM, Johnsen JA: Differential cholinergic sensitivity of sinus and AV nodes. *Eur J Pharmacol* 83:321-324, 1982
12. Royster RL, Keeler K, Haisty K, Johnston WE, Prough DS: Cardiac electrophysiologic effects of fentanyl and combinations of fentanyl and neuromuscular relaxants in pentobarbital-anesthetized dogs. *Anesth Analg* 67:15-20, 1988
13. Katona PG, Lipson D, Dauchot PJ: Opposing central and peripheral effects of atropine on parasympathetic cardiac control. *Am J Physiol* 232:H146-H151, 1977
14. Heinekamp WJR: The central influence of atropine and hyoscine on the heart rate. *J Lab Clin Med* 8:104-111, 1922
15. Gravenstein JS and Thornby JI: Scopolamine on heart rates in man. *Clin Pharmacol Ther* 10:395-400, 1969
16. Schmidt PJ, Ezri MD, Denes P: Cardiac arrhythmias: Update 1987. *Dis Mon* 33:365-432, 1987
17. Shah PK, Nalos P, Peter T: Atropine resistant post infarction complete AV block: Possible role of adenosine and improvement with aminophylline. *Am Heart J* 113:194-195, 1987

Anesthesiology  
75:370-374, 1991

## Epidural Analgesia in Patients with Congenital Lumbosacral Spinal Anomalies

MICHAEL G. COOPER, M.B., B.S., F.F.A.R.A.C.S.,\* NAVIL F. SETHNA, M.B., CH.B.†

Epidural anesthesia, other than that by the caudal route, is now an accepted and safe technique in pediatric regional anesthesia.<sup>1-4</sup> However, spinal deformity is regarded as a relative contraindication<sup>5,6</sup> to the safe placement and use of an epidural catheter. We reviewed the records of six cases of the use of lumbar epidural blockade in patients with congenital anomalies of the sacrum and lower lumbar spine.

### CASE REPORTS

**Case 1.** A girl aged 9 months and weighing 9 kg presented with complete sacral agenesis and partial sacralization of the fifth lumbar vertebra (see fig. 1). She presented for major perineal genitourinary reconstruction of a cloaca deformity. After induction of general anesthesia, a lumbar epidural catheter was inserted at L3-L4 via a 19-G Tuohy needle using loss of resistance to air to identify the epidural space. She received 2 ml 0.5% bupivacaine, which was repeated once during the 9-h operation. On awakening in recovery the patient experienced pain, which resolved with 1 ml 0.5% bupivacaine. Since there was limited facility for postoperative infusion via the epidural

route, the catheter was removed. However, analgesia lasted only 1 h, and an intravenous morphine infusion was commenced.

**Case 2.** A girl currently aged 3 yr and weighing 16 kg had been born with sacral teratoma, cloacal exstrophy, imperforate anus, duplex vagina, and bladder exstrophy. A mature teratoma was excised and sigmoid colostomy was performed on day 1 of life. The teratoma contained ribs articulating with the lower abnormal aspect of the sacrum, and at operation there appeared to be a double sacrum with a central membrane-lined cavity that did not contain cerebrospinal fluid. There remained a calcified remnant of sacrum and a marked diastasis of the pelvis. On this admission, she underwent major abdominopelvic surgery lasting 19 h that involved bilateral iliac osteotomies, splitting of the pubic symphysis, creation of a bladder from the stomach, reimplantation of ureters, creation of a urethra and bladder neck, and excision of the vaginal septum.

Postoperatively, after tracheal extubation, she required such large doses of opioid and sedation that respiratory depression occurred and tracheal intubation was necessary. In order to decrease analgesic requirement, which included ketamine 4 mg · kg<sup>-1</sup> · h<sup>-1</sup>, a catheter was inserted 3 cm into the epidural space at the L1-L2 interspace. This proved ineffective: there was no evidence of sympathetic or sensory blockade. The catheter was reinserted via the L2-L3 interspace. Four milliliters of lidocaine 1.5% with 1:200,000 epinephrine provided motor blockade, and an infusion of 0.125% bupivacaine with fentanyl 2 µg/ml was commenced at 7 ml/h. This provided effective analgesia and was subsequently maintained at 5 ml/h. All sedation ceased, and the trachea was extubated successfully. The infusion continued for 144 h.

**Case 3.** A girl aged 4 yr and weighing 13 kg had been born with a cloaca and a tracheoesophageal fistula. Esophageal repair, colostomy, vesicostomy, and vaginostomy were performed in the first days of life. The child developed chronic pulmonary disease secondary to recurrent aspiration despite two fundoplication procedures. She also developed asthma. The spinal anomaly consisted of hypoplasia of the lower lumbar vertebrae, partial sacral agenesis with a block fusion of L4-L5 causing kyphosis (see fig. 2). The patient underwent a 14-h major genitourinary reconstruction that included splitting of the pubic symphysis, adhesion lysis, creation of neourethra and perineal vaginoplasty, cloaca repair, and suprapubic cystostomy.

Epidural catheter placement was attempted at the end of the operation at L4-L5 and L3-L4 with a 17-G Tuohy needle. At both

\* Fellow, Pain Treatment Service.

† Assistant Professor in Anesthesia.

Received from the Department of Anesthesia, The Children's Hospital and Harvard Medical School, Boston, Massachusetts and the Department of Anaesthesia, The Children's Hospital, Camperdown, Sydney, Australia. Accepted for publication April 11, 1991. Supported in part by a research grant from Astra Pharmaceuticals Pty. Ltd., Australia (MGC).

Case 1 was performed at the Children's Hospital, Camperdown, Sydney and cases 2-6 at the Children's Hospital, Boston, Massachusetts.

Address reprint requests to Dr. Cooper: Department of Anaesthesia, The Children's Hospital, Camperdown, N.S.W. 2050, Australia.

Key words: Anatomy: spine. Anesthesia: pediatric. Anesthetic technique: epidural.

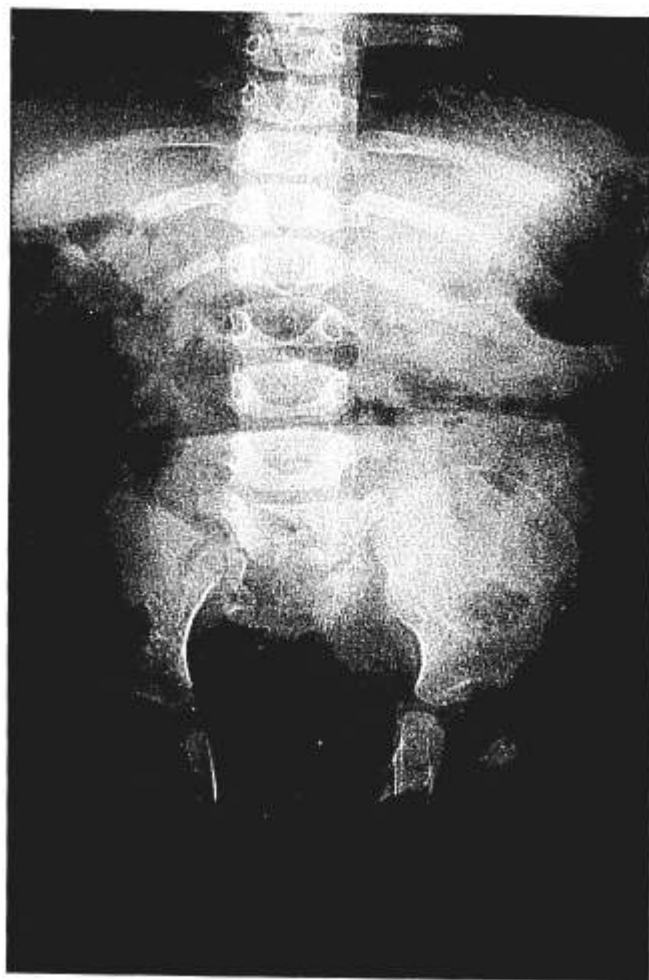

FIG. 1. X-ray of case 1, showing sacral agenesis with sacralization of fifth lumbar vertebra.

vertebral levels loss of resistance occurred with normal saline, but cerebrospinal fluid was obtained on attempted passage of the catheter, and the procedure was abandoned. At 36 h postoperatively, there was difficulty extubating the trachea because of extreme pain, which required  $0.1\text{--}0.2\text{ mg}\cdot\text{kg}^{-1}\cdot\text{h}^{-1}$  morphine and  $0.1\text{ mg}\cdot\text{kg}^{-1}\cdot\text{h}^{-1}$  midazolam and  $1\text{ }\mu\text{g/kg}$  fentanyl as required. Repeat epidural catheter placement was performed successfully at L2–L3 using a 19-G needle with 21-G catheter. An infusion of 0.1% bupivacaine with  $2\text{ }\mu\text{g/ml}$  fentanyl was commenced at  $3.9\text{ ml/h}$ . Satisfactory analgesia was provided by  $5.0\text{ ml/h}$ ; no further opioid or sedation was necessary; and the trachea was successfully extubated. The epidural infusion was continued for 96 h.

**Case 4.** This 7-yr-old girl weighed 24 kg and had undergone closure of an L4–L5 myelomeningocele at birth (fig. 3). A functioning ventriculoperitoneal shunt had been inserted 3 yr previously, and there were no symptoms of increased intracranial pressure. She had continent bladder and rectal sphincters but mild motor weakness in the lower extremities. She had a recurrently dislocating left hip, and underwent a 7-h procedure involving iliopsoas release, femoral osteotomy, muscle advancement, and pelvic Chiari osteotomy. This patient had experienced anaphylactic reactions under previous general anesthesia that was subsequently identified as a latex allergy. A 20-G epidural catheter was inserted *via* a 17-G Tuohy needle at the L2–L3 interspace, and

the epidural space was identified at 1.5 cm from the skin using a loss of resistance to air technique. Five milliliters 0.5% bupivacaine was instilled in the operating room, and an infusion of 0.125% bupivacaine with 1:200,000 epinephrine was commenced at  $3\text{ ml/h}$  in the recovery room. This subsequently was increased to  $4\text{ ml/h}$  with excellent effect and was continued for 44 h postoperatively.

**Case 5.** A 22-yr-old man weighing 58 kg had had an L5–sacral myelomeningocele repaired at birth. He had a neurogenic bladder but good lower limb function. He underwent a 15-h major bladder operation involving revision of ileocecal bladder augmentation, uretero-

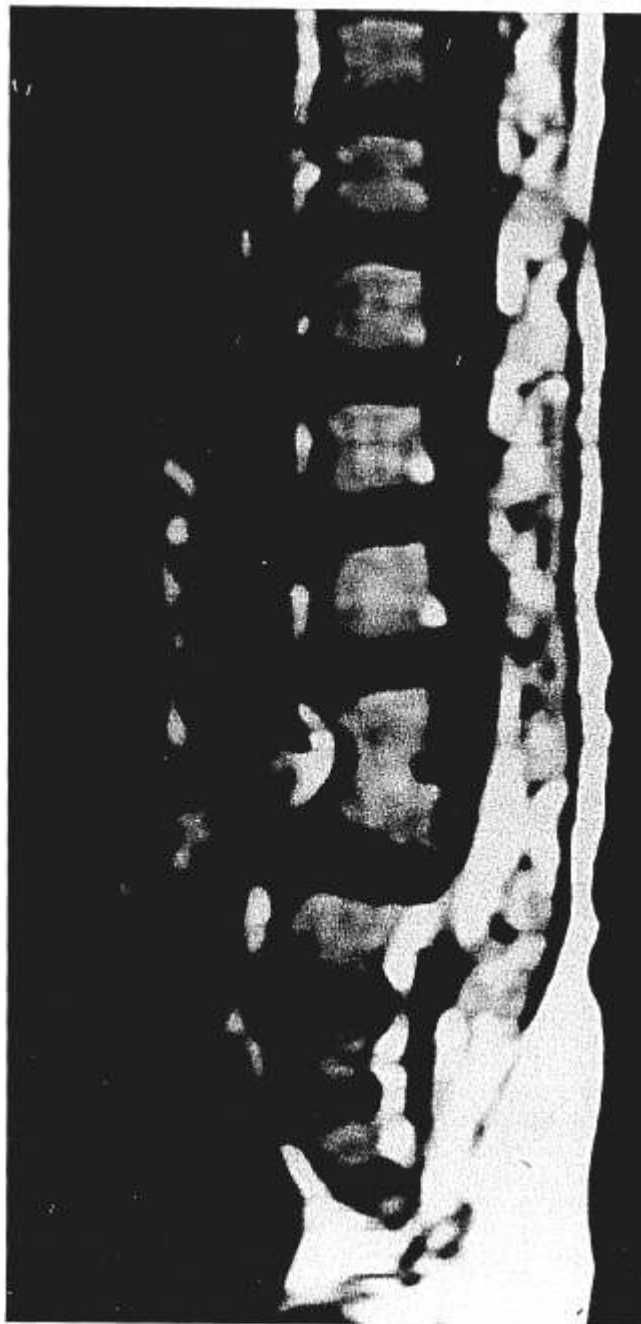


FIG. 2. MRI of case 3. Sagittal section showing L4–L5 block vertebrae with kyphosis and lower sacral agenesis.

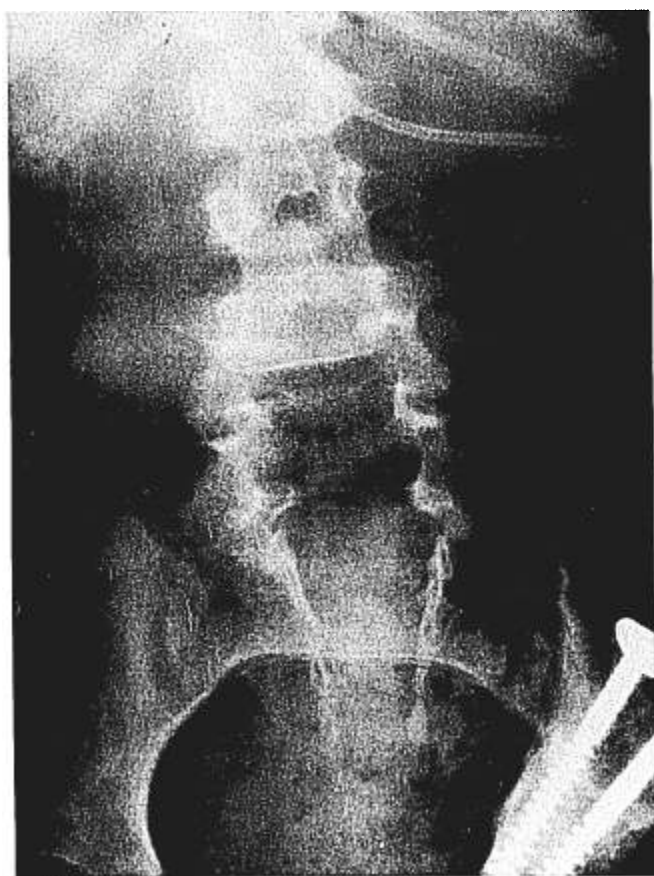

FIG. 3. X-ray of case 4 showing L4-L5 myelodysplasia.

colonic anastomosis, and bladder neck reconstruction under general anesthesia. Postoperatively he developed a right femoral nerve causalgia that was believed to be secondary to prolonged traction or compression intraoperatively. This pain persisted and was relieved only partially by a femoral nerve block 2 months later. Other pain in the right leg was believed to be sympathetically mediated and could be abolished by subarachnoid injection of lidocaine. He was readmitted for lumbar epidural and lumbar sympathetic blockade to treat his reflex sympathetic dystrophy. A 20-G epidural catheter was passed easily via a 17-G Tuohy needle at the L2-L3 interspace and was threaded 3 cm into the epidural space. Bupivacaine 0.125% was infused at 13 ml/h and abolished the pain. The epidural infusion was continued for 115 h.

**Case 6.** A 19-yr-old man weighing 57 kg had an S2-S3 repaired myelomeningocele and neurogenic bladder. He underwent a 16-h procedure that involved splitting of the pubic symphysis, bladder augmentation, excision of diverticula, ureteric reimplantation, and removal of an artificial sphincter mechanism. Thirty-six hours postoperatively, despite adequate intravenous opioids in the intensive care unit, analgesia could not be achieved without causing excessive somnolence and hypoventilation. He subsequently had an epidural catheter inserted at L1-L2 and was given 15 ml lidocaine 1% with 1:200,000 epinephrine, which provided good analgesia and sensory blockade. Three hours later the pain returned, and he received 11 ml 0.25% bupivacaine; and an infusion of 0.125% bupivacaine at 15 ml/h was then begun, with optimal pain relief obtained at 18 ml/h. The epidural infusion was maintained for 84 h.

All epidural catheter insertions in these patients were performed with patients in the lateral position and with full sterile technique. A

test dose of lidocaine 1% with 1:200,000 epinephrine was negative in each case for intravascular and intrathecal effects. All epidural catheters were removed intact.

## DISCUSSION

With epidural analgesia in patients with congenital spinal anomalies, special attention should be given to accurate identification of the epidural space, safe and reliable catheter placement, and determination of the appropriate volume of local anesthetic solution. The state of the underlying anatomy is an essential consideration in the safe performance of epidural analgesia in patients with congenital spinal anomalies.

Sacral agenesis is a rare condition associated with maternal diabetes. Neurologic deficit does not correlate with degree of osseous deficit: these patients often have lower limb sensation, since small sensory nerves may be preserved despite the loss of larger motor nerves.<sup>7,8</sup> Patient 1 above did not have any other anomalies detected on x-ray or myelography, but in such patients other anomalies may be present in the remainder of the spine, including scoliosis, spina bifida, vertebral fusion, tethered cord, lipoma, dermoid cyst, and diastematomyelia,<sup>8,9</sup> that may make identification of the epidural space difficult, as in case 3. Two groups of patients have been identified in sacral agenesis—one with high termination of the subarachnoid space and dural sac stenosis and the other with widened or normal subarachnoid space and a low-lying tethered cord.<sup>10</sup>

In myelodysplasia, evagination occurs and the embryologic neural crest does not fuse, while above the lesion fusion does occur and the neural tube appears to develop and differentiate normally. However, the distance from the skin to epidural space may be reduced, as in patient 4, in whom this distance was outside the normal range for age and weight.<sup>6</sup>

Warner *et al.*<sup>11</sup> reported a case of temporary paraplegia after spinal anesthesia in a 72-yr-old man with a low thoracic spinal cord arteriovenous malformation. Arteriovenous malformations are exceedingly rare in children,<sup>12,13</sup> and there appears to be no increased association with skeletal spinal anomalies.

Preoperative radiologic investigation of the spine is imperative. Anteroposterior and lateral spinal x-rays delineate normal vertebrae and the presence of spinous processes necessary for normal bony landmarks and ligamentous insertions. A recent report by Savolaine *et al.*<sup>14</sup> discusses the assessment of the anatomy of the lumbar epidural space by computed tomography-epidurography, with contrast injected via the sacral caudal canal. This route may not be appropriate in patients with lumbosacral anomalies. Ultrasound has been reported to be helpful in patients with incomplete ossification of the posterior ele-

TABLE 1. Patients, Pain Site, and Epidural Management

Case	Age	Weight (kg)	Spinal Anomaly	Indication for Epidural	Pain Site	Level Inserted	Infusion (ml · kg <sup>-1</sup> · h <sup>-1</sup> )
1	9 months	9	Lumbosacral agenesis	Postoperative analgesia	Perineum	L3-L4	NP
2	3 yr	16	Sacral teratoma	Postoperative analgesia; separation from respiratory support	Upper and lower abdomen, perineum	L2-L3	0.31
3	4 yr	13	Partial sacral agenesis, L4-L5 block vertebrae	Postoperative analgesia; separation from respiratory support	Upper and lower abdomen, perineum	L2-L3	0.38
4	7 yr	24	L4-L5 MML	Postoperative analgesia	Lower abdomen, hip	L2-L3	0.16
5	21 yr	58	L5-S1 MML	Reflex sympathetic dystrophy	Lower extremity	L2-L3	0.22
6	19 yr	57	S2-S3 MML	Postoperative analgesia; failed iv opioid analgesia	Upper and lower abdomen	L1-L2	0.31

MML = myelomeningocele; NP = not performed.

ments, such as in children under 1 yr of age or those with spina bifida.<sup>15</sup> Magnetic resonance imaging may be advantageous over other investigations, since it is noninvasive, provides greater anatomic detail of the spinal cord and surrounding soft tissue, and gives sagittal and parasagittal views<sup>9</sup> (fig. 2).

Once successful placement of an epidural catheter has been accomplished in a patient with a congenital spinal anomaly, the appropriate volume of local anesthetic must be determined. Patients 2 and 4 had lower infusion rates for their postoperative pain control (see table 1) than would be expected for a child with a normal epidural space.<sup>4</sup> The volume of local anesthetic may also depend on the age of the child and the extent of surgery.<sup>16</sup> The dose of local anesthetic should be titrated slowly, by small increments, to achieve adequate analgesia.

A recent text<sup>6</sup> has cautioned the use of epidural blockade in children with a history of hydrocephalus or seizure disorders due to increases in intracranial pressure that can be caused by epidural injection.<sup>17</sup> Patient 4 had a functioning ventriculoperitoneal shunt and had no symptoms of increased intracranial pressure postoperatively. Patient 2, having 2 or 3 seizures per year, had a history of mild seizure disorder. Preoperative computed tomography scan and electroencephalogram were normal; the next seizure occurred 5 months postoperatively.

Patients with lower spinal abnormalities often have other significant anomalies that may require major pelvic and abdominal reconstructive surgery and so would benefit from epidural blockade for postoperative analgesia. Conversely, children having imperforate anus or cloaca repairs have a higher than normal incidence of spinal anomalies<sup>18</sup> that must be recognized if epidural analgesia is to be considered. These patients may also have other indications for epidural blockade, as did patient 5, who had reflex sympathetic dystrophy. The use of epidural analgesia to negate the adverse effects of pain on respiration has been reported previously in children.<sup>19</sup> Adequate postoperative analgesia *via* the epidural route al-

lowed for early successful extubation in cases 2 and 3. All patients except patient 5 had a urinary catheter. After termination of epidural infusion, no patient had unduly prolonged neural blockade. There was no deterioration in the neurologic status of any patient.

In conclusion, the presence of congenital lumbosacral spinal anomalies are not an absolute contraindication to safe epidural analgesia. The preoperative neurologic status should be recorded. Appropriate radiologic investigation of the vertebral column is essential prior to insertion of an epidural catheter at a level of normal vertebral anatomy. Local anesthetic volume requirements may not be predictable. We did not perform epidurography in any of our patients; however, it may be of benefit after insertion of the epidural needle and catheter to outline the epidural space if epidural analgesia is unsuccessful.

The authors gratefully acknowledge the assistance of Charles Berde M.D., Ph.D.

## REFERENCES

1. Dalens B, Tanguy A, Haberer JP: Lumbar epidural anesthesia for operative and postoperative pain relief in infants and young children. *Anesth Analg* 65:1069-1073, 1986
2. Ecoffey C, Dubousset AM, Samii K: Lumbar and thoracic epidural anesthesia for urologic and upper abdominal surgery in infants and children. *ANESTHESIOLOGY* 65:87-90, 1986
3. Desparmet J, Meistelman C, Barre J, Saint-Maurice C: Continuous epidural infusion of bupivacaine for postoperative pain relief in children. *ANESTHESIOLOGY* 67:108-110, 1987
4. Berde CB, Sethna NF, Yemen TA, Pullerits J, Miler V: Continuous epidural bupivacaine-fentanyl infusion in children following ureteral reimplantation. *ANESTHESIOLOGY* 73:A1228, 1990
5. Bromage PR: Epidural Analgesia. Philadelphia, WB Saunders, 1978, p 707
6. Dalens BJ: Pediatric Regional Anesthesia. Boca Raton, CRC Press, 1990, pp 375, 395
7. Andrish J, Kalamachi A, MacEwen GD: Sacral agenesis: A clinical evaluation of its management, heredity and associated anomalies. *Clin Orthop* 139:52-57, 1979
8. Mariani AJ, Stern J, Khan AU, Cass AS: Sacral agenesis: An analysis

- of 11 cases and review of the literature. *J Urol* 122:684-686, 1979
9. Pappas CTE, Seaver L, Carrion C, Rekate H: An anatomical evaluation of the caudal regression syndrome (lumbosacral agenesis) with magnetic resonance imaging. *Neurosurg* 25:462-465, 1989
  10. Brooks SB, El Gammal T, Hartlage P, Beveridge W: Myelography of sacral agenesis. *AJNR* 2:319-323, 1981
  11. Warner DO, Danielson DR, Restall CJ: Temporary paraplegia following spinal anesthesia in a patient with a spinal cord arteriovenous malformation. *ANESTHESIOLOGY* 66:236-237, 1987
  12. Riche MC, Modenesi-Freitas J, Djindjian M, Merland JJ: Arteriovenous malformations of the spinal cord in children. *Neuroradiology* 22:171-180, 1982
  13. Milhorat TH: *Pediatric Neurosurgery*. Philadelphia, FA Davis, 1978, pp 324-326
  14. Savolaine ER, Pandya JB, Greenblatt SH, Conover SR: Anatomy of the human lumbar epidural space: New insights using CT-epidurography. *ANESTHESIOLOGY* 68:217-220, 1988
  15. Naidich TP, Fernbach SK, McLone DG, Shkolnik A: Sonography of the caudal spine and back: Congenital anomalies in children. *Am J Roentgenol* 142:1229-1242, 1984
  16. Warner MA, Kunkel SE, Offord KO, Atchison SR, Dawson B: The effects of age, epinephrine, and operative site on duration of caudal analgesia in pediatric patients. *Anesth Analg* 66:995-998, 1987
  17. Hilt H, Gramm HJ, Link J: Changes in intracranial pressure associated with extradural anesthesia. *Br J Anaesthesia* 58:676-680, 1986
  18. Denton JR: The association of congenital spinal anomalies with imperforate anus. *Clin Orthop* 162:91-98, 1982
  19. Tyler DC: Respiratory effect of pain in a child after thoracotomy. *ANESTHESIOLOGY* 70:873-874, 1989