

JAY B. BRODSKY, M.D.

JAMES B. D. MARK, M.D.

*Departments of Anesthesia and Surgery  
(Division of Thoracic Surgery) Stanford  
University School of Medicine  
Stanford, California 94305*

Anesthesiology  
74:1164, 1991

### Unrecognized Cyanosis during Laser Treatment of Cutaneous Vascular Lesions

*To the Editor:*—The flash-lamp pumped 585-nm tunable pulsed dye laser is currently used extensively in the treatment of cutaneous vascular lesions.<sup>1</sup> At the 585-nm wavelength range (yellow color), this laser is able to pass through epidermis and be absorbed preferentially by oxyhemoglobin in blood vessels.<sup>2</sup> This allows lesional resolution with a dramatic diminution in cutaneous side effects. During the use of this laser, all room personnel as well as the patient need eye protection to prevent retinal damage. The patient's eyes can be closed and covered by an opaque material, while the laser operator and others in the room must wear protective eyewear. Protective glasses and goggles intended for use with this laser block light efficiently in the 577–585-nm range.

The effect of wearing this eyewear, besides protection, is a highlighting of red colors and diminution of blue hues. On more than one occasion, we have noted sedated patients who appeared to be clinically well-oxygenated but in whom oxyhemoglobin saturation ( $Sp_{O_2}$ ) was decreasing. Only with the removal of the protective eyewear was cyanosis readily apparent. In view of this problem, it is imperative that pulse oximetry be used and meticulously followed during the course of anesthesia for laser treatment of cutaneous skin lesions. We also recommend periodic patient assessment without protective eyewear during the procedure, while the laser is on standby. Supplemental oxygen for sedated patients should also be considered, keeping in mind the incendiary potential of this laser as recently reported by Epstein *et al.*<sup>2</sup> Since other lasers used in the treatment of cutaneous vascular lesions (such as the copper-vapor and argon-pumped tunable dye laser) also emit a yellow color, protective eyewear used during their operation could potentially cause similar distortion.

Anesthesiology  
74:1164–1166, 1991

### New Anatomic Landmarks for Percutaneous Catheterization of the Internal Jugular Vein

*To the Editor:*—One of anatomic reasons for choosing the internal jugular vein (IJV) for central venous cannulation is its consistent position in the neck,<sup>1</sup> and most approaches use the sternocleidomastoid muscle as a landmark.<sup>2</sup> The carotid artery (CA)<sup>3</sup> and the IJV itself<sup>4</sup> can also be palpable and visible landmarks. In some cases of anesthetized patients and obese patients, however, all of the above landmarks are less apparent, and it is even more difficult to identify these landmarks during cardiac arrest. For those reasons, we have developed a new approach

- REFERENCES
1. Benumof JL, Partridge BL, Salvatierra C, Keating J: Margin of safety in positioning modern double-lumen endotracheal tubes. *ANESTHESIOLOGY* 67:729–738, 1987
  2. Brodsky JB, Shulman MS, Mark JBD: Malposition of left-sided double-lumen endobronchial tubes. *ANESTHESIOLOGY* 62:667–669, 1985
  3. Atwell SW: Major anomalies of the tracheobronchial tree. *Chest* 52:611–615, 1967

*(Accepted for publication March 8, 1991.)*

JOHN PALMIERI, M.D.  
*Fellow in Pediatric Anesthesia*

JEROME M. GARDEN, M.D.  
*Associate Professor of Clinical Dermatology*

FRANK L. SELENY, M.D.  
*Professor of Clinical Anesthesia*

G. W. STEVENSON, M.D.  
*Assistant Professor of Clinical Anesthesia*

*Children's Memorial Hospital  
Northwestern University Medical School  
Chicago, Illinois 60614*

### REFERENCES

1. Tan TO, Sherwood K, Gilcrest BA: Treatment of children with port-wine stains using the flashlamp-pulsed tunable dye laser. *N Engl J Med* 320:416–424, 1989
2. Epstein RH, Brummett RR, Lask GP: Incendiary potential of the flash-lamp pumped 585 nm tunable dye laser. *Anesth Analg* 71:171–175, 1990

*(Accepted for publication March 8, 1991.)*

for internal jugular venipuncture using bony rather than soft tissue landmarks. In order to validate our experience, we evaluated the new approach in 134 patients prospectively.

With institutional approval and written informed consent from patients, our new approach to internal jugular venipuncture was employed for placement of a pulmonary artery catheter in 134 (96 male, 38 female) anesthetized patients ranging in age from 21 to 84 yr, who were to undergo major abdominal surgery. After general anesthesia

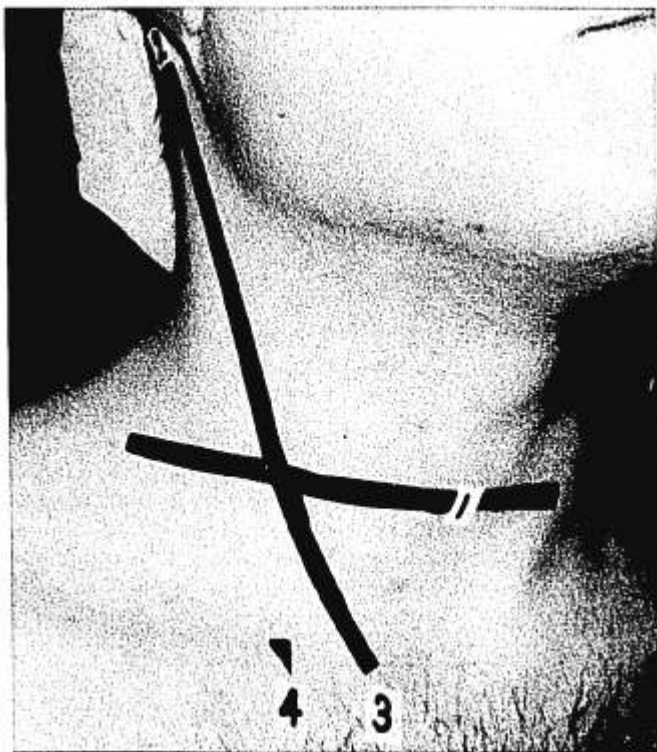


FIG. 1. Four bony landmarks and the puncture site. The puncture site is identified as the intersection of the axial plane at the level of the cricoid cartilage (1) and the line between the mastoid process (2) and the sternal end of the clavicle (3). A needle is introduced toward the notch of the clavicle (4).

was established, the lungs were ventilated by a SERVO 900C ventilator, while a PEEP of 2–5 cmH<sub>2</sub>O was applied during the procedure. Venipuncture was first attempted using the right IJV in all patients, and three attempts were allowed on each side. The right arm was placed alongside the trunk in order to lower the shoulder. The neck of the patient was slightly extended without any rotation of the head, and Trendelenburg's position was not required.

The landmarks of our new approach consist of four bony landmarks: the notch, which was located just above the medial end of the clavicle and was described as a landmark for the location of the IJV by Rao *et al.*<sup>5</sup>; the sternal end of the clavicle; the mastoid process; and the cricoid cartilage. The puncture site was identified as the intersection of the axial plane at the level of the cricoid cartilage and the line between the mastoid process and the sternal end of the clavicle (fig. 1). The location of the CA was identified by palpation, and the relationship between the puncture site and the apex of the triangle formed by the two heads of the sternocleidomastoid muscle and the clavicle was examined. The needle was introduced toward the notch of the clavicle at an angle of 30–45° with the coronal plane. A 23-G, 32-mm-long needle attached to a 5-ml syringe was used for a probing puncture. Next, the IJV was cannulated with a 16-G, 57-mm cannula (JELCO®).

The anatomic landmarks (the cricoid cartilage, the sternal end of the clavicle, the mastoid process, and the notch of the clavicle) were identified in all patients. The notch was located about 1.0 cm lateral to the sternal end of the clavicle. The CA was palpable 1.0–1.5 cm medial to the puncture site in all patients, usually beneath the medial border of the sternocleidomastoid muscle. The relationship of the level of the puncture site and the apex of the "triangle" varied, but the

puncture site was always located between the apex of the triangle and the clavicle. The IJV was entered caudally at this level, where it becomes anterolateral to and separates from the CA.

The right IJV was entered with a probing needle at the first attempt in 120 patients (89.6%). In 10 patients, the IJV was entered at the second trial, and in 4 patients it could not be located even at the third attempt. In 3 of these 4 patients, however, the left IJV could be entered at the first attempt. The IJV was entered within 3 cm, usually 1.5–2 cm, of the skin surface. In one patient, the internal jugular venipuncture failed after a total of six trials, three on each side. In the patients whose IJV was identified, cannulation with a 16-G cannula was accomplished within three attempts (success rate 99.3% [133/134]). The only complication was an arterial puncture in 2 patients.

A notable finding was that the puncture site identified by the new landmarks was consistently just lateral to the CA at the level of the cricoid cartilage. Although Oda *et al.*<sup>5</sup> reported that the anatomic relationship between the IJV and the CA is not distorted by a patient's body habitus, this relationship may have been distorted in our four patients in whom the IJV could not be found even at the third attempt. In fact, notable variations in the anatomic relationship between the IJV and the CA have been shown by ultrasound investigation.<sup>6</sup> Nevertheless, a high rate of success for the current series of patients indicates the anatomic relationship of the puncture site and the IJV was consistent in most of our patients. Our finding that the puncture site was always located nearer to the central vein than was the puncture site associated with other conventional methods may be attributed to this consistency. We speculate that the more proximal it is to the heart, the less the relationship of the CA, the IJV, and the puncture site will vary.

In summary, our new approach to the cannulation of the IJV with four bony landmarks was applied to 134 patients with a high rate of success (99.3%). The puncture site identified by the new bony landmarks was located just lateral to the CA, and the notch of the clavicle was shown to be a precise landmark for the location of the IJV. These bony landmarks were easily identifiable in anesthetized and paralyzed patients and should be useful for prompt cannulation of the IJV during cardiac arrest. The current study clearly indicates the consistent anatomic relationship between the new bony landmarks and the IJV.

EIJI OSHIMA, M.D.\*

Associate Chief of Anesthesiology  
Kitano Hospital

TOSHIYUKI ARAI, M.D.

Assistant Professor of Anesthesiology  
Kyoto University Hospital  
54 Kawahara-cho, Shogoin, Sakyo-ku  
Kyoto 606, Japan

NOBUKATA URABE, M.D.\*

Chief of Anesthesiology  
\*Kitano Hospital  
Tazuke Kofukai Foundation Medical Research Institute  
13-3 Kamiyama-cho, Kita-ku  
Osaka 530, Japan

#### REFERENCES

1. Jernigan WR, Gardner WC, Mahr MM, Milburn JL: Use of the internal jugular vein for the placement of central catheter. *Surg Gynecol Obstet* 130:520–524, 1970
2. Stanly TE III, Reves JG: Cardiovascular monitoring, *Anesthesia*,

- 3rd edition. Edited by Miller RD. New York, Churchill Livingstone, 1990, pp 1031-1099
3. Oda M, Fukushima Y, Hirota T, Tanaka A, Aono M, Sato T: The para-carotid approach for internal jugular catheterization. *Anaesthesia* 36:896-900, 1981
  4. English ICW, Frew RM, Pigott JF, Zaki M: Percutaneous catheterisation of the internal jugular vein. *Anaesthesia* 24:521-531, 1969

5. Rao TLK, Wong AY, Salem MR: A new approach to percutaneous catheterization of the internal jugular vein. *ANESTHESIOLOGY* 46:362-364, 1977
6. Horrow JC, Metz S, Thickman D, Frederic MW: Prior carotid surgery does not affect the reliability of landmarks for location of the internal jugular vein. *Anesth Analg* 66:452-456, 1987

(Accepted for publication March 12, 1991.)

Anesthesiology  
74:1166, 1991

## Ballistocardiography Complicating Tympanoplasty

*To the Editor:*—We recently anesthetized a healthy 9-yr-old, 30-kg boy with chronic otitis media and perforated tympanic membrane for tympanoplasty. The child underwent induction and maintenance of anesthesia with halothane, nitrous oxide, and oxygen. Intubation was performed under deep halothane anesthesia following placement of an intravenous catheter. Ventilation was controlled without a muscle relaxant. After 2.75 h, with inspired halothane at 1.2%, the nitrous oxide was discontinued in preparation for placement of the graft on the perforated tympanic membrane. Fifteen minutes after stopping the nitrous oxide, the heart rate increased from 105 to 125 beats per min without a change in blood pressure. Five minutes later the surgeon noted that there was a disruptive "bouncing" of the surgical field under the microscope. The patient had been placed with his head on what is normally the foot of the bed in order to allow the surgeons to be seated comfortably and operate with the microscope. The operating table and the microscope were checked for stability, and the table was weighted with sandbags in an attempt to damp the distracting movement under the microscope.

Upon further inspection by a senior anesthesiologist, the movement of the field was seen to coincide rhythmically with the heart rate. A ballistocardiogram, in effect, was being observed in the movement of the patient under the microscope. Since the patient had not been forcibly coupled to the operating table, his body was free to respond to cardiac ejection—*i.e.*, to produce the ballistocardiogram. The patient was given 0.5 mg/kg esmolol, which decreased the heart rate from 125 beats per min to 105 beats per min, and the distracting "bouncing" under the microscope stopped. No further  $\beta$ -adrenergic blockade was necessary because the operation finished in approximately 20 min.

Ballistocardiography was a technique employed until the early 1970s to measure cardiac output and force of contraction. In fact, it was used regularly to monitor the rejection of the cardiac homograft during early human cardiac transplantation.<sup>1</sup> The ultra-low-frequency (ULF)

ballistocardiogram is based on measuring the reactive movement of the human body caused by ejection of blood from the heart with each heart beat. The force of contraction is directly proportional to the contractile state of the heart, and in young children with healthy and efficient ventricles, the ballistocardiogram may be evident when standing on a bathroom scale (the pointer moves slightly with each heart beat) and when lying in bed at night (children may mention that the room moves rhythmically). After the nitrous oxide was discontinued, our young patient demonstrated an increase in the contractile state of the heart, which decreased his anesthetic depth and increased his cardiac contractile state. The short-acting, effective  $\beta$ -blocker esmolol alleviated this phenomenon and allowed surgery to continue unencumbered.

BRIAN J. GRONERT, M.D.  
*Assistant Professor of Anesthesiology*

JOHN A. REITAN, M.D.  
*Professor of Anesthesiology*

*Department of Anesthesiology  
University of California, Davis  
2315 Stockton Boulevard  
Sacramento, California 95817*

## REFERENCES

1. Shakespeare T, Reitan JA, Smith NT, Stinson EB, Shumway NE: ULF ballistocardiography in human cardiac transplantation. *Bibl Cardiol* 27(suppl):1-9, 1971

(Accepted for publication March 12, 1991.)

Anesthesiology  
74:1166-1167, 1991

## A Complication Following Prophylactic Blood Patch: Spinal or Subdural Anesthesia?

*To the Editor:*—Leivers reports a complication, apparent total spinal anesthesia, which he attributes to the performance of a prophylactic epidural blood patch.<sup>1</sup> Leivers hypothesizes that the pressure of the epidural blood forced cephalad a sufficiently large volume of lidocaine-containing cerebrospinal fluid to produce total spinal anesthesia.

I would like to suggest subdural anesthesia as an alternate mechanism. Suppose the tip of the epidural catheter migrated into the subdural space between the penultimate and final lidocaine doses. Subdural mi-

gration may have been more likely because of the previous dural puncture.<sup>2,3</sup> The patient would then have received 10 ml 1.5% lidocaine with 1:200,000 epinephrine 37 min before the apneic episode. Leivers's case report sounds suspiciously similar to Massey Dawkin's description of "massive extradural" (*i.e.*, subdural) anesthesia: "All goes well for about 20 min. Then respiration slowly fails; the pupils dilate, but the blood pressure does not fall. . . . Assuming that 2% lidocaine was used, the patient suddenly wakes up after 1¼ h, resumes breathing,