

Administration (FDA), further revised the label and package insert for Diprivan®. The new labeling and package insert instructions for Diprivan®, as summarized below, further emphasize the importance of adherence to strict aseptic techniques:

- Prepare just prior to each procedure
- Withdraw contents immediately after opening
- Administer promptly
- Complete administration in 6 h

The 6-h time limit for use after opening an ampule or vial was established in close consultation with the FDA. This time limit was selected to reinforce the importance of using safe handling procedures in the preparation and administration of Diprivan®.

DAVID B. GOODALE, D.D.S., PH.D.
Associate Director, CNS and Anesthesia
Stuart Pharmaceuticals
ICI Pharmaceuticals Group
Wilmington, Delaware 19897

REFERENCES

1. Guilfoyle DE, Yager JF: Procedures used in sterility testing of parenteral drugs by an FDA field laboratory. *J Parenter Sci Technol* 38:138-141, 1984

(Accepted for publication February 25, 1991.)

Anesthesiology
74:1157, 1991

A Modification of the Laryngeal Mask Airway

To the Editor:—We agree with Grebenik *et al.*¹ that the laryngeal mask airway (LMA) offers particular advantages over traditional techniques for providing general anesthesia to children receiving radiotherapy. We report a potential problem and our solution.

We were recently asked to provide anesthesia for a 3-yr-old boy undergoing a course of radiotherapy for a rhabdomyosarcoma. The patient was to be prone, as the treatment involved the spine as well as the head, which was to be held firmly in a plastic mold. There was no evidence of cerebral edema or raised intracranial pressure. As we were anxious to avoid frequent tracheal intubation, the laryngeal mask was considered. At the planning session, a size-2 LMA was inserted under inhalational anesthesia, allowing spontaneous ventilation *via* a clear airway. However, after turning to the prone position, there was marked clinical evidence of partial airway obstruction, including intercostal and suprasternal recession, paradoxical respiration, and stridor. Although hemoglobin saturation remained above 96%, an unacceptable end-tidal carbon dioxide (ET_{CO₂}) of 9% was recorded. A lateral radio-

graph, taken to plan therapy, revealed a sharp kink in the tube of the LMA.

A size-2 LMA was reinforced internally with a shortened plain 5.5-mm Mallinckrodt armored tracheal tube and was used on the next occasion. The clinical signs of airway obstruction described above were no longer present, and ET_{CO₂} was recorded at 6-6.5%. This modification allowed us to avoid repeated tracheal intubation. Figure 1 illustrates that kinking is prevented in the modified LMA.

We understand that the manufacturers are to strengthen the size-2 LMA to avoid the problem of kinking, although it is difficult to imagine that anything other than wire reinforcement would have prevented kinking in the position our patient was required to adopt.

I. G. WILSON,* F.F.A.R.C.S.
Lecturer

R. EASTLEY, F.F.A.R.C.S.
Consultant

*University Department of Anaesthesia
Leicester Royal Infirmary
Leicester LE1 5WW
United Kingdom*

**Current affiliation:
Visiting Assistant Professor
Department of Anesthesiology
University of Oklahoma
Oklahoma City, Oklahoma 73152*

REFERENCE

1. Grebenik CR, Ferguson C, White A: The laryngeal mask airway in pediatric radiotherapy. *ANESTHESIOLOGY* 72:473-477, 1990

(Accepted for publication February 26, 1991.)

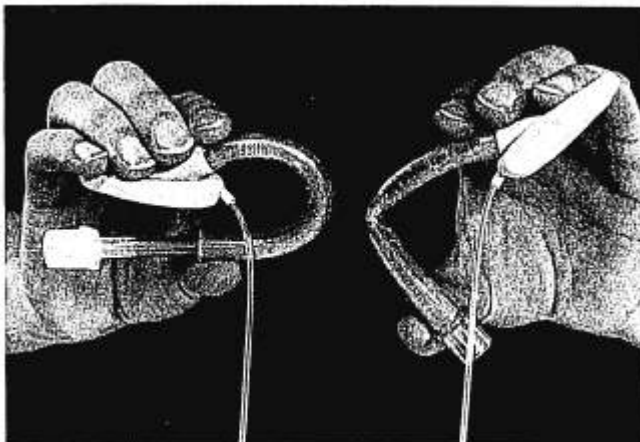


FIG. 1. Modified (*left*) and standard (*right*) LMAs.