

FIG. 1. Size 8.0-mm ID Mallinckrodt Hi-Lo (*top*) and Sheridan (*bottom*) polyvinylchloride endotracheal tubes. The Sheridan tube's longer cuff can be seen.

Anesthesiology
74:962, 1991

In Reply:—Dr. Sosis brings up an interesting point in that the original study to which he refers was done with Mallinckrodt intermediate Hi-Lo cuffed endotracheal tubes. The Sheridan cuff is indeed more proximal to the 15-mm adapter than is the Mallinckrodt, so the high position of the cuff he describes is certainly possible in a tall patient with a long neck. The photograph (fig. 1 accompanying his letter) exaggerates the more proximal position of the Sheridan cuff, whereas in fact it is only 8 mm closer to the 15-mm adapter than is the cuff on the Mallinckrodt. It is difficult to believe that 8 mm would make a significant difference in most patients.

I disagree with Dr. Sosis's conclusion that the technique of routinely securing endotracheal tubes at the 21- or 23-cm marks at the incisor teeth should be abandoned on the basis of his finding. If a tall patient has a persistent leak after placement of an endotracheal tube when the tube is taped at predetermined centimeter markings, then the tube should be placed more distal in the trachea. The method of using arbitrary marks to secure the endotracheal tube has made endobronchial intubation a rare event in our 50-bed intensive care unit (ICU) over the past 5 yr. An endotracheal tube cuff leak usually is obvious

Anesthesiology
74:962-963, 1991

Another Reason for Difficult Pulmonary Artery Catheterization

To the Editor:—We recently encountered a case in which pulmonary artery catheterization was difficult. The patient was a 70-year-old man scheduled for repeat coronary artery bypass grafting. As part of our anesthetic management, pulmonary artery catheterization under local anesthesia and sedation was planned. The right subclavian vein was cannulated, and an Abbott Opticath, fiberoptic pulmonary catheter (Model P7110-EPH-8, list number 50328) was inserted. When the catheter tip was advanced towards the right ventricle, atrial premature contractions followed by ventricular premature contractions were observed. However, a right ventricular pressure trace was never seen.

tubes obtained from different manufacturers, we caution against their technique of endotracheal tube placement. Instead, we recommend securing the endotracheal tube after its cuff has been noted to be below the vocal cords on laryngoscopy.

MITCHEL B. SOSIS, M.D., PH.D.
Assistant Professor

RONALD E. HARBUT, M.D., PH.D.
Resident

*Department of Anesthesiology
Rush-Presbyterian-St. Luke's Medical Center
1653 West Congress Parkway
Chicago, Illinois 60612*

REFERENCES

- Owen RL, Cheney FW: Endobronchial intubation: A preventable complication. *ANESTHESIOLOGY* 67:255-257, 1987

(Accepted for publication February 11, 1991.)

and is easily remedied, whereas endobronchial intubation may be more difficult to diagnose in the absence of a chest x-ray and can certainly lead to more serious consequences. I have no quarrel with the technique of securing the endotracheal tube at the point at which the cuff is just below the vocal cords on laryngoscopy, as recommended by Dr. Sosis. There are, however, drawbacks to this technique, in that the cords are not necessarily visualized with every laryngoscopy, and in that in the ICU laryngoscopy is not a convenient method for frequent documentation of tube position. No method of doing anything in medicine is fool-proof.

FREDERICK W. CHENEY, M.D.
*Professor, Anesthesiology
Department of Anesthesiology, RN-10
University of Washington
Seattle, Washington 98195*

(Accepted for publication February 11, 1991.)

The process was repeated several times with the patient first supine and then in the head-up, right lateral tilt position,¹ with the same results. Connections to the transducers were confirmed as correct. The catheter then was removed for inspection. It was noted that injection of fluid into the blue-colored port labeled "CVP PROXIMAL" came out the distal lumen orifice, while injection of fluid into the port labeled "PA DISTAL" emerged from the proximal CVP lumen. A second pulmonary artery catheter was obtained, and the patient's pulmonary artery was successfully catheterized.

Factors predisposing to difficult pulmonary artery catheter placement

include an enlarged right ventricular cavity, pulmonary hypertension, and low cardiac output.² Initially, it was believed that these factors were contributory. An improved success rate and less serious arrhythmias have been observed when the patient is placed in the head-up, right lateral tilt position.¹ However, this study used internal jugular vein catheterization, and we used the right subclavian vein, and therefore, these observations may not be entirely applicable. Our suspicions of a defective catheter were aroused by noting ventricular premature contractions with catheter advancement but without a right ventricular pressure trace.

In summary, difficult pulmonary artery catheterization may result from a manufacturing error in the catheter that is not obvious upon superficial inspection. Before resorting to various maneuvers to manipulate a pulmonary artery catheter into position, we recommend that the catheter be checked for incorrect labeling.

Anesthesiology
74:963-964, 1991

STUART K. BERGMAN, M.D.
J. FRANCISCO JIMENEZ, M.D.
First Coast Anesthesia Services
1229 Romeny Street
Jacksonville, Florida 32211

REFERENCES

1. Kensch DJ, Winters S, Thys DM: The Patient's position influences the incidence of dysrhythmias during pulmonary artery catheterization. *ANESTHESIOLOGY* 70:582-584, 1989
2. Sprung CL, Jacobs LJ, Caralis PV, Karpf M: Ventricular arrhythmias during Swan-Ganz catheterization of the critically ill. *Chest* 79:413-415, 1981

(Accepted for publication February 11, 1991.)

Connecting a Jet Stylet to a Jet Injector

To the Editor:—Recently the concept and use of a jet stylet during extubation of patients in whom subsequent ventilation and/or reintubation may be difficult was described.¹ A jet stylet is a small-internal-diameter (ID), hollow, semirigid catheter that is inserted into an *in situ* endotracheal tube (ETT) prior to extubation. After the ETT is withdrawn over the jet stylet, the small-ID hollow catheter may then be used as a means of ventilation (*i.e.*, the jet function) and/or as an intratracheal guide for reintubation (*i.e.*, the stylet function). The jet function may safely allow additional time to assess the need for the stylet function.

We have been using a commercial tube exchanger as our jet stylet catheter and have made the connection of the tube exchanger to a jet injector by wedging the hub of an appropriately sized intravenous (iv) catheter into the tube exchanger (14-, 16-, and 18-G iv catheter hubs fit into the large, medium and small Sheridan tracheal tube exchangers, respectively [Sheridan Catheter Corporation, Argyle, NY]).^{2*} However, the iv catheter cannot be in place during the removal of the ETT since the ID of the ETT ordinarily does not fit over the hub of the iv catheter. In addition, wedging the iv catheter into the tube exchanger usually takes both times ($\frac{1}{2}$ to 1 min) and a significant degree of finger strength; consequently, the wedging should be done prior to use of the jet stylet in order to dilate the proximal end of the jet stylet and allow the iv catheter-tube exchanger connection to be made more swiftly when the need actually arises.

We have devised a simple, inexpensive attachment that when preassembled provides for much easier and faster connection of the tube exchanger to a jet injector. A metal female Luer lock-barbed cone adaptor (either Beckton Dickinson Co., Rutherford, NJ, parts 3092 [metal] or 3250 [plastic] or Popper & Son, Inc., New Hyde Park, NY, catalogue number 6174 [metal]) is inserted into the proximal end of 4.0-cm lengths of 5.0-, 4.0-, and 3.0-mm-ID ETT and the distal end of the 4.0-cm lengths of 5.0-, 4.0-, and 3.0-mm-ID ETT fit very snugly over the proximal end of large, medium, and small Sheridan tracheal tube exchangers, respectively (fig. 1). Of course, the female Luer lock attaches directly to the jet injector.² The ID of the metal adaptor (1.93 mm) is larger than a 14-G iv catheter (1.47 mm). Since it is far easier and quicker to push the open end of the 4.0-cm length of ETT onto

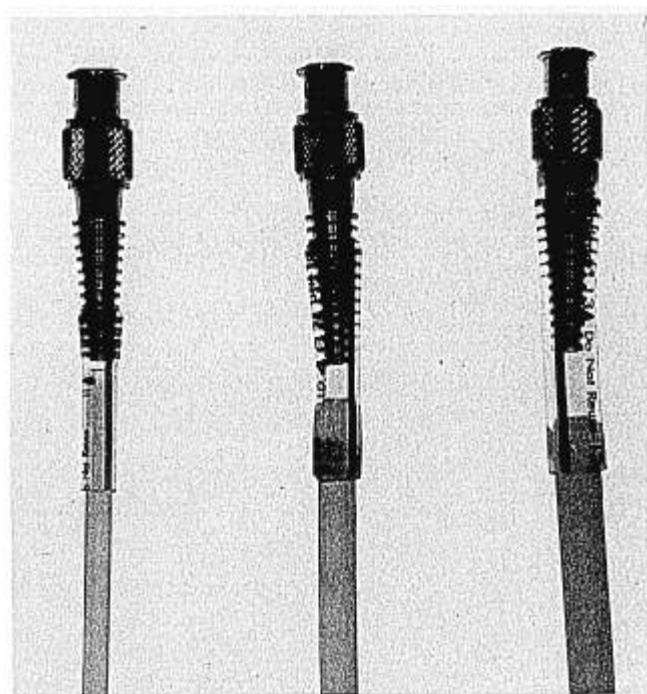


FIG. 1. Attachment of jet stylet to the jet injector. A metal female Luer lock-barbed cone adaptor is fitted into the proximal end of 4.0-cm lengths of 5.0-, 4.0-, and 3.0-mm endotracheal tubes (*right to left, respectively*). The distal end of the 5.0-, 4.0-, and 3.0-mm lengths of endotracheal tube fit over the proximal end of large, medium, and small Sheridan tracheal tube exchangers, respectively. The female Luer lock connects to the jet injector.

the proximal end of the tube exchanger than it is to wedge an iv catheter hub into the hollow end of the tube exchanger, it is much easier and quicker to institute jet ventilation with the new system compared to the old system. Consequently, we think that this is the best method currently available for connecting a tube exchanger to a jet injector.

* Benumof JL. Management of the Difficult or Impossible Airway. *ASA Refresher Courses in Anesthesiology* 163:7, 1990