

to ~3 days after complete denervation but can be decelerated back to preinnervation rate by reinnervation. The $t_{1/2}$ of immature AChR is ~1 day. The qualitative changes occurring in our model of *partial* denervation are unknown, although our model confirms quantitative increases in AChR at 2 weeks after injury.¹ If qualitative changes do occur, the transition time for its conversion is also unknown, since this depends on the $t_{1/2}$.⁵

In the model of partial denervation we used, we speculate that the junctional and extrajunctional AChRs affecting neurotransmission (twitch response) have a dual (mature and immature) population of AChRs. The ligand, ¹²⁵I- α -bungarotoxin, used to quantitate AChR, however, does not differentiate them. In contrast to α -bungarotoxin, the affinity for *d*Tc is different.⁴ The affinity of *d*Tc being higher for the mature AChR, in our study low concentrations of *d*Tc may have antagonized the mature receptors only, resulting in 50% twitch depression. Inactivation of the remaining AChR, which are immature, on the other hand, would require a higher concentration of *d*Tc because of its lower affinity. Thus, the dual population hypothesis may explain the lack of difference in ED₅₀ but a significant difference in the ED₉₅. Examination of the slopes of the dose-response curves indicates a significantly flatter slope ($P = 0.02$) in the denervated and suggests an altered affinity state, possibly due to a qualitative change.

Would the results be different had the experiment been performed at a later period than 2 weeks when all AChR may have been converted to the immature form? In this instance all AChRs would be resistant to *d*Tc and a significant rightward shift of the curve would occur at the lower (ED₅₀) and upper ends (ED₉₅) of the curve in addition to a flatter slope. Such a pattern was observed in the rodent burn model where the slope was flatter, and the ED₅₀ and ED₉₅ shifted to the right.⁶ In another report on the effects of endotoxin, we observed again that $\frac{1}{4}$ LD₅₀ of endotoxin shifted ED₉₅ but not ED₅₀ at 2 weeks, while $\frac{1}{2}$ LD₅₀ doses shifted both ED₅₀ and ED₉₅.⁷ Thus, the neuromuscular junctional changes may be related to both severity and duration of insult.

Relative to the second point, it should be reiterated that in the burn model too the EDs were significantly correlated with AChR number, but similar to the denervation model, a poorer correlation between ED₅₀ compared to ED₉₅ and AChR was observed.⁶ The dual population hypothesis referred to earlier may explain this. We disagree with the approach suggested by Dr. Storella that the correlation between ED and AChR be considered for denervated group only, since this approach does not reflect the full spectrum of changes in AChR number. However, if the denervation group was studied at different times after injury, where the spectrum of changes in AChR would vary from minimal to marked, the data analysis suggested by Dr. Storella would have been possible.

In summary, our study demonstrates that partial denervation causes resistance to *d*Tc. As indicated in the discussion, an important mechanism implicated is the up-regulation of AChR. Alternate or additional and very plausible explanations include altered affinity, partial denervation-induced terminal nerve sprouting, which increases the margin of safety, and possibly altered channel properties. The relative contributions of each of these remain to be characterized.

J. A. J. MARTYN, M.D.
*Associate Professor of Anaesthesiology
Harvard Medical School and
Massachusetts General Hospital
Boston, Massachusetts 02114*

C. W. HOGUE, JR., M.D.
*Assistant Professor of Anesthesiology
Washington School of Medicine
St. Louis, Missouri 63110*

REFERENCES

1. Hogue CW, Jr., Itani MS, Martyn JAJ: Resistance to d-tubocurarine in lower motor neuron injury is related to increases in acetylcholine receptors at the neuromuscular junction. *ANESTHESIOLOGY* 73:703-709, 1990
2. Schuetze SM, Role LW: Developmental regulation of nicotinic acetylcholine receptors. *Annu Rev Neurosci* 10:403-465, 1987
3. Gu Y, Hall ZW: Immunological evidence for a change in subunits of acetylcholine receptor in developing and denervated rat muscle. *Neuron* 1:117-125, 1988
4. Beranek R, Vyskocil F: The action of d-tubocurarine and atropine on the normal and denervated rat diaphragm. *J Physiol* 188: 53-66, 1967
5. Shyng SL, Salpeter MM: Effect of reinnervation on the denervation rate of junctional acetylcholine receptors synthesized in denervated skeletal muscles. *J Neurosci* 10:3905-3915, 1990
6. Kim C, Martyn JAJ, Fuke N. Burn injury to trunk of rat causes denervation-like responses in the gastrocnemius muscle. *J Appl Physiol* 65:1745-1751, 1989
7. Tomera JF, Martyn JAJ. Intraperitoneal endotoxin but not protein malnutrition shifts d-tubocurarine dose-response curves in mouse gastrocnemius muscle. *J Pharmacol Exp Ther* 250:216-220, 1989

(Accepted for publication February 10, 1991.)

A Caution on the Use of Routine Depth of Insertion of Endotracheal Tubes

To the Editor:—A group of anesthesiologists at our institution use the technique of Owen and Cheney¹ of routinely securing endotracheal tubes after orotracheal intubation when the 23- or 21-cm marks are at the incisor teeth for normal adult men and women patients, respectively. However, our hospital recently changed from stocking Mallinckrodt (Glens Falls, NY) Hi-Lo polyvinylchloride (PVC) endotracheal tubes to Sheridan (Argyle, NY) PVC tubes. We initially experienced difficulty in adequately making an airtight seal by inflating the tube's cuff in several patients after orotracheal intubation using the Sheridan

tubes. Direct laryngoscopy in these cases revealed that the endotracheal tube's cuff was protruding from the larynx into the hypopharynx. On comparing the two types of endotracheal tubes (fig. 1), it can be seen that the cuff on the Sheridan endotracheal tube is longer and that its proximal end is placed closer to the 15-mm adapter than is that of the Mallinckrodt tube.

Owen and Cheney¹ did not specify the type of endotracheal tube used when they described their technique of arbitrary tube placement at the incisors. Due to the variation in cuff position on endotracheal

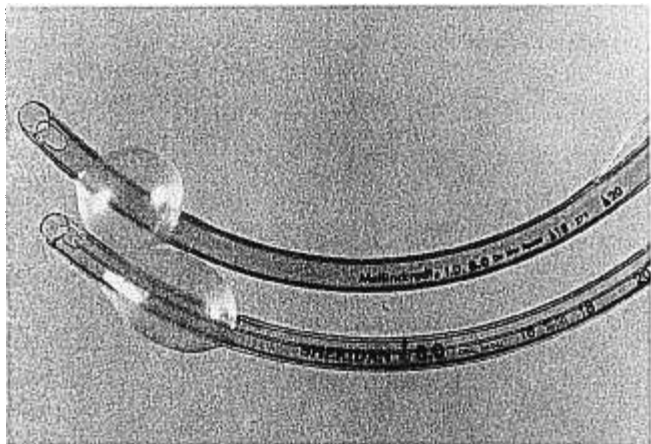


FIG. 1. Size 8.0-mm ID Mallinckrodt Hi-Lo (*top*) and Sheridan (*bottom*) polyvinylchloride endotracheal tubes. The Sheridan tube's longer cuff can be seen.

Anesthesiology
74:962, 1991

In Reply:—Dr. Sosis brings up an interesting point in that the original study to which he refers was done with Mallinckrodt intermediate Hi-Lo cuffed endotracheal tubes. The Sheridan cuff is indeed more proximal to the 15-mm adapter than is the Mallinckrodt, so the high position of the cuff he describes is certainly possible in a tall patient with a long neck. The photograph (fig. 1 accompanying his letter) exaggerates the more proximal position of the Sheridan cuff, whereas in fact it is only 8 mm closer to the 15-mm adapter than is the cuff on the Mallinckrodt. It is difficult to believe that 8 mm would make a significant difference in most patients.

I disagree with Dr. Sosis's conclusion that the technique of routinely securing endotracheal tubes at the 21- or 23-cm marks at the incisor teeth should be abandoned on the basis of his finding. If a tall patient has a persistent leak after placement of an endotracheal tube when the tube is taped at predetermined centimeter markings, then the tube should be placed more distal in the trachea. The method of using arbitrary marks to secure the endotracheal tube has made endobronchial intubation a rare event in our 50-bed intensive care unit (ICU) over the past 5 yr. An endotracheal tube cuff leak usually is obvious

Anesthesiology
74:962-963, 1991

Another Reason for Difficult Pulmonary Artery Catheterization

To the Editor:—We recently encountered a case in which pulmonary artery catheterization was difficult. The patient was a 70-year-old man scheduled for repeat coronary artery bypass grafting. As part of our anesthetic management, pulmonary artery catheterization under local anesthesia and sedation was planned. The right subclavian vein was cannulated, and an Abbott Opticath, fiberoptic pulmonary catheter (Model P7110-EPH-8, list number 50328) was inserted. When the catheter tip was advanced towards the right ventricle, atrial premature contractions followed by ventricular premature contractions were observed. However, a right ventricular pressure trace was never seen.

tubes obtained from different manufacturers, we caution against their technique of endotracheal tube placement. Instead, we recommend securing the endotracheal tube after its cuff has been noted to be below the vocal cords on laryngoscopy.

MITCHEL B. SOSIS, M.D., PH.D.
Assistant Professor

RONALD E. HARBUT, M.D., PH.D.
Resident

*Department of Anesthesiology
Rush-Presbyterian-St. Luke's Medical Center
1653 West Congress Parkway
Chicago, Illinois 60612*

REFERENCES

- Owen RL, Cheney FW: Endobronchial intubation: A preventable complication. *ANESTHESIOLOGY* 67:255-257, 1987

(Accepted for publication February 11, 1991.)

and is easily remedied, whereas endobronchial intubation may be more difficult to diagnose in the absence of a chest x-ray and can certainly lead to more serious consequences. I have no quarrel with the technique of securing the endotracheal tube at the point at which the cuff is just below the vocal cords on laryngoscopy, as recommended by Dr. Sosis. There are, however, drawbacks to this technique, in that the cords are not necessarily visualized with every laryngoscopy, and in that in the ICU laryngoscopy is not a convenient method for frequent documentation of tube position. No method of doing anything in medicine is fool-proof.

FREDERICK W. CHENEY, M.D.
*Professor, Anesthesiology
Department of Anesthesiology, RN-10
University of Washington
Seattle, Washington 98195*

(Accepted for publication February 11, 1991.)

The process was repeated several times with the patient first supine and then in the head-up, right lateral tilt position,¹ with the same results. Connections to the transducers were confirmed as correct. The catheter then was removed for inspection. It was noted that injection of fluid into the blue-colored port labeled "CVP PROXIMAL" came out the distal lumen orifice, while injection of fluid into the port labeled "PA DISTAL" emerged from the proximal CVP lumen. A second pulmonary artery catheter was obtained, and the patient's pulmonary artery was successfully catheterized.

Factors predisposing to difficult pulmonary artery catheter placement