

3. Martin RW, Bashein G, Zimmer R, Sutherland J: An endoscopic micromanipulator for multiplanar transesophageal imaging. *Ultrasound Med Biol* 12:965-975, 1986
4. Martin RW, Bashein G: Measurement of stroke volume with three-dimensional transesophageal ultrasonic scanning. *ANESTHESIOLOGY* 70:470-476, 1989

5. Abel MD, Nishimura RA, Callahan MJ, Rehder K, Ilstrup DM, Tajik AJ: Evaluation of intraoperative transesophageal two-dimensional echocardiography. *ANESTHESIOLOGY* 66:64-68, 1987

(Accepted for publication January 29, 1991.)

Anesthesiology  
74:959, 1991

*In Reply:*—Dr. Bashein and Dr. Martin have devised an ingenious solution to the difficulties of imaging the left ventricle in dogs using transesophageal echo techniques. Although surgery is required, the experimental model that they have developed should provide useful insights into the problems of transesophageal imaging for the detection of myocardial ischemia.

One important caveat is the requirement for thoracotomy to exploit the Bashein/Martin model. It is well recognized that thoracotomy induces abnormalities of cardiac motion at least as delineated by transthoracic echocardiography. Various explanations have been offered for these abnormalities, including alterations in intrathoracic rotational and translational motion, regional ischemia, effects of cardioplegia, and cardiopulmonary bypass.<sup>1,2</sup> These thoracotomy-induced alterations may introduce an additional variable into studies of ischemic dyskinesia and must be considered by researchers performing transesophageal echos in dogs using the Bashein/Martin thoracotomy model.

RICHARD E. KERBER, M.D.  
*Professor of Medicine*

Anesthesiology  
74:959-960, 1991

BYRON F. VANDENBERG, M.D.  
*Assistant Professor of Medicine*

*Cardiovascular Division  
Department of Internal Medicine  
The University of Iowa  
Iowa City, Iowa 52242*

#### REFERENCES

1. Kerber RE, Litchfield R: Postoperative abnormalities of interventricular septal motion: Two-dimensional and M-mode echocardiographic correlations. *Am Heart J* 104:263-268, 1982
2. Lehmann KG, Lee FA, McKenzie WB, Barash PG, Prokop EK, Durkin MA, Ezekowitz MD: Onset of altered interventricular motion during cardiac surgery: Assessment by continuous intraoperative transesophageal echocardiography. *Circulation* 82: 1325-1334, 1990

(Accepted for publication January 29, 1991.)

### Hazard with Warming Lights

*To the Editor:*—Safety features found on equipment are often unappreciated, especially if they function only on rare occasions. We would like to call attention to an operating room situation where the protective feature of a heating lamp most likely prevented a serious untoward event. However, this safety feature alone may not always offer full protection against the failure conditions for which it was designed.

A 21-yr-old man was undergoing retroperitoneal lymph node dissection for a metastatic testicular seminoma. All measures were taken to preserve his body heat, including the use of an Emerson 96-HB warming light (J. H. Emerson Co., Cambridge, MA). This device supplies radiant heat by means of two 250-W infrared producing light bulbs. A safety feature of the warming lights consists of a double layer of wire mesh around the sides of each bulb and a single layer on the front. The wire mesh is made from strands 0.5 mm in diameter and consists of a grid 6 × 6 cm.

During the case, the warming light was directed at the head of the patient from a distance of 72 cm, as determined by an integral measuring rod. The light was positioned so that the bulbs were directly below an intravenous (iv) fluid bag and administration set on an IV pole (fig. 1). During one of the frequent replacements of the iv fluid bag, several drops of residual solution fell onto one of the heat-producing light bulbs. The resultant thermal shock on the glass bulb caused it to explode. The wire mesh around the bulb prevented glass shards

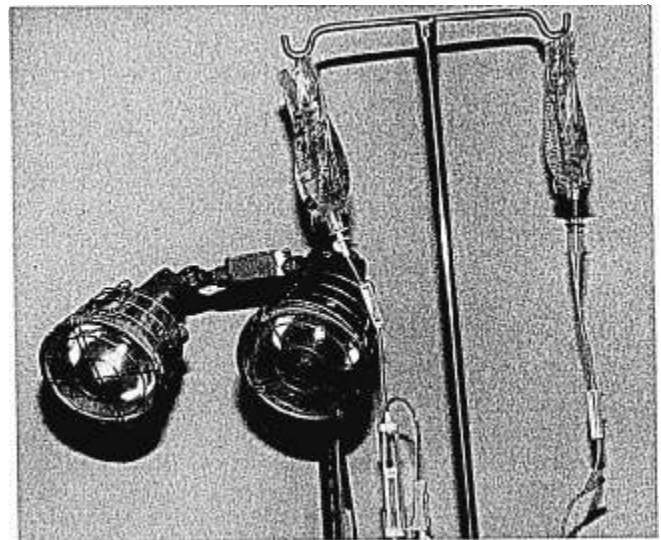


FIG. 1. Bag of fluid hanging directly over warming lights. Note protective wire mesh over the front of the lights.