

TITLE: COMPARISON OF THIOPENTAL-ISOFLURANE-N₂O, PROPOFOL - N₂O, AND PROPOFOL ALONE FOR NEUROANESTHESIA

AUTHORS: J. Van Hemelrijck, MD, R. Tempelhoff, MD, W.S. Jellish, MD, PhD, P.F. White, PhD, MD

AFFILIATION: Department of Anesthesiology, Washington University, St. Louis, MO 63110

Concerns regarding the use of propofol in neuroanesthesia have been raised because of its possible adverse effects on cerebrovascular hemodynamics. This study compared the hemodynamic and EEG effects of a thiopental-isoflurane and two propofol-based anesthetic techniques before surgical stimulation.

After obtaining informed consent, 42 patients (ASA 1-3; age 18-74) scheduled for neurosurgical procedures, were randomly assigned to one of three treatment groups according to an IRB-approved protocol. All patients were premedicated with diazepam, 10-20 mg po. Group 1 was induced with thiopental, 3-5 mg/kg, and anesthesia was maintained with 70% N₂O and isoflurane, 0.25-0.5%. Groups 2 and 3 were induced with a loading infusion of propofol at 1 mg/kg/min until loss of the eyelash reflex. Initial propofol maintenance infusion rates were 9 mg/kg/h (with 70% N₂O) in Group 2, and 12 mg/kg/h (without N₂O) in Group 3. Fentanyl, 3-6 µg/kg, followed by an infusion of 1-4 µg/kg/h was administered to all patients for analgesia. A two channel EEG (Neurotrac, Interspec) was continuously monitored. The power in each frequency band was averaged over 1 min epochs. Arterial pressure (BP) was measured directly. Baseline BP, lowest BP before and after

intubation, and highest BP at intubation, and the corresponding heart rate values were recorded. ANOVA and student's t-test were used for data analysis, with p<0.05 considered significant.

Induction doses for the three treatment groups were thiopental 4.2±1.5 mg/kg(1), and propofol 2.0±0.2(2), and 2.0±0.2 mg/kg(3). Although Group 1 patients received more fentanyl before intubation (5.9±2.8 vs 3.6±1.7 and 3.3±2.3 µg/kg for Groups 2 and 3), hemodynamic changes were similar for the three treatment groups (fig. 1). EEG-power changes in the different frequency bands were similar for all three groups. However, a larger number of propofol-treated patients had a burst suppression EEG pattern during the 60 min study period (fig. 2) indicative of a greater "depth" of anesthesia.

We conclude that propofol alone or in combination with N₂O is a satisfactory alternative to a standard thiopental-isoflurane N₂O technique for neurosurgical anesthesia. Compared to thiopental-isoflurane, EEG analysis would suggest that a greater "depth of anesthesia" was achieved with the propofol-based techniques.

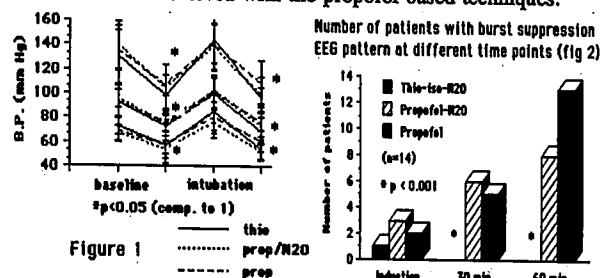


Figure 1

— thiopental
..... prop/N₂O
- - - prop

TITLE: FENTANYL-INDUCED TEMPORAL LOBE SEIZURE ACTIVITY RECORDED WITH EPIDURAL (INCLUDING PERIHIPPOCAMPAL) ELECTRODES

AUTHORS: R. Tempelhoff, M.D., K.L. Bernardo, M.D., P.A. Modica, M.D., I. Edwards, P.A.

AFFILIATION: Depts. Anes. & Neurosurg., Washington University, St. Louis, MO 63110

Fentanyl, a potent narcotic agent, is commonly used for anesthesia during epilepsy surgery (1,2). Scalp EEG's in patients receiving low to moderate doses of fentanyl have failed to demonstrate electrical seizure activity (3,4). The purpose of this study was to determine whether fentanyl is capable of evoking electrical seizure activity in patients with complex partial seizures monitored with epidural (including perihippocampal) electrodes.

During the first surgical stage (2), bitemporal epidural electrodes were inserted under general anesthesia in 6 patients, after institutional approval and informed consent had been obtained. After surgery, the patients were monitored for 2 to 3 days in a quiet setting without pharmacological interference. The symptomatic temporal lobe was identified by correlating clinical and electrical seizure activity obtained during continuous simultaneous video and epidural EEG monitoring. During the second surgical stage, electrodes were removed and anterior temporal lobectomy performed on the symptomatic side (3 right, 3 left). After placement of the standard anesthetic monitors continuous recordings were made from the epidural electrodes with a Grass EEG. An iv fentanyl infusion was started, at a rate of 500 µg/min, while the patient was breathing 100% O₂ per mask. Subsequently ventilation was controlled to maintain an SaO₂ >99% and ETCO₂ at 35 mmHg. Shortly after

the onset of electrical seizure activity the fentanyl infusion was stopped, thiopental and/or benzodiazepine given and routine anesthesia management started.

Each patient exhibited electrical seizure activity at a fentanyl dose ranging from 20 to 52 µg/kg administered over 2 to 7 min. Four of the 6 patients had electrical seizure activity on the side opposite that from which the clinical partial complex seizures had been shown to arise during the awake monitoring period. Most of the electrical seizure activity was detected in the medial (i.e. perihippocampal) electrode leads only; seizure activity in this location would not be detected with routine scalp (surface) EEG (5).

Our results suggest that fentanyl triggers electrical seizure activity in patients with partial complex seizures, frequently in locations different from that in which the clinical seizures arise. This finding could be important for the anesthetic management of patients undergoing electrocorticography for seizure focus localization during resection.

References: 1) International Anesthesiology Clinics 24 (3), 1986. 2) J Neurosurg 60:457-466, 1984. 3) Anesth Analg 70:303-315, 1990. 4) Anesthesiology 71:852-862, 1989. 5) Brain 98:129-156, 1975.

ORIGIN OF FENTANYL-INDUCED ELECTRICAL SEIZURE ACTIVITY WITH RESPECT TO SYMPTOMATIC TEMPORAL LOBE			
Pt.#	Ipsilateral	Contralateral	Fentanyl Dose (µg/kg)
1	-	+	38.71
2	-	+	20
3	+	-	33.33
4	-	+	20
5	+(a)	+	51.72(b)
6	+	-	25

(a) Continuous seizure activity from ipsilateral temporal lobe throughout induction, as in real-time record.
(b) Fentanyl dose at which contralateral seizure activity was evoked.