

- changes in intra- and extracellular potassium and responses to neuromuscular blocking agents. *Anesth Analg* 57:417-421, 1978
6. Davis R: Etiology and treatment of perioperative cardiac dysrhythmia, *Cardiac Anesthesia*. Edited by Kaplan J. Philadelphia, WB Saunders, 1987, pp 411-450
 7. Solomon RJ, Katz JD: Disturbances of potassium homeostasis, *Advances in Anesthesia*. Edited by Stoelting RK, Barash PG, Galagher TJ. Chicago, Year Book Medical, 1986, pp 169-194
 8. Khoury G, Klandorf H, Brems J, Busuttil R: Pancreatic hormonal responses to hyperglycemia during orthotopic liver transplantation in man. *Transplantation* 47:891-893, 1989
 9. Dyckner T, Wester PO: Relation between potassium, magnesium and cardiac arrhythmias. *Acta Med Scand (suppl)* 647:163-177, 1981
 10. Marquez J, Martin D, Virji M, Kang YG, Warty V, Shaw B, Sassano J, Waterman P, Winter P, Pinsky M: Cardiovascular depression secondary to ionic hypocalcemia during hepatic transplantation in humans. *ANESTHESIOLOGY* 65:457-461, 1986
 11. Brown MJ, Brown DC, Murphy MB: Hypokalemia from beta₂-receptor stimulation by circulating epinephrine. *N Engl J Med* 309:1419-1421, 1983
 12. Decaux G, Soupart A, Caulhie P, Delwiche F: Potassium homeostasis in liver cirrhosis. *Arch Intern Med* 148:547, 1988

Anesthesiology
73:340-341, 1990

A New Technique for Replacing an Endobronchial Double-Lumen Tube with an Endotracheal Single-Lumen Tube

JOHN A. GATELL, M.D.,* SAMUEL M. BARST, M.D.,† DAWN P. DESIDERIO, M.D.,†
ANNE C. KOLKER, M.D.,† COREY S. SCHER, M.D.†

Although endobronchial intubation with a double-lumen tube (DLT) is both useful and safe in thoracic surgical operations,¹ the need for gradual separation from mechanical ventilation postoperatively may necessitate placement of a single-lumen endotracheal tube (SLT) before emergence from anesthesia. This maneuver may be difficult, either due to preexisting anatomic considerations or because of postoperative changes such as upper airway edema. This report describes a technique for rapidly replacing a DLT with an SLT using a flexible bronchoscope as a guide while maintaining nearly continuous ventilation.

CASE REPORT

A 70-yr-old, 45-kg woman with cancer of the mid-esophagus was scheduled for esophagogastrectomy. Her physical findings, blood chemistries, and pulmonary function tests were within normal limits. Her ECG showed sinus tachycardia at 105 beats per min with Q waves in V₁-V₂ and diffuse, nonspecific S-T segment abnormalities. Intraoperative monitors included ECG, digital pulse oximetry, left radial arterial catheter, and mass spectrometry.

While breathing oxygen and after receiving d-tubocurarine (1.5 mg iv), anesthesia was induced with sufentanil (30 µg iv) and thiopental (200 mg iv). Succinylcholine (80 mg iv) was administered to facilitate

tracheal intubation while cricoid pressure was applied by an assistant. It was not possible to visualize the glottis directly using a 3 MacIntosh laryngoscope blade despite the patient being in the "sniffing position." The difficulty in visualization of the glottis appeared to be caused by a combination of a long incisor-to-oropharynx distance, a relatively small mouth, and limited head extension. An attempt was made to use a long and narrow laryngoscope blade (a no. 3 Miller blade), but glottic visualization remained unsuccessful despite repositioning the head with slight extension of the neck.

While the lungs were ventilated with 100% oxygen *via* a mask, a no. 35 left-sided (9 mm ID), polyvinyl-chloride DLT (Mallinckrodt) was prepared by removing the stylet and passing a 4-mm diameter flexible fiberoptic bronchoscope (FFB; Olympus LF-1) through the DLT bronchial lumen. The DLT-FFB combination was then passed into the trachea, and the FFB was advanced into the left main bronchus and served as a guide for placement of the DLT. The FFB then was removed, and the Y-adapter was attached; it was possible to ventilate the lungs within 30 s from the start of the FFB-DLT intubation. Exact placement of the DLT was confirmed both by auscultation of breath sounds and by FFB examination of the bronchial lumen of the DLT *via* the tracheal lumen as described by Benumof.² General anesthesia was maintained with isoflurane (0.3-0.8 % in oxygen), sufentanil (80 µg iv), and vecuronium. The operation proceeded uneventfully with the right lung deflated when surgically necessary.

At the conclusion of surgery, bilateral lung inflation was reinstituted successfully. It was decided, however, that the lungs should be mechanically ventilated in the Post Anesthesia Care Unit. Because of the previous difficulty during direct laryngoscopy, uncertainty regarding the patient's upper airway anatomy, and the possible development of postoperative laryngeal edema, it was felt that changing from the DLT to an SLT should be performed under FFB guidance.

After assuring that the patient was completely paralyzed, both the tracheal and bronchial cuffs of the DLT were deflated, and the DLT was withdrawn until the bronchial lumen was above the level of the carina. The tracheal lumen adapter was cross-clamped, and bilateral ventilation was maintained *via* the bronchial lumen. With the tracheal lumen now isolated, a no. 10 scalpel was used to create a 5×5-mm opening in the lateral wall of the tracheal lumen distal to the reinforced area connecting the bronchial and tracheal lumina. A 25-cm long, 7-mm OD SLT was advanced over the FFB until the 15-mm adapter

* Fellow of Clinical Anesthesia and Research.

† Assistant Professor of Anesthesiology.

Received from the Department of Anesthesiology and Critical Care Medicine, Memorial Sloan-Kettering Cancer Center and Cornell University Medical College, New York, New York. Accepted for publication March 6, 1990.

Address reprint requests to Dr. Desiderio: Department of Anesthesiology and Critical Care Medicine, Memorial Sloan-Kettering Cancer Center, Room C-302, 1275 York Avenue, New York, New York 10021.

Key words: Anesthesia: thoracic. Anesthetic technique: endobronchial intubation; tracheal intubation. Equipment: endobronchial tube; endotracheal tube; flexible fiberoptic bronchoscope.

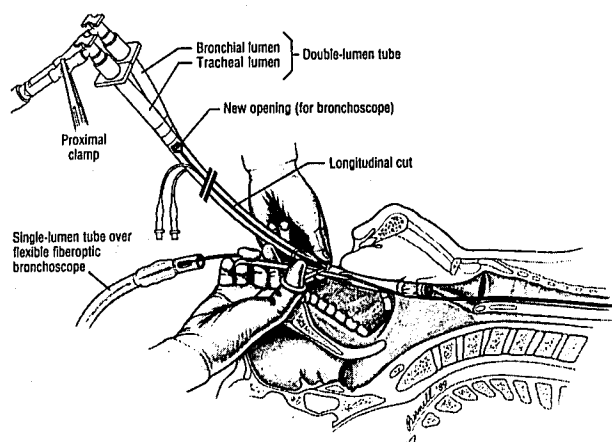


FIG. 1. Diagrammatic representation of fiberoptic bronchoscope passed through tracheal lumen of the endobronchial tube and acting as guide for single lumen tube. The bronchial lumen of the endobronchial tube remains in close proximity to the glottic inlet, permitting ventilation of the lungs while the tube's tracheal lumen is freed from the bronchoscope.

was abutting the handle of the FFB. The SLT-FFB combination was then inserted into the tracheal lumen of the DLT through the newly created opening and advanced until the tracheal mucosa could be visualized. The new opening in the DLT was extended distally with a pair of scissors. The DLT was withdrawn while being cut longitudinally until the opening of the tracheal lumen was out of the mouth. At this time ventilation was maintained *via* the bronchial lumen of the DLT, which was resting in the oropharynx (fig. 1). Once the FFB was freed from the tracheal lumen of the DLT, the SLT was then passed over the FFB and positioned in the trachea. Ventilation was then instituted *via* the SLT. Hemoglobin oxygen saturation by finger pulse oximetry never decreased below 98% during the endobronchial-endotracheal tube exchange. It was then possible to transfer the patient to the Post Anesthesia Care Unit where separation from mechanical ventilation was successfully performed over the next 8 h.

DISCUSSION

The advantage of the described technique is that an SLT can be exchanged for a DLT while maintaining positive-pressure ventilation and access to the trachea. Although a variety of techniques have been described for exchanging single-lumen endotracheal tubes using guides such as polyethylene tubing³ or a commercially available endotracheal tube introducer,⁴ these procedures lack the direct visualization afforded by a FFB. Rosenbaum *et al.*⁵ described the use of the FFB for replacing one SLT with another by passing the FFB into the trachea alongside the original SLT and then placing a new SLT after removing the original SLT. When a DLT is in use, however, it is not always possible to place an FFB in the trachea adjacent to the DLT because the entire tracheal lumen may be occupied by the DLT. More recently, Hudes *et al.*⁶ described a technique to replace a malfunctioning SLT by creating an opening in the old SLT for introduction of a new SLT over an FFB under direct visualization. The

procedure we describe is a modification of this technique, with the important addition that positive-pressure ventilation can be maintained almost continuously while exchanging a DLT for a new SLT.

It is important to emphasize that the tracheal lumen of the DLT should be used to guide the FFB. From previous experience, we have found that insertion of the FFB into the bronchial lumen results in loss of the ability to provide positive-pressure ventilation during the time that the FFB was being freed from the last few centimeters of the DLT. In this situation, the tracheal lumen is out of the mouth and ventilation is interrupted for an unnecessarily protracted period of time. By contrast, the technique described in this report for exchange of a DLT for an SLT makes it possible to continuously ventilate both lungs *via* the bronchial lumen while the FFB is freed from the tracheal lumen of the DLT.

The only problem we have experienced with the exchange of a DLT for an SLT is difficulty in cutting the polyvinyl-chloride DLT. A large pair of sharp scissors and considerable physical force are necessary. An assistant should also be present to manually ventilate the lungs and monitor vital signs during exchange of airways. Finally, we recommend application of a silicone lubricant to the FFB surface before placing the SLT. This affords easy passage of the FFB into the tracheal lumen of the DLT, smooth separation of the split DLT from the FFB, and easy passage of the new SLT over the FFB and into the trachea.

In summary, we have described safe and successful techniques using an FFB as a guide for initially intubating the trachea with a double-lumen endobronchial tube and for exchanging a double-lumen endobronchial with a single-lumen endotracheal tube in patients whose airway may be difficult to manage either because of anatomic deformity or edema. While the described technique to exchange the DLT for an SLT using the FFB as a guide is somewhat time-consuming, the advantage is that ventilation is maintained during the exchange.

REFERENCES

1. Burton NA, Watson DC, Brodsky JB, Mark JBD: Advantages of a new polyvinyl chloride double-lumen tube in thoracic surgery. *Ann Thorac Surg* 36:78-84, 1983
2. Benumof JL, Partridge BL, Salvatierra C, Keating J: Margin of safety in positioning modern double-lumen endobronchial tubes. *ANESTHESIOLOGY* 67:729-738, 1987
3. Millen JE, Glauser FL: A rapid, simple technic for changing endotracheal tubes. *Anesth Analg* 57:735-736, 1978
4. Desai SP, Fencel V: A safe technique for changing endotracheal tubes. *ANESTHESIOLOGY* 53:267, 1980
5. Rosenbaum SH, Rosenbaum LM, Cole RP, Askanazi J, Hyman AI: Use of the flexible fiberoptic bronchoscope to change endotracheal tubes in critically ill patients. *ANESTHESIOLOGY* 54: 169-170, 1981
6. Hudes ET, Fisher JA, Guslitz B: Difficult endotracheal reintubations: A simple technique. *ANESTHESIOLOGY* 64: 515-517, 1986