

Anesthesiology  
72:955, 1990

## The Ureteroscope: An Alternative to the Intubating Bronchoscope

*To the Editor:*—Fiberoptic endoscopy has become established as an important technique in numerous clinical settings in both anesthesia and critical care. Specific bronchoscopes, with optics, length, and rigidity designed for tracheal intubation and confirmation of double-lumen tube placement have been developed for the practice of anesthesia. Many small hospitals may not have the funds to purchase these special scopes. Larger hospitals may need multiple scopes. In our institution, we had ordered an intubating bronchoscope that had not arrived and we were looking for an alternative scope with which to check double-lumen endotracheal tube placement. We discovered a seldom-used ureteroscope that served our purposes admirably both for difficult intubations and evaluation of endotracheal tubes *in situ*. The comparison of specifications for the ureteroscope with the intubating bronchoscope are seen in table 1. The fiberoptics are equivalent in field of view, outer diameter, suction channel, and depth of field. The ureteroscope has more tip deflection upward by 40° and less downward by 20° but these factors in our experience did not appreciably alter its function as compared with the bronchoscope. The ureteroscope is also 10.5 cm longer than the bronchoscope that was also no disadvantage. However, the fiberoptic intubating bronchoscope has an adaptation on the suction instrument channel for intermittent suction that is not present on the ureteroscope suction instrument channel. We remedied this by cutting an elliptical hole in standard 3/16-inch surgical connecting tube for intermittent suction by digital occlusion (fig. 1).

Although an ureteroscope costs more than an intubating bronchoscope, if one is on hand it may be useful as an alternative intubating bronchoscope in these days of shrinking medical budgets. It would not be the first time that we have borrowed from our colleagues in urology. In 1912, Elsberg recommended "an ordinary silk woven urethral catheter . . . (that) can be procured everywhere"<sup>1</sup> for common use as an endotracheal tube.

TABLE 1. Comparison of Olympus Fiberscopes: Ureterofiberscope (URF-P) and Intubating Bronchoscope (6F-1)

	URF-P	LF-1
Field of view	75°	75°
Direction of view	Forward	Forward
Outer diameter	3.6 mm	4 mm
Depth of field	3–50 mm	3–50 mm
Tip deflection upward	160°	120°
Tip deflection downward	100°	120°
Working length	70.5 cm	60 cm
Suction/instrument channel	1.2 mm	1.2 mm

DORIS K. COPE, M.D.  
Chief of Anesthesiology  
Veteran's Administration Medical Center  
Biloxi, Mississippi 39530  
Assistant Professor of Anesthesiology  
University of South Alabama Medical Center  
2451 Fillingim Street  
Mobile, Alabama 36617

### REFERENCE

1. Elsberg CA. Intratracheal insufflation anesthesia, its value in thoracic and in general surgery. *NY State J Med* 12:525–529, 1912

(Accepted for publication February 23, 1990.)

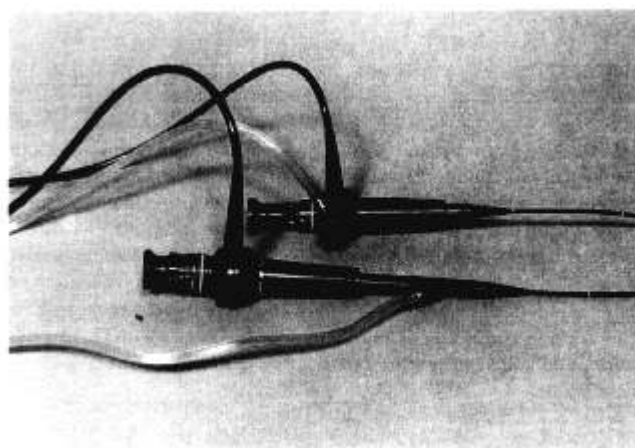


FIG. 1. Suction adaptation of the ureteroscope below by cutting a hole in ordinary 3/16-inch surgical connecting tubing for intermittent digital occlusion. This may be a slightly less convenient location for the suction port than on the intubating scope above.

Anesthesiology  
72:955–956, 1990

## Blind Selective Bronchial Catheterization

*To the Editor:*—Recently, Rouby *et al.*<sup>1</sup> reported that insertion of a straight suction catheter through an endotracheal tube resulted in right bronchial catheterization 86%, left bronchial catheterization 11.5%, and curling of the catheter in the upper airway 2.5% in patients in an ICU.

We have developed a curved-tip catheter with a guide mark to indicate direction of curvature. The most important factor determining final location of a catheter during blind selective bronchial catheterization is the guide mark which facilitates directing the endotracheal

tube to the desired location.<sup>2-6</sup> Our technique resulted in a success rate of 89-97%<sup>2,4-6</sup> for left bronchial catheterization and 97-100% for right bronchial catheterization.<sup>2,4,5</sup> When a curved-tip catheter is not available, one can be easily constructed using a cigarette lighter; a guide mark is made using a felt tipped pen.<sup>6</sup> In addition, we also developed a device for determining location of a catheter tip in the bronchi using a stethoscope and an audible sound signal.<sup>7</sup> When our device is not available, a sound signal generator can be used alternatively.

Using our technique we have successfully treated atelectasis and pulmonary edema without the need for fiberoptic bronchoscopy.<sup>8</sup> Furthermore, our technique can be used for selective bronchoalveolar lavage.

YUKIO KUBOTA, M.D.

*Chief of Department of Anesthesia*

YOSHIRO TOYODA, M.D.

*Associate Chief of Department of Anesthesia*

HIROSHI KUBOTA, M.D.

*Staff, Department of Anesthesia*

*Osaka Kohseinenkin Hospital*

*4-2-78, Fukushima, Fukushima-Ku, Osaka, 553, Japan*

Anesthesiology  
72:956, 1990

*In Reply:*—I appreciate the interest and constructive comments of Dr. Y. Kubota and Y. Toyoda. They propose a modified technique for selective catheterization of right and left bronchi and also of bronchi of the upper lobes. Although in general the location of the catheter within the bronchial tree does not appear to be critical in the bacteriologic diagnosis of nosocomial pneumonia,<sup>1</sup> the possibility of a selective catheterization of some lung segment could be important in specific cases such as unilateral bacterial pneumonia. I agree with their proposition and will soon modify our catheter according to their recommendations.

JEAN-JACQUES ROUBY, PH.D., M.D.

*Clinical Chief, Critical Care Unit*

Anesthesiology  
72:956-957, 1990

## Use of Purified C<sub>1</sub> Esterase Inhibitor in Patients with Hereditary Angioedema

*To the Editor:*—Wall, Frank, and Hahn recently reported their experience with 25 patients with hereditary angioedema requiring surgery.<sup>1</sup> We are most surprised that use of purified C<sub>1</sub> esterase inhibitor concentrate was not suggested as prevention, especially for patients undergoing surgical procedures at high risk (dental and ENT surgery) or those requiring tracheal intubation. Its efficacy in surgery as well as for the treatment of a crisis has long been known.<sup>2-5</sup> Of course,

fresh frozen plasma (FFP) contains the missing enzyme, but it also carries all the complement proteins, especially C<sub>4</sub> and C<sub>2</sub>, which could keep a crisis going. Moreover in contrast to C<sub>1</sub> esterase inhibitor concentrate, FFP may also transmit viral diseases.

We recently had to anesthetize two patients with hereditary angioedema, both of whom received C<sub>1</sub> esterase inhibitor. Patient 1 required extensive dental surgery and patient 2 underwent removal of

## REFERENCES

1. Rouby JJ, Rossignon MD, Nicholas MH, Martin de Lassale E, Cristin S, Grosset J, Viars P: A prospective study of protected bronchoalveolar lavage in the diagnosis of nosocomial pneumonia. *ANESTHESIOLOGY* 71:679-685, 1989
2. Kubota Y, Magaribuchi T, Toyoda Y, Murakawa M, Urabe N, Asada A, Fujimori M, Ueda Y, Matsuura H: Selective bronchial suctioning in the adult using a curve-tipped catheter with a guide mark. *Crit Care Med* 10:767-769, 1982
3. Kubota Y, Toyoda Y, Kubota H, Sawada S, Ishida H, Murakawa M, Mori K, Tokuda T: Selective left bronchial suctioning in infants and children. *Crit Care Med* 14:902-903, 1986
4. Kubota Y, Toyoda Y, Kubota H, Sawada S, Asada A, Sasai S, Ueda Y, Matsuura H: Is a straight catheter necessary for selective bronchial suctioning in the adult? (letter) *Crit Care Med* 14:755-756, 1986
5. Kubota Y, Toyoda Y, Kubota H, Asada A: Selective bronchial suctioning (letter). *Chest* (in press)
6. Kubota Y, Toyoda Y, Sawada S, Murakawa M: The utility of a handmade curve-tipped catheter on selective left bronchial catheterization (letter). *Crit Care Med* 11:765-766, 1983
7. Kubota Y, Toyoda Y, Ueda Y, Fujimori M, Mori K, Okamoto T, Yasuda T, Matsuura H: Device for determining location of an endotracheal catheter tip. *Crit Care Med* 12:125-126, 1984
8. Kubota Y, Toyoda Y, Kubota H, Asada A, Sugiyama K: Treatment of atelectasis with selective bronchial suctioning: 1. Use of a curved tipped catheter with a guide mark. *Chest* (in press)

(Accepted for publication February 23, 1990.)

*Departement d'Anesthesie  
CHU Pitie-Salpetriere  
83 Boulevard de l'Hopital  
75651 Paris Cedex 13, France*

## REFERENCE

1. Johanson WG, Seidenfeld JJ, Gomez P, De Los Santos R, Coalson JJ: Bacteriologic diagnosis of nosocomial pneumonia following prolonged mechanical ventilation. *Am Rev Respir Dis* 137:259-264, 1988

(Accepted for publication February 23, 1990.)