

The Laryngeal Mask Airway in Pediatric Radiotherapy

C. R. Grebenik, F.F.A.R.C.S.,* C. Ferguson, F.F.A.R.C.S.,† A. White, F.F.A.R.C.S.‡

The use of the laryngeal mask airway, a new form of airway, is described in infants and young children receiving radiotherapy under general anesthesia. The laryngeal mask airway consists of a tube, at the distal end of which is attached an elliptically shaped cuff resembling a miniature face mask. The laryngeal mask is inserted blindly into the pharynx, and its cuff forms a low pressure seal around the larynx through which the patient can breathe spontaneously. No complications occurred during use of the laryngeal mask in 25 children who received 312 anesthetics. This experience suggests that the laryngeal mask airway has a valuable role in this situation and may contribute to the safety of anesthesia. (Key words: Anesthesia; pediatric. Equipment: laryngeal mask. Radiotherapy.)

INFANTS AND YOUNG CHILDREN undergoing radiotherapy may require anesthesia to guarantee immobility during irradiation. The frequency of treatment (daily for up to 6 weeks) dictates that the anesthetic technique should be simple, easily repeatable, and preferably avoid invasive procedures, such as tracheal intubation and venipuncture. The child must be left unattended during treatment so that a secure and patent airway must be assured.

The introduction of a new type of airway, the Brain laryngeal mask¹⁻³ (fig. 1) has radically changed our practice of anesthesia for radiotherapy in children. This airway consists of a tube at the distal end of which lies an elliptical cuff resembling a miniature face mask. The laryngeal mask is inserted blindly into the pharynx, and its cuff forms a low pressure seal around the larynx through which the patient can breathe spontaneously (fig. 2). This offers many of the advantages of tracheal intubation without repeated laryngeal trauma. The mask is made entirely of medical grade silicone and is reusable.

Methods

With institutional approval, we prospectively studied over a period of 6 months 25 consecutive children who required repeated anesthesia for radiotherapy, 312 anesthetics in total. Each child received treatment on a daily basis (excluding weekends) for the duration of radiotherapy. The children ranged in age from 3 weeks to 3 yr

and in weight from 3.5 to 20 kg. Eight children were each given 20 or more anesthetics with the laryngeal mask. The anesthetics were given by six experienced anesthetists who were familiar with the use of the laryngeal mask. The children received nothing po for 4 h preoperatively apart from 0.03 mg/kg of atropine po 1 h before treatment was due. Anesthesia was induced with an inhalational agent in nitrous oxide and oxygen. When a sufficient depth of anesthesia was achieved, judged by the onset of regular diaphragmatic respiration, the child's head was put in the customary position for intubation and the laryngeal mask inserted.

The technique of mask insertion is simple and easily learned (fig. 3). First, the cuff of the mask is deflated and well lubricated with sterile jelly. The mask is inserted with the aperture facing anteriorly and passed blindly into the pharynx with one smooth movement until resistance is felt. The mask is designed so that when its distal end reaches the base of the hypopharynx, it is correctly placed over the laryngeal inlet (it is too broad to pass into the esophagus without excessive force being used). At this point the cuff is inflated with an appropriate volume of air (table 1). The anesthetic T-piece is attached, and the correct placement of the laryngeal mask is checked by auscultation of breath sounds and observation of the movement of the reservoir bag with respiration. In most cases an unobstructed airway is achieved immediately. If the airway is partially obstructed, it is usually due to incorrect positioning of the mask or to epiglottic downfolding, and the obstruction can usually be eliminated by removing and reinserting the mask.

The number of attempts required to place the mask correctly were noted. Once the mask was in place, the tube attached to the mask was taped to the face to prevent movement. After positioning the child for treatment the correct placement of the mask was rechecked as described. At this stage the depth of anesthesia was decreased to 1 MAC equivalent because the mask is tolerated at light levels of anesthesia, provided the child is not stimulated. The children were monitored with pulse oximetry and observed during treatment using closed circuit television cameras. At the end of the procedure the laryngeal mask was left in place during recovery until protective reflexes had returned. Supplemental oxygen was given. At the onset of swallowing, the cuff of the mask was deflated and gently withdrawn from the larynx. After awakening the children were observed in the recovery area for about 20 min and given a drink before being discharged into the care of their parents.

* Senior Registrar.

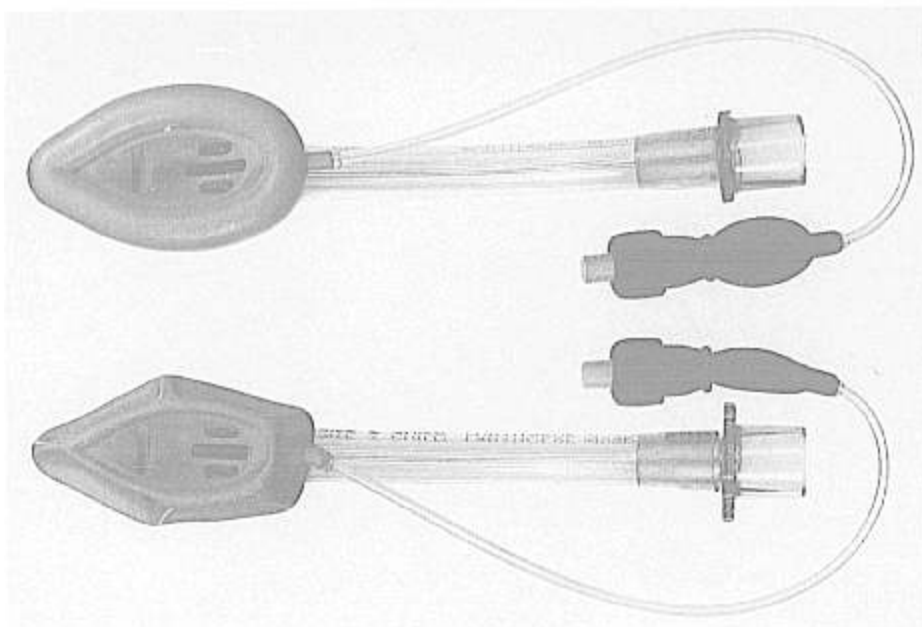
† Lecturer.

‡ Registrar.

Received from the Department of Anaesthesia, St Bartholomew's Hospital, London, United Kingdom. Accepted for publication October 25, 1989.

Address reprint requests to Dr. Grebenik: Department of Anaesthesia, St. Bartholomew's Hospital, West Smithfield, London EC1A 7BE, United Kingdom.

FIG. 1. The laryngeal mask airway with cuff inflated (*top*) and deflated for insertion (*bottom*).



Results

In our series of 312 anesthetics in 25 children there were no complications directly related to the laryngeal mask, even with daily usage over a prolonged period. The

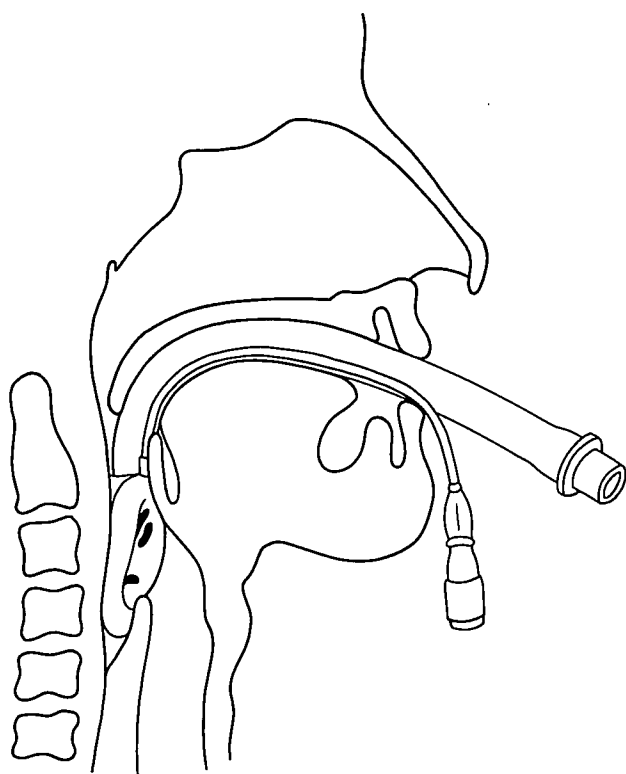


FIG. 2. The laryngeal mask in position.

incidence of sore throat is difficult to assess in infants and small children, but there were no problems with feeding or adverse comments from parents. On 23 occasions more than one attempt was needed to position the mask correctly. Difficulty with using the mask occurred twice. On one occasion the mask could not be correctly positioned despite repeated attempts. This was probably due to inexperience with the technique of mask insertion in children because the same child received eight other uneventful anesthetics with the laryngeal mask during its course of treatment. The other problem occurred in an 8-week-old baby weighing 6 kg. In this infant the size 2 laryngeal mask, although initially giving a clear airway, had a tendency to emerge from the mouth unless firmly strapped in place. It seems likely that the size 2 mask was slightly too large for this infant and the use of the size 1 (at that time not commercially available) might have avoided this problem. There was one case of laryngospasm during mask insertion by an anesthetist who attempted to insert the mask when a too light level of anesthesia was present. The choice of volatile agent was left to the anesthetists. Halothane was used on 227 occasions, enflurane on 69 occasions, and isoflurane on 16 occasions.

Discussion

A wide range of anesthetic techniques have been described for children undergoing radiotherapy.⁴⁻⁸ Despite its many disadvantages, ketamine has been frequently advocated because the airway is better preserved without support or mechanical assistance with this anesthetic agent than with any other. Until October 1988 approximately

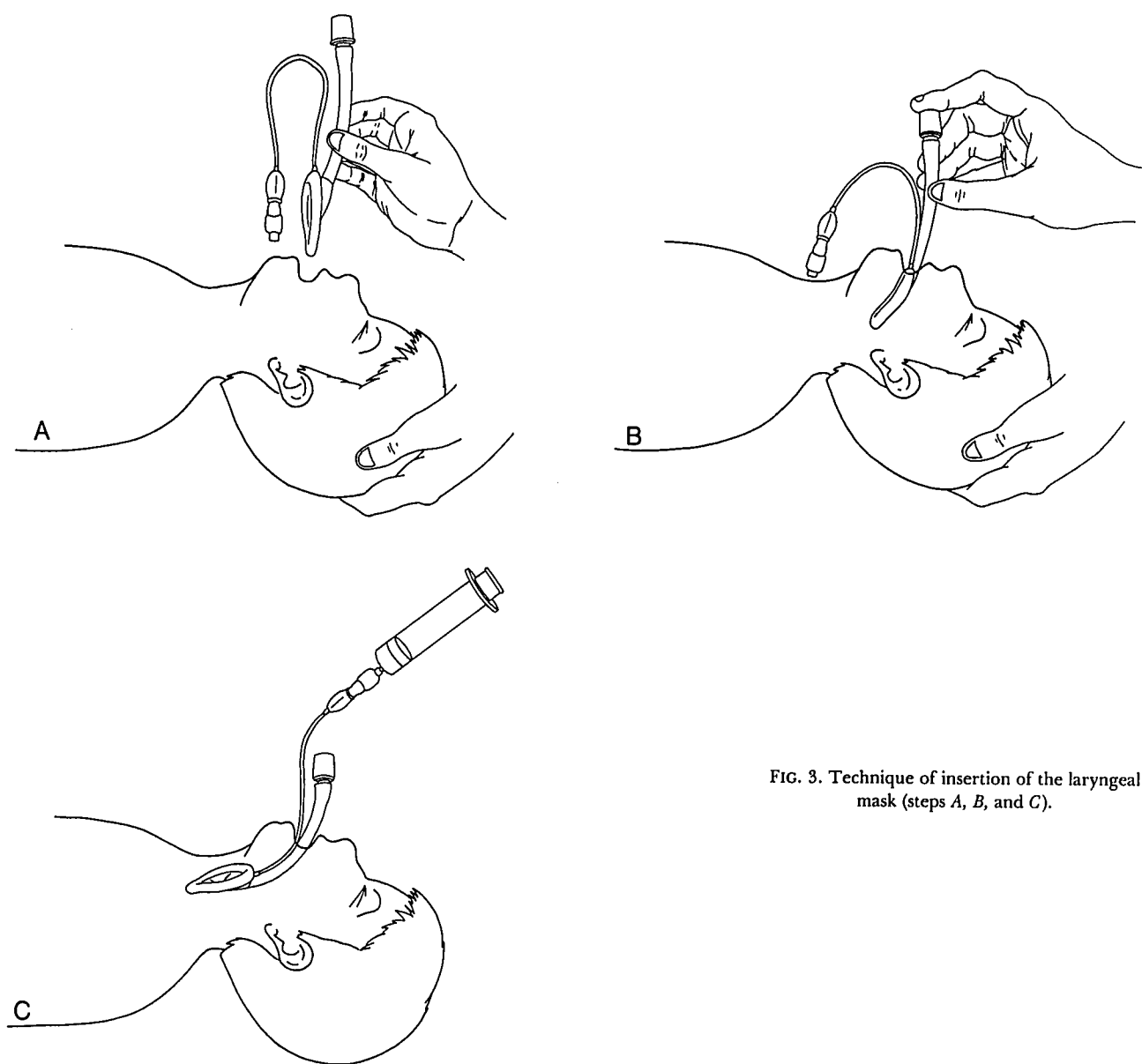


FIG. 3. Technique of insertion of the laryngeal mask (steps A, B, and C).

95% of children requiring anesthesia for radiotherapy in our hospital received intramuscular ketamine.⁹

The use of inhalational anesthesia has significant advantages over ketamine. Induction is rapid and usually well tolerated and, when performed on a daily basis, soon becomes a routine for parents and children. Anesthetic

depth can be easily controlled and recovery is fast and complete. However, as with ketamine, the most common complications are related to problems with airway patency,^{5,6,8} and without tracheal intubation an unobstructed airway can be difficult to maintain. Methods of mechanical airway support have been described to hold the head extended and the chin forward during anesthesia,^{4,10} but these are at best a compromise. Problems with the maintenance of airway patency are exacerbated by the demands of positioning for radiotherapy. Treatment is frequently performed with the child supine, and only rarely in the prone and lateral positions. In our hospital a new lens sparing technique of radiotherapy is used for children with retinoblastoma.¹¹ This technique re-

TABLE 1. Sizes of Laryngeal Mask

Mask Size	Patient Size	Cuff Volume (ml)
1	Neonate-6.5 kg	2-4
2	6.5-25 kg	5-10
3	25 kg to small adult	20
4	Large adult	20-30

quires the child to be immobilized in a full head shell. The eye is located by a contact lens attached to a rigid metal arm fixed to the applicator on the linear accelerator. Once the shell is locked, the child's head is rigidly confined and access is severely restricted. With the child in the head shell it is frequently difficult to maintain a clear airway using insufflation or a modified airway technique. The use of the laryngeal mask has simplified anesthesia for these children and, in our view, contributes greatly to the safety of the procedure. No child in the series has had any anomaly of the upper respiratory tract that might have made airway maintenance difficult, but the laryngeal mask has been successfully used in cases of difficult intubation^{12,13} and may be of particular value in such cases.

In conclusion, the repeated use and remote nature of anesthesia for pediatric radiotherapy creates a number of problems. The use of the laryngeal mask airway is a novel solution and represents a major advance in safe anesthesia for these children.

The authors wish to thank Martin Luce, Sister Louise Becker, and the staff of the Radiotherapy Department for their help.

References

1. Brain AIJ: The laryngeal mask—a new concept in airway management. *Br J Anaesth* 55:801–804, 1983
2. Brain AIJ, McGhee TD, McAteer EJ, Thomas A, Abu-Saad MAW, Bushman JA: The laryngeal mask airway—development and preliminary trials of a new type of airway. *Anaesthesia* 40:356–361, 1985
3. Brodrick PM, Webster NR, Nunn JF: The laryngeal mask airway—a study of 100 patients during spontaneous breathing. *Anaesthesia* 44:239–241, 1989
4. Glauber DT, Audenaert SM: Anesthesia for children undergoing craniospinal radiotherapy. *ANESTHESIOLOGY* 67:801–803, 1987
5. Casey WF, Price V, Smith HS: Anaesthesia and monitoring for paediatric radiotherapy. *J R Soc Med* 79:454–456, 1986
6. Brett CM, Wara WM, Hamilton WK: Anesthesia for infants during radiotherapy: An insufflation technique. *ANESTHESIOLOGY* 64:402–405, 1986
7. Cronin MM, Bousfield JD, Hewett EB, McLellan I, Boulton TB: Ketamine anaesthesia for radiotherapy in small children. *Anaesthesia* 27:135–142, 1972
8. Edge WG, Morgan M: Ketamine and paediatric radiotherapy. *Anaesth Intensive Care* 5:153–156, 1977
9. Braude N, Harnett AN: Anesthesia for pediatric radiotherapy. *Anesthesiol Rev* 14:15–21, 1987
10. Brown CHW, Boulton TB, Crichton TC: Anaesthesia for radiotherapy—a frame for maintaining the airway. *Anaesthesia* 24:428–430, 1969
11. Harnett AN, Hungerford J, Lambert G, Hirst A, Darlinson R, Hart B, Trodd TC, Plowman PN: Modern lateral external beam (lens sparing) radiotherapy for retinoblastoma. *Ophthalmic Paediatr Genet* 8:53–61, 1987
12. Brain AIJ: Three cases of difficult intubation overcome by the laryngeal mask airway. *Anaesthesia* 40:353–355, 1985
13. Smith BL: Brain airway in anaesthesia for patients with juvenile chronic arthritis. *Anaesthesia* 43:416, 1988