

## *The Position and the State of the Larynx during General Anesthesia and Muscle Paralysis*

Murali Sivarajan, M.D.\* B. Raymond Fink, M.D.†

Based on a chance observation in two patients in whom the larynges could be visualized during direct laryngoscopy using topical anesthesia but not after general anesthesia and muscle paralysis, the authors postulated that there will be a shift in the position of the larynx with the onset of general anesthesia and muscle paralysis. To verify this the authors measured the position of larynx in lateral radiographs of necks taken in human volunteers when they were awake, and after induction of general anesthesia and muscle paralysis. The authors found that the hyoid bone and epiglottis were shifted anteriorly and the supraglottic region or the vestibule of the larynx was enlarged with the onset of general anesthesia and muscle paralysis. In addition, the larynx was also stretched longitudinally with wide separation of the vestibular and vocal folds. The authors conclude that consciousness is associated with tonic muscular activity that folds the larynx and partially closes it and that onset of general anesthesia and muscle paralysis opens the larynx wider and shifts it anteriorly, which might make visualization of the larynx during direct laryngoscopy difficult in some patients. (Key words: Anesthesia: general. Laryngoscopy: difficulty. Larynx: position; folding.)

A CHANCE CLINICAL OBSERVATION was made by one of us in two patients who had short thick necks, raising suspicion that visualization of their larynges might be difficult during direct laryngoscopy. The larynges could indeed be visualized in these two patients during direct laryngoscopy using topical anesthesia but not after induction of general anesthesia and muscle paralysis. It is known that during deep inspiration, with the downward movement of the diaphragm, the larynx also descends.<sup>1</sup> "Tracheal tug," which is the downward displacement of larynx and trachea observed during very deep stages of anesthesia, partial or inadequate recovery from muscle relaxants, and respiratory obstruction, has been linked to the downward movement of the diaphragm acting on the trachea through the lung.<sup>2</sup> On the other hand, during effort closure of the larynx, the thyroid and the cricoid cartilages move upward<sup>3</sup> as does the diaphragm. Induction of general anesthesia and muscle paralysis has been reported to produce a cephalad shift of the end-expiratory position of the diaphragm.<sup>4</sup> Because of the related movements of

diaphragm and larynx during deep inspiration and effort closure, we postulated that the larynx would shift cephalad along with the diaphragm during general anesthesia and muscle paralysis that might make visualization of the larynx during direct laryngoscopy difficult in some patients. To verify whether the onset of general anesthesia and muscle paralysis shifts the position of the larynx, we made measurements of laryngeal position in lateral radiographs taken in human volunteers when they were awake and after induction of general anesthesia and muscle paralysis.

### Methods

The subjects of the study were nine physician colleagues. Institutional permission and informed consent from each subject were obtained. After an overnight fast, subjects were studied in the morning. A Teflon® cannula was inserted into a forearm vein for administration of drugs. After topical anesthesia of the mouth, pharynx, and hypopharynx using lidocaine 4% solution, an oropharyngeal airway was inserted. With subjects in the supine position and the head resting on a pillow to provide approximately 20-degree flexion of the neck, an anesthesia mask was strapped onto the face to deliver oxygen. Constant manual support of the mandible was provided to maintain the head in extension. Lateral radiographs were taken at functional residual capacity (end-tidal expiration): when the subjects were awake; within 1 min of the loss of eyelash reflex following a sleep-dose of thiopental but with the subjects breathing spontaneously; and immediately after cessation of spontaneous respiration following succinylcholine. To ensure the same position of the head and neck during the three radiographs, the position of the x-ray tube was fixed and the alignment of the head and neck to the lighted grid projected from the x-ray tube was maintained constant. Direct laryngoscopy was then performed while the subjects were still paralyzed to ascertain the ease of visualization of the larynx. Manual ventilation was maintained until complete recovery from succinylcholine, and subjects were monitored until full recovery from anesthesia. All the experiments were performed by one investigator (MS) and the set of three radiographs from each subject was coded.

All measurements were made by the other investigator (BRF) and a colleague who were unaware of the code. Minimal distances between the mandibular ramus and the upper border of the body of hyoid (ramus to hyoid) were measured in each radiograph: between the upper border

\* Associate Professor, Department of Anesthesiology, Kasturba Medical College; and the Department of Anesthesiology, University of Washington School of Medicine.

† Professor Emeritus, Department of Anesthesiology, University of Washington School of Medicine.

Received from the Departments of Anesthesiology Kasturba Medical College Manipal, Karnataka, India; and the University of Washington School of Medicine Seattle, Washington. Accepted for publication October 8, 1989.

Address reprint requests to Dr. Sivarajan: Department of Anesthesiology, RN-10, University of Washington, Seattle, Washington 98195.

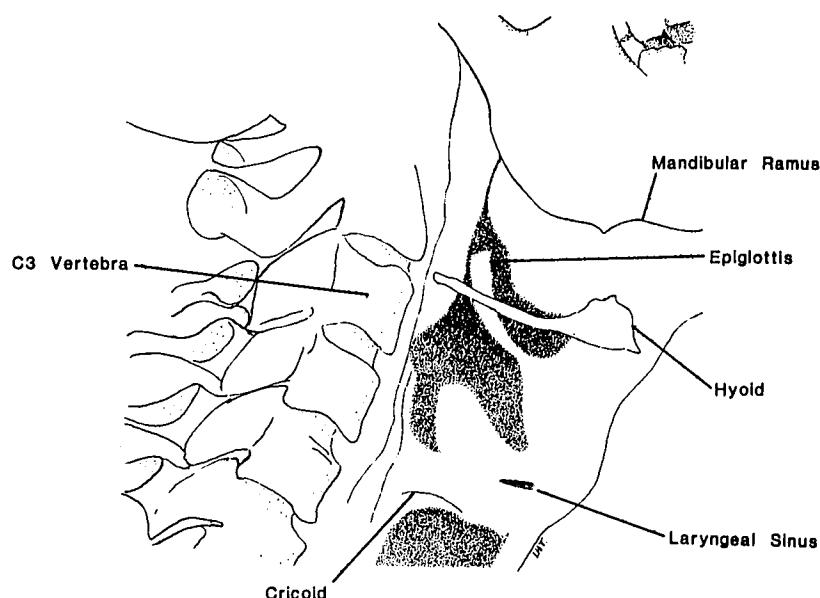


FIG. 1. Lateral view of neck drawn from the lateral radiograph in figure 2A.

of third cervical vertebra (C3) and a fixed point on the mandible (C3 to mandible); between C3 and the posterior surface of the body of hyoid (C3 to hyoid); between C3 and the tip of epiglottis (C3 to epiglottis); between the tip of epiglottis to the posterior surface of the body of hyoid (epiglottis to hyoid); and between the tip of epiglottis to calcified cricoid (epiglottis to cricoid). The maximum width of the laryngeal sinus between the vestibular and vocal folds was also measured in each radiograph (fig. 1). In two subjects the cricoid cartilages did not show any calcification to enable measurement of epiglottis to cricoid distance and the laryngeal sinuses were not in the field of the radiographs. Hence these particular measurements could be made in only seven subjects. Measurements during anesthesia with the patient breathing spontaneously and during muscle paralysis were compared with measurements during awake condition using Student's *t* test for paired observations. Correcting for multiple comparisons, changes were considered significant if *P* was less than 0.025.

### Results

With the onset of general anesthesia and muscle paralysis, there were significant increases in C3 to hyoid and C3 to epiglottic distances indicating an anterior movement of the larynx in relation to the cervical spine. The anterior movement of the epiglottis was greater than that of hyoid so that epiglottis to hyoid distance became significantly smaller (table 1). However, there was no cephalad movement of the larynx at functional residual capacity as evidenced by nonsignificant changes in the ramus to hyoid distances. The distance between C3 and mandible was

not significantly changed with anesthesia and paralysis indicating that the position of head and neck was constant during the three radiographs (table 1).

The larynx was also stretched longitudinally as shown by significant increases in epiglottis to cricoid distances with anesthesia and paralysis. This resulted in separation of vestibular and vocal folds so that the laryngeal sinus, which was narrow or closed during the awake state, became wide open with anesthesia and paralysis (table 2, fig. 2). There were also marked increases in the size of the air shadows outlining the supraglottic region or the vestibule of the larynx with the onset of anesthesia and paralysis (fig. 2). The entire glottis could be easily visualized in all nine subjects during direct laryngoscopy performed under anesthesia and muscle paralysis.

TABLE 1. Position of Larynx following Anesthesia and Paralysis (N = 9)

	Awake	Anesthetized, Breathing Spontaneously	Anesthetized, Paralyzed
C3 to hyoid distance (mm)	39.7 ± 5.8	42.4 ± 5.4	43.4 ± 6.1*
C3 to epiglottis distance (mm)	23.8 ± 2.5	27.9 ± 3.5†	28.4 ± 3.7†
Epiglottis to hyoid distance (mm)	23.4 ± 5.1	21.4 ± 4.3*	21.7 ± 4.2
Ramus to hyoid distance (mm)	22.8 ± 10.4	23.7 ± 6.6	24.6 ± 6.9
C3 to mandible distance (mm)	108.5 ± 19	109.3 ± 16.4	109.5 ± 16.7

Data are mean ± SD.

\* *P* < 0.02 when compared with awake values.

† *P* < 0.01 when compared with awake values.

TABLE 2. State of Larynx following Anesthesia and Paralysis (N = 7)

	Awake	Anesthetized, Breathing Spontaneously	Anesthetized, Paralyzed
Epiglottis to cricoid distance (mm)	46.5 ± 3.2	50.8 ± 4.0*	49.9 ± 4.6
Laryngeal sinus width (mm)	1.9 ± 2	4.6 ± 1.9†	4.7 ± 1.4†

Data are mean ± SD.

\*  $P < 0.02$  when compared with awake values.

†  $P < 0.01$  when compared with awake values.

### Discussion

To our surprise, we found that during general anesthesia and muscle paralysis the larynx was not displaced cephalad but was displaced anteriorly. This anterior displacement was unrelated to the position of the mandible which was constant during the measurements. Along with anterior displacement, the larynx was also stretched longitudinally resulting in separation of vestibular and vocal folds. Both changes could be characterized as unfolding, the anterior displacement unfolding the median thyrohyoid fold to increase dimensions of the vestibule of the larynx and the longitudinal stretch unfolding the vestibular and vocal folds that results in a wide-open glottis.<sup>1,3</sup> Similar changes are also seen during deep inspiration.<sup>1,3</sup> While the wide-open glottis during deep inspiration serves to improve conductance of the airway, a similar event during anesthesia and paralysis leaves the trachea less protected from a foreign body especially when there is no skeletal muscle activity to expel it by generating cough.

This finding suggests that consciousness is associated with tonic activity that folds the larynx to protect the trachea and that this tonic activity is abolished at the onset of general anesthesia.

Fink has described spring mechanisms in the larynx that are stressed by various laryngeal activities that help restore neutral position when the activity ceases.<sup>5</sup> An anteriorly displaced, unfolded larynx during muscle paralysis then represents the neutral position, and a folded larynx during the awake state could best be ascribed to the activity of laryngeal muscles as well as the muscles of the chest wall. The laryngeal muscle that could be implicated is the thyrohyoid muscle which, by pulling the thyroid and the hyoid toward each other, would deform the pre-epiglottic body causing it to displace the epiglottis posteriorly. Abolition of the activity of this muscle would result in restitution of epiglottis and hyoid to a more anterior position resulting in unfolding of the median thyrohyoid fold.

A cephalad shift in the end-expiratory position of the diaphragm during anesthesia and paralysis reported by Froese and Bryan,<sup>4</sup> upon which we based our original hypothesis, has recently been questioned by Kraye *et al.*<sup>6</sup> While the contribution of the diaphragmatic shifts to the reduction in functional residual capacity during anesthesia and paralysis needs to be clarified, there is clear evidence that the outward recoil of the chest wall is decreased during anesthesia and paralysis perhaps due to abolition of tonic activity of the muscles of chest wall.<sup>7</sup> The opposing inward recoil of the lung then shifts the lung and the thoracic cavity volume to a new equilibrium that results in a smaller functional residual capacity during anesthesia.<sup>7,8</sup> The same recoil forces of the lung acting through

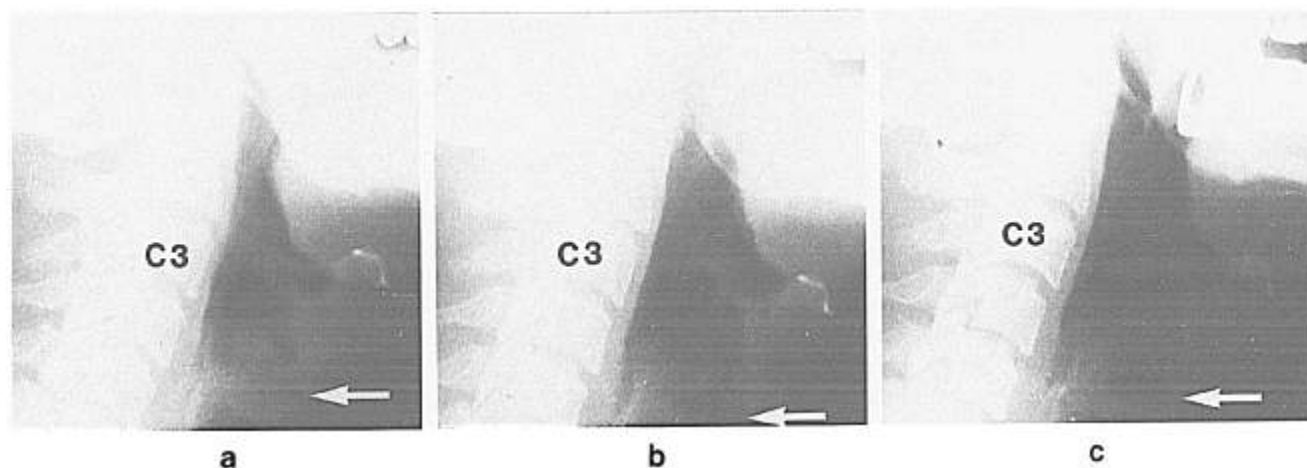


FIG. 2. Lateral radiographs of neck from one subject taken at functional residual capacity when the subject was awake (a), within 1 min of the loss of eyelash reflex following a sleep-dose of thiopental but breathing spontaneously, (b) and immediately after cessation of spontaneous respiration following succinylcholine (c). C3 is the third cervical vertebra. The arrow points to the laryngeal sinus. Note marked increases in the sizes of the air shadows and the laryngeal sinuses immediately after the onset of general anesthesia and muscle paralysis.

the trachea could also account for longitudinal stretch of the larynx to produce unfolding of the vestibular and vocal folds. No other laryngeal force could account for the unfolding of the vocal and vestibular folds that results in a wide-open glottis. In fact, in bilateral recurrent laryngeal nerve paralysis, which renders both the abductors and the adductors of the vocal fold inactive, the vocal folds are in midposition, partially closing the glottis and creating inspiratory stridor.<sup>9</sup> Although unfolding and widening of the laryngeal passage and the decrease in functional residual capacity occur together, they are probably not causally related. While consciousness is associated with a folded and partially closed larynx, it is unlikely that this condition has any role to play in maintaining functional residual capacity of the lung. A partially closed (or partially open) airway would offer no threshold resistance and would only increase the time constant for emptying the lung.

Nichol and Zuck have asserted that in patients with a narrow atlanto-occipital gap, bowing of the cervical spine takes place during direct laryngoscopy due to limitation of extension at the atlanto-occipital joint.<sup>10</sup> This results in anterior displacement of the larynx which, they suggest, may be a cause of difficult laryngoscopy. Although difficulty in visualizing the larynx during direct laryngoscopy is sometimes attributed to "anterior larynx," there is no other documentation of this phenomenon. Our study does not clearly establish whether the anterior shift in the larynx could lead to difficulty in visualizing the larynx during direct laryngoscopy or not. In fact, in all nine subjects, visualization of the larynx was quite easy during anesthesia and muscle paralysis. However, we did not perform direct laryngoscopy when our subjects were awake to detect any qualitative differences in the ease with which the larynx could be visualized under awake conditions. Our plan was to perform direct laryngoscopy under awake conditions only in those subjects in whom the larynx could not be visualized during anesthesia and paralysis. We were not afforded that opportunity. Our study does suggest that

the frequent clinical practice of ascertaining the ease of direct laryngoscopy under awake conditions in patients in whom we suspect difficulty and then inducing general anesthesia to perform tracheal intubation may be fraught with surprise and frustration. In those situations, it may be best to perform tracheal intubation using topical anesthesia while the patient is awake.

In summary, it appears that the onset of anesthesia results in displacement of the larynx to a more anterior position as well as a longitudinal stretch and unfolding of the larynx. Consciousness is associated with active postural folding and partial closure of the larynx that may serve to protect the trachea. Onset of anesthesia unfolds the larynx and opens it wider in the anteroposterior and longitudinal dimensions.

## References

1. Fink BR: The Human Larynx—A Functional Study. New York, Raven Press, 1975, pp 56–83
2. Fordham R: Pulmonary Ventilation, A Practice of Anesthesia, Fourth edition. Edited by Churchill-Davidson HC. Philadelphia, W. B. Saunders, 1978, pp 124–179
3. Fink BR, Demarest RJ: Laryngeal Biomechanics. Cambridge, Harvard University Press, 1978, pp 45–63
4. Froese AB, Bryan AC: Effects of anesthesia and paralysis on diaphragmatic mechanics in man. *ANESTHESIOLOGY* 41:242–255, 1974
5. Fink BR: Spring mechanisms in the human larynx. *Acta Otolaryngol* 77:295–304, 1974
6. Kraye S, Rehder K, Vettermann J, Didier PE, Ritman EL: Position and motion of the human diaphragm during anesthesia-paralysis. *ANESTHESIOLOGY* 70:891–898, 1989
7. Westbrook PR, Stubbs SE, Sessler AD, Rehder K, Hyatt RE: Effects of anesthesia and muscle paralysis on respiratory mechanics in normal man. *J Appl Physiol* 34:81–86, 1973
8. Nunn JF: Applied Respiratory Physiology, Third edition. London, Butterworths, 1987, pp 350–378
9. Last RJ: Anatomy—Regional and Applied. New York, Churchill Livingstone, 1978, pp 422–429
10. Nichol HC, Zuck D: Difficult laryngoscopy—The "anterior" larynx and the atlanto-occipital gap. *Br J Anaesth* 55:141–144, 1983