

## Cardiopulmonary Resuscitation Without a Ventilator Using a Novel Endotracheal Tube in a Human

*To the Editor:*—We have previously reported that in animals, cardiopulmonary resuscitation (CPR) can be performed efficiently without a ventilator using a modified endotracheal tube and a constant insufflation of oxygen.<sup>1</sup> In the wall of this tube, small capillaries have been molded by extrusion, allowing the delivery of high-velocity microjets near the distal tracheal end of the tube (Synthelabo, Patent Boussignac/Labrunne, France). The inlet of the capillaries is located at the proximal end of the tube (fig. 1). Injecting oxygen *via* these capillaries enhances gas transport toward the alveoli and maintains a constant positive pressure in the lungs. This results from air entrainment through the central lumen of the endotracheal tube.<sup>2</sup> We also have shown that constant flow insufflation (CFI) of oxygen using this tube maintains adequate oxygenation without adverse effects to patients in whom the trachea is intubated with the modified tube which in turn is disconnected from the ventilator.<sup>3</sup> In animals, when CFI was used during CPR,<sup>1</sup> external chest compression had an expiratory effect because the tube remained open to the atmosphere. During chest relaxation, CFI resulted in inflation of the lungs. The animal study also demonstrated that the standard CPR and the CPR-CFI method had a similar ventilatory and hemodynamic efficacy but suggested that cerebral blood flow could be greater with CPR-CFI than with the conventional CPR technique.<sup>1</sup> We report the observation of the first patient treated by this new technique during CPR.

A 65-yr-old man was referred to our cardiac catheterization laboratory with a history of unstable angina. Baseline coronary angiography showed a total occlusion of the proximal left anterior descending (LAD) artery and a 75% stenosis of the right coronary artery. A few minutes after the end of the procedure, the patient complained of chest pain and became unconscious. Cardiac arrest was recognized by pulselessness and the trachea was intubated with an 8-mm internal diameter endotracheal tube allowing delivery of CFI while external chest compression was performed. As a rapid and simple way to ventilate the lungs, oxygen was administered through the capillaries of the tube at a flow rate of 10 l/min (which generates approximately 10 cm H<sub>2</sub>O of alveolar pressure) and the tube was left open to the atmosphere. Consequently, CFI was the sole method of ventilation. Immediate efficacy of CPR was assessed by normal pupillary reactivity. Intravascular measurement of systolic and diastolic aortic pressure were 70 and 45 mmHg, respectively; arterial blood gases showed a pH of 7.55, an oxygen tension and saturation of 227 mmHg and 100%, and a carbon dioxide tension and a bicarbonate concentration of 33 mmHg and 30

mmol/l, respectively. Repeat coronary angiography could be performed while CPR-CFI was being maintained. A total occlusion of the proximal left circumflex artery was noticed in addition to the previously observed occlusion of the LAD. No spontaneous cardiac electrical activity reappeared despite administration of vasoactive drugs and the patient was transferred to the operating room for coronary bypass surgery. Arterial blood gases remained stable. CPR was then continued with controlled mechanical ventilation after 55 min of CFI. Clinical examination still revealed normal pupillary reactivity. Therefore, heart transplantation was considered after failure of the bypass surgery to restore adequate left ventricular function. Electroencephalogram showed a satisfactory brain function with bilateral symmetric activity. However, due to nonmedical contraindications, transplantation was not performed and extracorporeal bypass was ended.

In this case, CPR was performed using CFI as a ventilatory mode over 1 h with both satisfactory ventilatory and hemodynamic data. Although we initially used this technique because it was immediately available, we elected to continue it since diastolic aortic pressure was high and the pupillary reactivity was normal. Indeed, previous experimental studies in dogs have shown that maintenance of aortic diastolic pressure above a critical level (30 mmHg) is crucial for restoring adequate cardiorespiratory function during cardiac arrest.<sup>4</sup> Fluid loading and epinephrine were administered during this period and also could account for the efficacy of CPR. This case suggests that CFI, which is a very simple method to ensure normal gas exchange, can be used as an alternative method of ventilation during CPR in humans.

LAURENT BROCHARD  
GEORGES BOUSSIGNAC  
JEAN-LUC DUBOIS RANDÉ  
ALAIN HARF  
CATHERINE BERTRAND  
HERBERT GESCHWIND  
*Cardiac Catheterization Laboratory  
Medical Intensive Care Unit  
Department of Cardiology  
INSERM U 296  
University Hospital Henri Mondor  
94010 CRETEIL, France*

### REFERENCES

1. Brochard L, Adnot S, Bertrand C, Boussignac G, Harf A: Ventilatory and hemodynamic effects of cardiopulmonary resuscitation (CPR) during constant flow ventilation (CFV) (abstract). *Am Rev Respir Dis* 137:A295, 1988
2. Isabey D, Boussignac G, Harf A: Effect of air entrainment on airway pressure during endotracheal gas injection. *J Appl Physiol* (in press)
3. Mion G, Brochard L, Mancebo J, Boussignac G, Isabey D, Harf A, Lemaire F: Prevention of arterial oxygen desaturation induced by endotracheal suctioning using constant flow insufflation (abstract). *ANESTHESIOLOGY* 69:A179, 1988
4. Sanders AB, Ewy GA, Taft TV: Prognostic and therapeutic importance of the aortic diastolic pressure in resuscitation from cardiac arrest. *Crit Care* 12:871-878, 1984

(Accepted for publication September 20, 1989.)

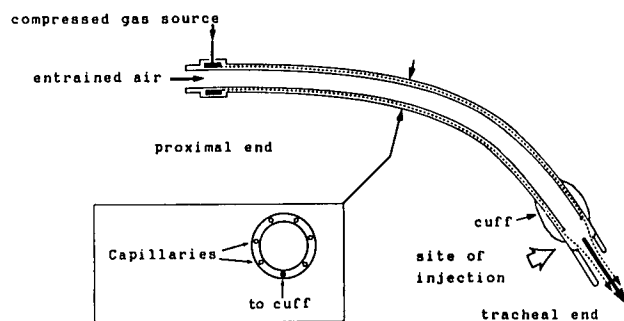


FIG. 1: Diagram of the endotracheal tube allowing constant flow insufflation. (Reproduced with permission from *J Appl Physiol* 67(2):771-779, 1989.)