

Renograffin injected into the bony cyst demonstrated a communication between the needles. The surgeon also injected 60 mg of methylprednisone in 1½ ml of normal saline into the cyst through the distal needle and removed the needles. The remainder of the surgical course was unremarkable. There were no neurological or other sequelae postoperatively.

#### DISCUSSION

Drinker, *et al.*<sup>1</sup> in 1922 first described the circulation in the mammalian bone marrow. Blood from the bone marrow passes to the noncollapsible medullary venous channels, to emissary veins, and then into the general circulation. In 1934, Josefson<sup>2</sup> described intraosseal injections as a new technique for injections of liver preparations as treatment for pernicious anemia. Currently intraosseous infusion is limited mostly to pediatric emergency situations. We believe that in this patient air passed from the needle(s) to the systemic circulation in a pathway similar to that taken by intraosseously injected fluid. It resulted from positive pressure injection rather than from negative pressure aspiration, thus accounting for its brief self-limiting episode as soon as the cause was removed.

At the onset of surgery, there was no reason to believe that this patient was at risk for venous air embolism. The most sensitive monitor to detect venous air embolism appears to be the Doppler ultrasonic monitor. It may be capable of detecting air bubbles as small as 0.12 ml.<sup>3</sup> However, our case illustrates that even less sensitive monitors can be of great help in the intraoperative diagnosis of air embolism. The capnograph will show a decrease in the end tidal CO<sub>2</sub>. The heart sounds will become metallic,

resonant, and then drum-like. A systolic murmur may precede the grinding mill-wheel murmur.

As soon as air embolism is suspected or detected the surgeon must be informed. In our case, the outcome might have been disastrous without an early response. Much more air could have been forced in the circulation. While further air entry is being stopped, additional measures should include discontinuation of N<sub>2</sub>O, ventilation with oxygen, and use of vasopressors or antiarrhythmic drugs, if necessary, to maintain hemodynamic stability. Positive intrathoracic pressure, position change of the patient, and aspiration from the central venous catheter, if present, should also be considered.

In summary, this case describes venous air embolism in a child caused by intraoperative placement of needles into a femoral bone cyst and injection of air into the cyst in an effort to aspirate fluid from the cyst. The occurrence of this unlikely intraoperative complication was diagnosed by routine monitoring alone, using capnography, pulse oximetry, ECG, blood pressure cuff, and auscultation of the heart and breath sounds.

#### REFERENCES

1. Drinker CK, Drinker KR, Lund CC: The circulation in the mammalian bone marrow. *Am J Physiol* 62:1-92, 1922
2. Josefson A: A new method of treatment—Intraosseal injections. *Acta Med Scan* 81:550-564, 1934
3. Maroon JC, Goodman SM, Horner TG, Campbell RL: Detection of minute venous air emboli with ultrasound. *Surg Gynecol Obstet* 127:1236-1238, 1968

### Juvenile Hyaline Fibromatosis: Anesthetic Management

GLENN C. VAUGHN, M.D.,\* RICHARD F. KAPLAN, M.D.,† STEVEN TIECHE, M.D.,\* JOHN B. DOWNS, M.D.‡

Juvenile hyaline fibromatosis (JHF) is a rare autosomal recessive disease with incomplete penetrance.<sup>1</sup> Clinical characteristics of affected individuals include multiple

subcutaneous nodules, flexion contractures of large and small joints, hypertrophic gingiva, and radiolucent destruction of the humerus and femur.<sup>1-3</sup> Difficulty with intubation of the trachea may be caused by gingival hypertrophy and temporomandibular joint and cervical spine contractures.

#### CASE REPORT

A 13-month-old 7-kg female with JHF was scheduled to have a Nissen fundoplication performed. The prenatal course was uneventful and her birthweight was 6 lb 7 oz. She appeared normal until early in her fifth month when flexion contractures of her upper and lower extremities and gingival hypertrophy were noted. Six months later she was hospitalized with failure to thrive and postprandial vomiting of several

\* Resident in Anesthesiology.

† Associate Professor of Anesthesiology.

‡ Professor and Chairman of Anesthesiology.

Received from the Department of Anesthesiology, University of South Florida College of Medicine, Box 59, 12901 Bruce B. Downs Blvd., Tampa, Florida 33612-4799. Accepted for publication August 16, 1989.

Address reprint requests to Dr. Kaplan.

Key words: Anesthesia, pediatric; pediatric airway. Fiberoptic bronchoscopy. Juvenile hyaline fibromatosis.

weeks duration. There was no history of heart failure, frequent upper respiratory tract infections, diarrhea, or renal disease.

The child was small for her age weighing 7 kg. She had multiple, freely moveable, subcutaneous scalp nodules, marked gingival hyperplasia, and contractures of the temporomandibular joint that hindered examination of her mouth. Her head was fixed in a neutral position, due to limited flexion and extension of the neck. Examination of the chest revealed no abnormalities. Her abdomen was scaphoid and muscular tone appeared normal. All extremities had flexion contractures, were stiff, and markedly limited in range of motion. Biopsies of her left ear and gingiva were performed under local anesthesia and confirmed the diagnosis of JHF. Gastroesophageal reflux was confirmed radiographically following a barium study; she was scheduled for a fundoplication to prevent aspiration.

The child was not fed for 6 h prior to the operation. She received ranitidine 1.25 mg/kg through a jejunal feeding tube and metoclopramide 0.2 mg/kg iv prior to the procedure. Sodium citrate 15 ml was administered orally immediately preoperatively. Electrocardiogram, blood pressure, and oxyhemoglobin saturation ( $SpO_2$ ) were monitored. A transtracheal needle, a rigid bronchoscope, and surgical support for tracheostomy were immediately available. Topical cocaine 4% was placed in both nares. Supplemental oxygen, 4 l/min by oral cannula, was given as a 3.2-mm fiberoptic bronchoscope (Olympus corporation, Lake Success, NY) was passed atraumatically into the left nares. The nasopharynx, oropharynx, and larynx were free of fibromas. The vocal cords were easily visualized and moved without limitation. One cc of Lidocaine 1% was sprayed through the bronchoscope onto the vocal cords to obtund laryngeal reflexes and prevent laryngospasm. An initial attempt to pass a 4-mm uncuffed endotracheal tube through the right nostril under fiberoptic visualization *via* the left nostril was unsuccessful due to an inability to anteriorly displace the tracheal tube. The endotracheal tube was withdrawn and a soft-tipped 175-cm long 0.035-inch diameter "J" Rosen wire (BARD USCI, Billerica, MA) guide wire was passed through the suction port of the bronchoscope. The wire was advanced 3–4 cm through the vocal cords (fig. 1). The bronchoscope then was carefully withdrawn over the guide wire. A 4-mm uncuffed tracheal tube (Sheridan, Argyle, NY) was then passed over the guide wire into the trachea and the wire removed (fig. 1). Auscultation of the chest and capnography confirmed tracheal placement. After induction of general anesthesia, laryngoscopy was performed with a Miller 1.0 laryngoscope blade. The epiglottis and posterior arytenoids were visualized; however, difficulty was noted in visualizing the vocal cords.

Neuromuscular blockade was monitored by stimulation of the orbicularis oculi muscle. Response to train-of-four and tetanus stimulation returned to baseline 45 min after the initial dose of vecuronium. Additional doses of vecuronium (0.03 mg/kg) were given iv every 20 min after complete recovery of the train-of-four response. Neuromuscular blockade was reversed with neostigmine 0.07 mg/kg iv and glycopyrrolate 0.01 mg/kg iv. Inhalation anesthetics were discontinued and she was taken to the recovery room with her trachea intubated and her lungs mechanically ventilated. When she was awake and alert the tracheal tube was removed.

## DISCUSSION

Juvenile hyaline fibromatosis is a rare disease with variable presentation. Although not completely elucidated, an autosomal recessive pattern of inheritance generally is assumed.<sup>2</sup> Many afflicted individuals are products of consanguineous marriages.<sup>1–3</sup> Most are of normal intelligence and live into the fourth decade. Light microscopy of biopsied lesions reveals an eosinophilic hyaline matrix surrounding well-differentiated fibroblasts.<sup>1,2</sup> Electron microscopic examination of the fibroblasts reveals enlarged granular endoplasmic reticulum and golgi bodies containing a matrix similar to the extracellular matrix.<sup>2</sup> Clinical characteristics include multiple slow-growing subcutaneous nodules, hypertrophic gingiva, flexion contractures, and radiolucent bone destructions.<sup>1–3</sup>

Although rare, systemic manifestations involving the pleura,<sup>4</sup> lung,<sup>4</sup> kidney,<sup>5</sup> and gastrointestinal<sup>6</sup> tract have been reported. Preoperative assessment should include a search for any coexisting disease. Subcutaneous nodular involvement of the hands and feet associated with flexion contractures may be disabling.<sup>3</sup> Entrapment of nerves, tendons, and arteries can produce palsies and vascular insufficiency.<sup>6</sup> The degree of gingival hyperplasia, as in our patient, can be extensive. Sucking and mastication may be impaired and malnutrition is common.<sup>2</sup>

We found it impossible to monitor neuromuscular blockade of the adductor pollicis muscle because of flexion

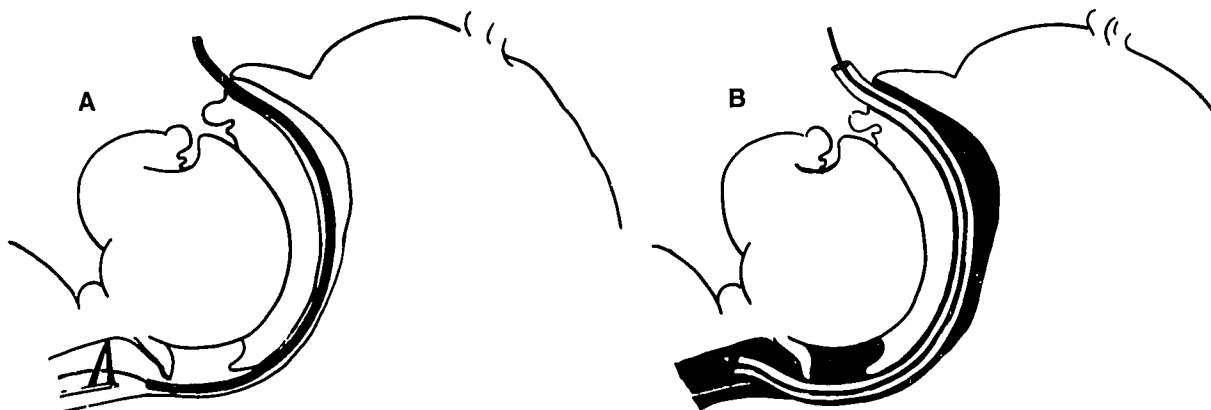


FIG. 1. A illustrates the fiberoptic scope through the nasal passages and the guide wire through the larynx. B illustrates the endotracheal tube placed over the wire and through the vocal cord. (Used with permission from Patil V, Stehling L, Zauder HL: Fiberoptic Endoscopy in Anesthesia. Chicago, Yearbook Medical Publishers Inc., 1983, p 113.)

contractures. Stimulation of the orbicularis oculi muscle can provide a reliable trend for monitoring neuromuscular paralysis, but may underestimate the degree of neuromuscular blockade of other muscles.<sup>10</sup>

This patient presented with both an airway that appeared difficult to manage and a history of gastroesophageal reflux. General anesthesia or sedation prior to endotracheal intubation might have resulted in inability to ventilate the lungs or in aspiration of gastric contents. An awake intubation with local anesthesia was planned. Physical restraint was not necessary because of marked immobility due to the patient's disease. Several reports have described unique methods to establish and maintain a patent airway in pediatric patients.<sup>8-10</sup> The need to inspect her larynx for tissue hyperplasia made tracheal intubation assisted by fiberoptic visualization ideal. A 3.2-mm pediatric fiberoptic bronchoscope can be inserted through tracheal tubes with an internal diameter of 4.5 mm and larger.<sup>9,10</sup> A 4.5-mm tracheal tube was too large for our patient and likely would have caused laryngeal trauma. We inserted a soft-tipped guide wire through the suction port of the bronchoscope to use as a guide for the tracheal tube. The technique allowed laryngeal visualization to confirm correct tube placement and could be used to pass any size endotracheal tube.<sup>10</sup>

In summary, juvenile hyaline fibromatosis is an unusual disease with profound anesthetic implications. Assessment of multiple organ involvement, uneventful tracheal intubation assisted by placing a guide wire through a pe-

diatric bronchoscope, care in positioning, and appropriate neuromuscular monitoring all led to an uneventful outcome.

#### REFERENCES

1. Fayad MN, Yacoub A, Salman S, Khudr A, DerKaloustian VM: Juvenile hyaline fibromatosis: Two new cases and a review of the literature. *Am J Med Genet* 26:123-131, 1987
2. Remberger K, Krieg T, Kunze D, Weinmann H, Hubner G: Fibromatosis hyalinica multiplex (juvenile hyaline fibromatosis). *Cancer* 56:614-624, 1985
3. Aldred M, Crawford P: Juvenile hyaline fibromatosis. *Oral Surg Oral Med Oral Pathol* 63:71-77, 1987
4. Marty-Double C, Balmes P, Mary H, Allieu Y, Pignoddel C, Targhetta R, Lesbros D, Metge L: Juvenile fibromatosis resembling aponeurotic fibroma and congenital multiple fibromatosis. *Cancer* 61:146-152, 1988
5. Teng P, Warden M, Cohn WL: Congenital generalized fibromatosis (renal and skeletal) with complete spontaneous regression. *J Pediatr* 62:748-753, 1963
6. Plaschkles J: Congenital fibromatosis: Localized and generalized forms. *J Pediatr Surg* 9:95-101, 1974
7. Caffrey RD, Warren ML, Becker KE: Neuromuscular blockade monitoring comparing the orbicularis oculi and adductor pollicis muscles. *ANESTHESIOLOGY* 65:95-97, 1986
8. Borland L, Swan D, Leff S: Difficult pediatric endotracheal intubation: A new approach to the retrograde technique. *ANESTHESIOLOGY* 55:577-578, 1981
9. Rucker R, Silva W, Worcester CC: Fiberoptic Bronchoscopic Nasotracheal Intubation in Children. *Chest* 76:56-58, 1979
10. Patil V, Stehling L, Zauder HL: *Fiberoptic Endoscopy in Anesthesia*. Chicago, Year Book Medical Publishers Inc., 1983, p 113

## Venous Air Embolism in the Recovery Room Producing Unexplained Cardiac Dysrhythmias: A Case Report

THOMAS J. LOSASSO, M.D.,\* J. DAVID MARTINO, M.D.,† DONALD A. MUZZI, M.D.\*

Venous air embolism is a well-known complication of neurosurgical procedures performed upon patients who are in the sitting position but has also been reported during head and neck surgery, total hip replacement, cesarean section, and other surgical procedures.<sup>1-3</sup> The authors are unaware of any previous report of this complication

occurring in a patient in the recovery room. We report a case of venous air embolism in the recovery room initially manifest as unexplained cardiac dysrhythmias in a patient recovering from general anesthesia for posterior cervical fusion.

#### REPORT OF A CASE

A 14-yr-old female sustained an odontoid fracture without neurologic damage in a motor vehicle accident. Despite immobilization in a halo vest since the time of injury, the fracture did not heal. Four months after sustaining the injury, the patient was admitted to the hospital for elective C1-C2 fusion. The patient's past medical history was unremarkable with the following exception: while being observed in the intensive care unit at the time of the initial injury, unifocal PVCs were noted. Antidysrhythmics were not required, and the ectopy resolved

Received from the Department of Anesthesiology, Mayo Clinic and Mayo Foundation, Rochester, Minnesota 55905. Accepted for publication August 22, 1989.

\* Instructor in Anesthesiology, Mayo Medical School.

† Assistant Professor Anesthesiology (Pediatrics), Ohio State University School of Medicine, Columbus, Ohio.

Address reprint requests to Dr. Losasso.

Key words: Embolism: air. Heart: dysrhythmia.