Anesthesiology
71:296–300, 1989

Seizures During Emergence from Anesthesia

PAUL A. MODICA, M.D.,* RENE TEMPELHOFF, M.D.†

Postoperative seizures following neurosurgical procedures are well known.[1] However, seizure activity during emergence from general anesthesia is an unusual occurrence. We report the management of such a case that occurred in an epileptic patient who underwent a craniotomy for insertion of epidural electrode recording arrays used for the extraoperative localization of his seizure focus. Continuous end-tidal carbon dioxide (ET_{CO_2}) monitoring was valuable in the management of these seizures during emergence. In addition, this report also briefly describes the anesthetic protocol we developed at our institution to facilitate cortical EEG monitoring and intraoperative identification of the sensorimotor region during epilepsy surgery.

CASE REPORT

A 25-yr-old man weighing 85 kg with an intractable complex partial seizure disorder poorly responsive to various anticonvulsant regimens was admitted to the neurosurgical service to undergo evaluation for possible surgical resection of his epileptogenic focus. At the time of admission he was having one to three seizures per week. His anticonvulsant regimen consisted of phenytoin 150 mg; carbamazepine 400 mg; valproic acid 750 mg; all three times a day, and clorazepate 7.5 mg twice a day. His past medical history and physical examination were otherwise unremarkable. All routine admission laboratory tests, including chest x-ray and electrocardiogram (ECG), were normal. Serum anticonvulsant levels were therapeutic.

On the second hospital day, he underwent a left frontotemporoparietal craniotomy and a secondary small right temporal craniotomy with insertion of epidural electrode recording arrays to define precisely the location of his epileptogenic focus. The electrodes were placed on the extradural surface of the cerebral cortex to cover the left frontal-parietal region, left orbital-frontal lobe, as well as the left and right anterior temporal lobes. In this and all cases of epilepsy surgery performed at our institution, electrocorticographic recordings were then obtained intraoperatively from each electrode array for brief (1–5 min) periods only (fig. 1). These recordings are performed to both confirm satisfactory electrode contact with the epidural surface prior to surgical closure and to record seizure activity if it occurs intraoperatively during the direct cortical electrostimulation used to identify the sensorimotor region.[2] After these recordings are completed, no additional cortical EEG monitoring is performed intraoperatively.

In order to facilitate cortical EEG monitoring and intraoperative identification of the patient's left hemispheric sensorimotor strip (including its relationship to the left frontal-parietal epidural electrodes), anesthetic management was based on a protocol developed at our institution.[2] In all cases, sedative-hypnotics are not administered preoperatively. With each patient breathing 100% oxygen (O_2) by mask, anesthesia is induced with incremental doses of fentanyl, 50 μg, iv, and droperidol, 1.25 mg, iv. Loss of response to simple commands is achieved in most patients with 8–20 $\mu g \cdot kg^{-1}$ of fentanyl and 0.08–0.2 $mg \cdot kg^{-1}$ of droperidol. As unresponsiveness occurs, either vecuronium, 0.1 $mg \cdot kg,^{-1}$ iv, or atracurium, 0.5 $mg \cdot kg,^{-1}$ iv, is administered and the trachea is intubated following moderate hyperventilation *via* mask. Using controlled ventilation to maintain ET_{CO_2} at 24–28 mmHg, anesthesia is maintained with nitrous oxide (N_2O) 60–70% in O_2, isoflurane 0.2–0.3% ET, and a fentanyl infusion titrated to a stable depth of anesthesia as determined by changes in heart rate (HR) and mean arterial blood pressure (MAP). In most cases, 4–8 $\mu g \cdot kg^{-1} \cdot h^{-1}$ of fentanyl is required, supplemented by intermittent 50 μg boluses when significant hemodynamic changes occur (*i.e.*, increases in HR and/or MAP > +15% of postinduction baseline).[3] Following intubation, neuromuscular blockade (determined by ulnar nerve stimulation) is allowed to dissipate spontaneously during craniotomy and dural exposure. Functional localization of the hand and face sensorimotor areas is then accomplished by recording the cortical sensory evoked responses associated with transcutaneous electrical stimulation of the contralateral median and facial nerves. The location of the sensorimotor region is also further confirmed by direct cortical electrostimulation to elicit movement of the contralateral hand and face.[2] When functional localization is completed, neuromuscular blockade is then reintroduced with an intermediate-acting muscle relaxant (*e.g.*, atracurium), and the fentanyl infusion is progressively decreased. Both the infusion and the isoflurane are discontinued during closure of the scalp flap.

In this case, preoperative medication included his usual anticonvulsant medications given orally. With the patient breathing 100% O_2 by mask, anesthesia was induced with fentanyl, 1000 μg, iv, and droperidol, 5 mg, iv. Tracheal intubation was facilitated with atracurium, 40 mg, iv. Maintenance of anesthesia included N_2O 70%, O_2 30%, isoflurane 0.2% ET, and fentanyl infusion. The patient was monitored with ECG, automatic blood pressure (BP) cuff, pulse oximetry, esophageal stethoscope with temperature probe, and mass spectrometry. An orogastric tube was inserted and the stomach was emptied. Controlled mechanical ventilation maintained ET_{CO_2} at 26 mmHg using a minute ventilation (MV) of 12.0 liters per minute ($l \cdot min^{-1}$). An arterial blood gas (ABG) drawn during ventilation using these settings revealed: *p*H 7.53; p_{CO_2} 28 mmHg; p_{O_2} 185 mmHg; HCO_3 24.3 $mEg \cdot l^{-1}$. Throughout the first 9 h of anesthesia, good cardiovascular stability was maintained with a HR of 70–80 beats per min (bpm) and a BP of 100–120/60–70 mmHg. Following completion of functional localization and the intraoperative cortical EEG recordings, atracurium, 40 mg, iv, was administered. Seizure activity was absent on all the EEG recordings obtained (fig. 1).

During closure of the muscle flap, 30 min after isoflurane discontinuation, the ET_{CO_2} and HR were noted to have slowly risen to 38 mmHg and 110 bpm, respectively (fig. 2). Thiopental, 100 mg, iv, and

* Instructor of Anesthesiology, Division of Neuroanesthesia.

† Assistant Professor of Anesthesiology and Neurological Surgery, Director of Neuroanesthesia.

Received from the Department of Anesthesiology, Division of Neuroanesthesia, Washington University School of Medicine, Box 8054, 660 S. Euclid Ave., St. Louis, Missouri 63110. Accepted for publication March 16, 1989.

Address reprint requests to Dr. Modica.

Key words: Anesthesia, emergence. Brain, seizures. Carbon dioxide, hypercapnia. Electroencephalography (EEG), cortical.

Downloaded from http://asa2.silverchair.com/anesthesiology/article-pdf/71/2/296/634806/0000542-198908000-00021.pdf by guest on 10 April 2024

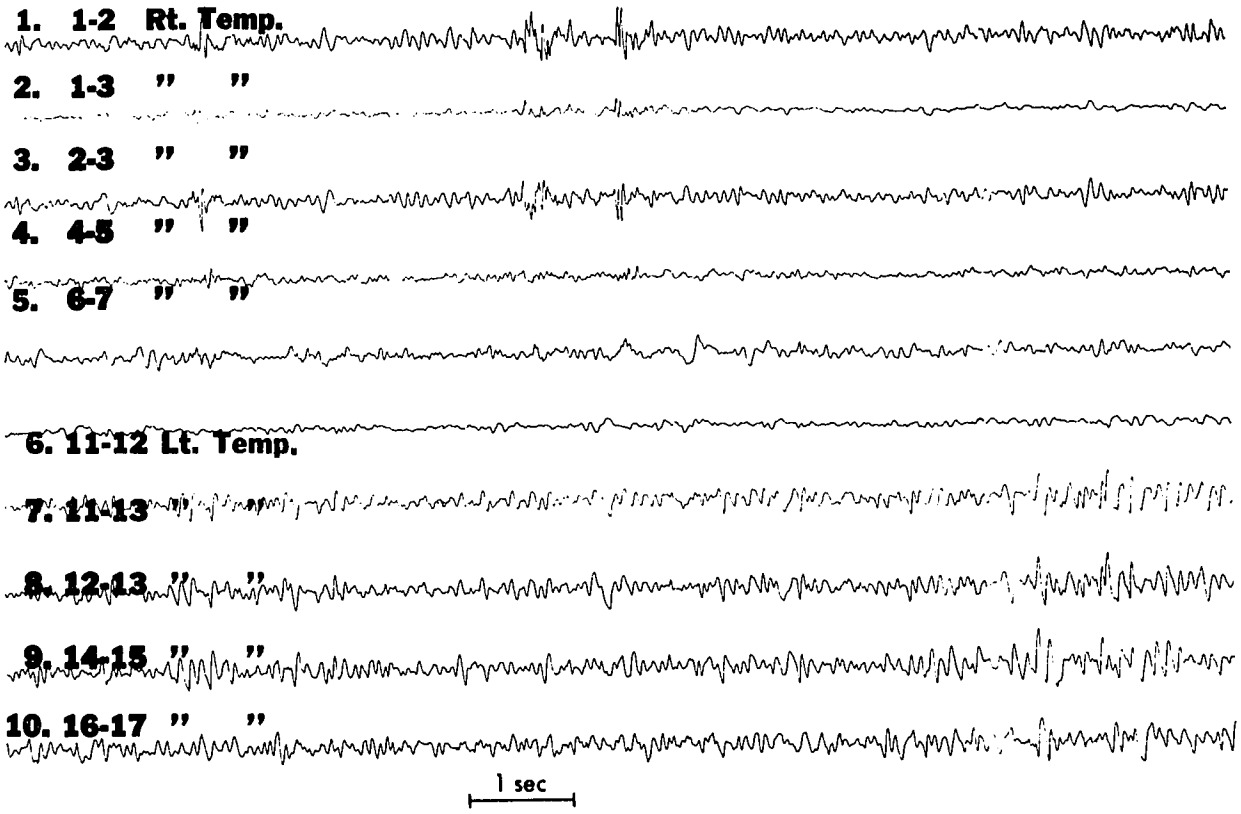

FIG. 1. Ten channel electrocorticographic recordings obtained intraoperatively from the right and left anterior temporal epidural electrodes during anesthesia with nitrous oxide 70%, fentanyl infusion, 5 $\mu g \cdot kg \cdot hr^{-1}$, and isoflurane 0.2% end-tidal. Gain is 7 μV. Each channel is recorded from an adjacent pair (*i.e.*, 1–2, 1–3, etc) of electrodes. Interelectrode distance in each pair is 1 cm. No seizure activity is noted.

fentanyl, 350 μg, iv, were given, but no change in HR or ET_{CO_2} occurred. In addition, the temperature of the patient had also increased from 35.6° C to 36.9° C over this period. Consequently, after confirming the integrity of the breathing circuit and endotracheal tube, an ABG was drawn which demonstrated: *p*H 7.46; p_{CO_2} 33 mmHg; p_{O_2} 168 mmHg; HCO_3 24.7 $mEg \cdot l^{-1}$, with a hemoglobin of 11.4 $g \cdot dl^{-1}$.

Approximately 10 min later, the fentanyl infusion was stopped. Soon thereafter, the patient began to move in response to skin suturing. Thiopental, 100 mg, iv, and fentanyl, 500 μg, iv, were given over the next 5 min. The total dose of fentanyl administered throughout the case was 6000 μg (70.6 $\mu g \cdot kg^{-1}$). The movement stopped, but the HR remained elevated at approximately 115 bpm. His temperature had increased to 37.2° C, but the ET_{CO_2} remained stable at 40 mmHg.

After placement of the head dressing, the N_2O was turned off, 100% O_2 administered, and a regular spontaneous breathing pattern was observed. The mass spectrometer indicated 0% ET-isoflurane. The patient began to exhibit spontaneous movements of all four extremities and appeared to be opening his eyes to command. During the next 5 min, the ET_{CO_2} remained at 40 mmHg with an O_2 saturation of 99%. The spirometer indicated a spontaneous MV of 12 $l \cdot min^{-1}$ (800 cc × 15). Ulnar nerve stimulation revealed sustained tetanus (100 Hz) and thus, an anticholinesterase was not administered. At this time, extubation was considered. However, during the following minute the ET_{CO_2} and HR rapidly rose to 78 mmHg and 160 bpm, respectively (fig. 2). Thiopental, 50 mg, iv, was given and mechanical ventilation (MV = 19 $l \cdot min^{-1}$) was reinstituted with 100% O_2. No arrhythmias were noted. Despite this hyperventilation, the ET_{CO_2} remained at approximately 80 mmHg during the following 5 min and the patient continued to exhibit spontaneous movements, primarily of the upper extremities. Oxygen saturation was 99%. At this point, the patient's right arm went up in a flexed position at the elbow, consistent with his usual seizure pattern. BP was 130/70 mmHg. Thiopental, 250 mg, iv, was administered and the ET_{CO_2} decreased to 40 mmHg in less than 1 min with cessation of the patient's peripheral motor activity (fig. 2). HR also fell to 110 bpm. Five minutes later, with the same ventilatory parameters, tonic activity reappeared gradually in the right arm. The ET_{CO_2} and HR again rapidly increased to 70 mmHg and 130 bpm, respectively. A second dose of thiopental, 250 mg, iv, was given and the ET_{CO_2} again rapidly decreased to 40 mmHg as the tonic activity ceased. An ABG was analyzed when the ET_{CO_2} was 65 mmHg. The results were: *p*H 7.15; p_{CO_2} 63 mmHg; p_{O_2} 466 mmHg; HCO_3 23.3 $mEg \cdot l^{-1}$. This confirmed the significance of the high ET_{CO_2} observed. Again, within 5 min, the same sequence of events reoccurred; the ET_{CO_2} reaching 65 mmHg, followed by prompt resolution with a third dose of thiopental, 250 mg, iv. Soon after, lorazepam, 4 mg, iv, was also administered, and within 5 min the patient exhibited less pronounced motor activity associated with a smaller increase in ET_{CO_2} to 50 mmHg. However, 2–3 min later, both the increase in ET_{CO_2} and the seizure activity resolved spontaneously. During the next 15 min, the controlled MV was slowly decreased to 10 $l \cdot min^{-1}$ 40% O_2 administered, and the ET_{CO_2} stabilized at 30 mmHg. An ABG revealed: *p*H 7.48; p_{CO_2} 27 mmHg; p_{O_2} 186 mmHg; HCO_3 20.6 $mEg \cdot l^{-1}$. The patient's esophageal temperature was 38.0° C and his HR ranged from 100 to 110 bpm. He was then transferred to the neurological intensive care unit where mechanical ventilation was continued using a MV of 10 $l \cdot min^{-1}$ with an inspired O_2 of 40%.

An ABG drawn 1 h later showed: *p*H 7.50; p_{CO_2} 27 mmHg; p_{O_2} 175

Downloaded from http://asa2.silverchair.com/anesthesiology/article-pdf/71/2/296/634806/0000542-198908000-00021.pdf by guest on 10 April 2024

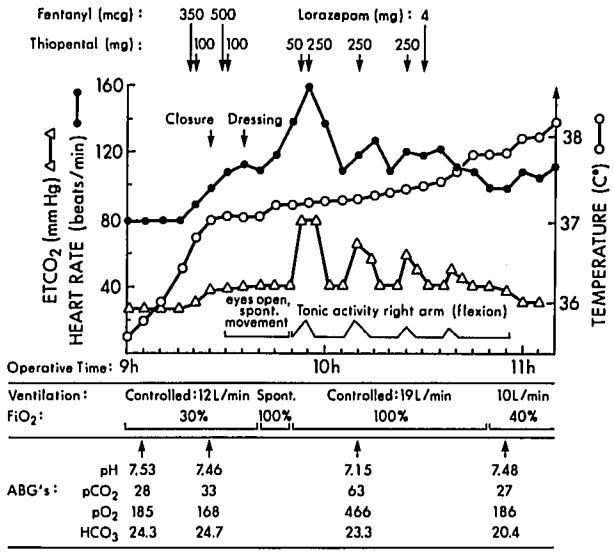

FIG. 2. Chronologic graph of end-tidal CO_2 (ET-CO_2), heart rate, esophageal temperature, minute ventilation with percent (%) inspired oxygen (FI_{O_2}), arterial blood gas results, drugs administered, and neurological examination.

mmHg; HCO_3 23.4 mEg·l^{-1}. His oral temperature was 38.8° C and HR was approximately 100 bpm. Serum electrolytes, including glucose, calcium, and magnesium, were all within normal limits. The patient was weaned from mechanical ventilation and the trachea was extubated 8 h postoperatively. No further seizures occurred that evening and no new neurological deficits were found. A room air ABG showed: *p*H 7.44; p_{CO_2} 38 mmHg; p_{O_2} 89; HCO_3 26.5 mEg·l^{-1}. His temperature had decreased to 38.0° C. The remainder of his postoperative course was uneventful. In order to facilitate extraoperative electrocorticography, his anticonvulsant medications were reduced by half by discontinuing carbamazepine and clorazepate. Only phenytoin and valproic acid were resumed using the same dosages and administration schedules prescribed preoperatively. Serum anticonvulsant levels were not reevaluated.

At our institution the epileptogenic focus is localized extraoperatively using the electrocorticographic recordings obtained from the indwelling epidural electrode arrays. In addition, the speech and/or sensorimotor areas and their relationship to the seizure focus are identified in the awake patient by stimulating and recording epidurally *via* the electrode arrays.[2] In a specially designed room, both the patient's behavior and the electrocorticogram are recorded continuously, displayed side-by-side on the split screen of a television monitor. This is necessary to determine accurately which cortical area shows the first sign of seizure activity in the moments preceding the onset of a clinical convulsion, essential information for localizing the focus. In the case presented, our patient had three clinical seizures extraoperatively that were preceded by sudden suppression of the interictal left temporal lobe recordings. The suppressed record rapidly progressed to a high voltage repetitive seizure discharge that spread first to the left frontal lobe, then to the right temporal lobe, and finally to the left frontal-parietal region.

In view of the above electrocorticographic findings, a left anterior temporal lobectomy was performed 3 days after the first craniotomy. Maintenance of anesthesia again consisted of the same agents used in the first craniotomy plus muscle relaxation provided by pancuronium. His anesthetic course during the 10-h secondary craniotomy was uneventful, including both emergence and the immediate postoperative period.

DISCUSSION

During epileptic seizures, a number of potentially serious systemic sequelae occur. Acutely, seizures can produce hypertension, tachycardia, cardiac arrhythmias, hyperthermia, respiratory and lactic acidosis.[4] Some of these systemic complications (*e.g.*, tachycardia, hypercarbia, increasing body temperature) were evident at the time of our patient's seizures during emergence. Not surprisingly, the deleterious effects of seizures result primarily from rapid increases in brain and muscle O_2 demand combined with the impairment of ventilation produced by tonic spasm.[4] This can lead to hypoxemia and severe systemic acidosis if seizure activity becomes prolonged or repetitive. Ultimately, irreversible neurological damage occurs as the brain's limited capacity to adjust its metabolism to generate increased energy fails.[5]

As illustrated in this report, in order to prevent residual neurological abnormalities, oxygenation accompanied by vigorous efforts to control the abnormal discharge are the most important parts of the treatment of repetitive seizures.[5] Throughout our patient's seizures his arterial p_{O_2} was well maintained and he recovered uneventfully. However, early during emergence the patient's condition appeared to satisfy the usual criteria for extubation, as it was difficult to distinguish his early seizure movements from those normally encountered during emergence. This is not surprising because some patients with partial epilepsy do not manifest large amounts of motor activity during their seizures. Fortunately for our patient, a period of compromised oxygenation was avoided, as the data provided by continuous ET_{CO_2} monitoring prevented an untimely extubation by revealing an acute increase in CO_2 production before motor seizure activity was clearly evident. His seizures were only briefly controlled by bolus doses of thiopental, a consequence of its rapid redistribution from the brain to lean tissue.[6] Continuing suppression of seizure activity was finally achieved with lorazepam as it does not require repetitive injections after initial control is attained.[7]

There are numerous anesthetic and nonanesthetic causes of perioperative seizures, some of which could have been involved in this case. Convulsions due to abnormalities in various serum electrolytes are well known[1]; however, all of our patient's postoperative electrolyte determinations were normal. Cerebral edema of multiple origins, such as fluid overload or after tumor resection,[1] is a common cause of perioperative seizures. It could have been a factor during this craniotomy, especially in view of the prolonged cortical stimulation and insertion of the epidural recording electrodes, a foreign body. However, the brain appeared well relaxed clinically during closure of the craniotomy. Febrile convulsions, including those due to malignant hyperthermia, have been reported dur-

Downloaded from http://asa2.silverchair.com/anesthesiology/article-pdf/71/2/296/634806/0000542-198908000-00021.pdf by guest on 10 April 2024

ing general anesthesia,[1] but usually at temperatures higher than the 37–38° C level found in this case when the seizures occurred. Furthermore, the mild hyperthermia observed in our patient was most likely a systemic effect (rather than a cause) of his seizures.

In unpremedicated epileptic[8] and nonepileptic[9] patients, 70% N_2O produced fast (15–35 Hz) EEG activity. The epileptics exhibited restlessness and hallucinations, whereas in the nonepileptics the fast EEG activity persisted for up to 1 h following N_2O discontinuation. Withdrawal convulsions have occurred in mice after removal from a 15-min exposure to 0.5–1.6 atm N_2O,[10] while humans exposed to hyperbaric (1.5 atm) N_2O exhibited excitatory phenomena during recovery.[11] Despite this evidence, it is doubtful that the seizures we observed during emergence were caused by N_2O withdrawal, as this has never been reported in humans, including those monitored with an EEG. In addition, the intermittent (albeit brief) intraoperative cortical EEG recordings did not demonstrate seizure activity during N_2O administration.

There have been several reports, all without EEG monitoring, of seizure-like motor behavior in nonepileptic patients during anesthetic induction with low (100–200 μg)[12] to moderate (2250–2500 μg)[13] doses of fentanyl. Although we did not observe any EEG epileptiform activity intraoperatively, the use of concomitant neuromuscular blockade may have prevented clinical seizure movements in our patient during anesthetic induction with fentanyl, 1000 μg, iv. Interestingly, in all previous studies performed with scalp EEG monitoring, no evidence of cortical seizure activity was demonstrated following either low (500 μg)[14] or high (150 μg/kg)[15] doses of fentanyl, including cases where seizure-like movements were observed. This suggests that these movements represent either myoclonus or exaggerated fentanyl-induced muscle rigidity.[14,15] However, one could also contend that these convulsive-like movements are instead due to fentanyl-induced subcortical seizure activity, which would not be detected with standard surface EEG electrodes. Ketamine-induced subcortical seizures have been demonstrated with depth electrode EEG in epileptics in whom simultaneous cortical recordings were unremarkable.[8] Furthermore, fentanyl-induced seizures in rats are accompanied by metabolic activation of the subcortical limbic system (hippocampus, amygdala, etc.).[16] The hippocampus is located in the medial temporal lobe and our patient had a temporal lobe seizure focus. During the 10 h of anesthesia, he received 70.6 $\mu g \cdot kg^{-1}$ of fentanyl, including 800 μg in the last half hour. This may have produced a late secondary peak in fentanyl plasma concentration,[17] which theoretically could have activated his epileptogenic focus subcortically and led to the seizures observed during emergence. If true, this would be a rare occurrence, as fentanyl-induced EEG or clinical seizure activity has never been reported either in epileptic patients or during emergence from high-dose fentanyl anesthesia.

Retrospectively, after considering the above possibilities, we believe that the patient's poorly controlled complex partial seizure disorder itself was the most likely etiology of his seizures during anesthetic emergence. However, other interacting factors were also potentially involved. Although his anticonvulsant medications have half-lives in the 10–20-h range,[18] he had not received any of these drugs for over 12 h and his stomach was emptied soon after his morning doses. Thus, we suspect some contribution from declining anticonvulsant plasma levels in the genesis of his seizures during emergence. In addition, a degree of cortical irritation due to prolonged cortical stimulation and insertion of epidural electrodes may have also contributed to the observed seizures. Finally, his seizures occurred during emergence, a period associated with light levels of anesthesia, a known method of eliciting convulsive tendencies.[19]

Our anesthetic protocol for functional localization and cortical EEG monitoring was developed for specific reasons. By omitting sedative-hypnotic drugs (including premedicants) and high concentrations of volatile anesthetic agents from anesthesia, we found during direct cortical electrostimulation that the threshold for producing movement of the contralateral hand/face was lower and also more reproducible in a small range of stimulus intensities from patient to patient. In addition, the extent of electrically excitable cortex is also much less constricted with our neuroleptanesthesia-based technique. Furthermore, by excluding drugs known to increase (*e.g.*, diazepam) or decrease (*e.g.*, methohexital) the seizure threshold in epileptics, we feel that the opportunity to obtain reliable recordings of seizures, both intraoperatively (if they occur) and especially extraoperatively, is greatly enhanced. Based on the available evidence,[20] it appears that following clinically relevant doses of atracurium, the plasma levels of laudanosine formed are of little (if any) concern during surgery for epilepsy in patients with normal renal and hepatic function.

In summary, a case of seizures that occurred during anesthetic emergence is presented. Continuous ET_{CO_2} monitoring was valuable in helping to prevent an untimely extubation before motor seizure activity was clearly evident. Thus, oxygenation was well maintained and the seizures were controlled with thiopental and lorazepam, resulting in a good postoperative neurological outcome. The most likely etiology of these seizures was the patient's own poorly controlled complex partial seizure disorder itself, although other interacting factors were also potentially involved.

References

1. Manners JM, Wills A: Post-operative convulsions: A review based on a case report. Anaesthesia 26:66–77, 1971

Downloaded from http://asa2.silverchair.com/anesthesiology/article-pdf/71/2/296/634806/0000542-198908000-00021.pdf by guest on 10 April 2024

2. Goldring S, Gregorie EM, Tempelhoff R: Surgery of epilepsy, Operative Surgery. Edited by Lansey S. London, Butterworth, 1989 (in press)
3. Tempelhoff R, Modica PA, Spitznagel E: Increased fentanyl requirements in patients receiving long-term anticonvulsant therapy (abstract). ANESTHESIOLOGY 69:A594, 1989
4. Wasterlain CG: Mortality and morbidity from serial seizures. Epilepsia 15:155–176, 1974
5. Duffy TE, Howse DC, Plum F: Cerebral energy metabolism during experimental status epilepticus. J Neurochem 24:925–934, 1975
6. Cloyd JC, Wright BD, Perrier D: Pharmacokinetic properties of thiopental in two patients treated for uncontrollable seizures. Epilepsia 20:313–318, 1979
7. Walker JE, Homan RW, Vasko MR, Crawford IL, Bell RD, Tasker WG: Lorazepam in status epilepticus. Ann Neurol 6:207–213, 1979
8. Ferrer-Allado T, Brechner VL, Dymond A, Cozen H, Crandall P: Ketamine-induced electroconvulsive phenomena in the human limbic and thalamic regions. ANESTHESIOLOGY 38:333–344, 1973
9. Yamamura T, Fukuda M, Takeya H, Goto T, Furukawa K: Fast oscillatory EEG activity induced by analgesic concentrations of nitrous oxide in man. Anesth Analg 60:283–288, 1981
10. Harper MH, Winter PM, Johnson BH, Koblin DD, Eger EI II: Withdrawal convulsions in mice following nitrous oxide. Anesth Analg 59:19–21, 1979
11. Hornbein TF, Eger EI II, Winter PM, Smith G, Weststone D, Smith KH: The minimum alveolar concentration of nitrous oxide in man. Anesth Analg 61:553–556, 1982
12. Safwat AM, Daniel D: Grand mal seizure after fentanyl administration (letter). ANESTHESIOLOGY 59:78, 1983
13. Rao TLK, Mummaneni N, El-Etr AA: Convulsions: An unusual response to intravenous fentanyl administration. Anesth Analg 61:1020–1021, 1982
14. Scott JC, Sarnquist FH: Seizure-like movements during a fentanyl infusion with absence of seizure activity in a simultaneous EEG recording. ANESTHESIOLOGY 62:812–814, 1985
15. Murkin JM, Moldenhauer CC, Hug CC Jr, Epstein CM: Absence of seizures during induction of anesthesia with high-dose fentanyl. Anesth Analg 63:489–494, 1984
16. Tommasino C, Maekawa Y, Shapiro HM, Keifer-Goodman J, Kohlenberger RW: Fentanyl-induced seizures activate subcortical brain metabolism. ANESTHESIOLOGY 60:283–290, 1984
17. McClain DA, Hug CC Jr: Intravenous fentanyl kinetics. Clin Pharmacol Ther 28:106–114, 1980
18. Rall TW, Schleifer LS: Drugs effective in the therapy of the epilepsies, The Pharmacological Basis of Therapeutics. Edited by Gilman AG, Goodman LS, Rall TW, Murad F. New York, Macmillan Publishing Co., 1985, pp 446–472
19. Lebowitz MH, Blitt CD, Dillon JB: Enflurane-induced central nervous system excitation and its relation to carbon dioxide tension. Anesth Analg 51:355–363, 1972
20. Ingram MD, Sclabassi RJ, Cook DR, Stiller L, Bennett MH: Cardiovascular and electroencephalographic effects of laudanosine in "nephrectomized" cats. Br J Anaesth 58(suppl):14S–18S, 1986

Anesthesiology
71:300–303, 1989

Coronary Angioplasty Following Acute Perioperative Myocardial Infarction

STEVEN ROTH, M.D.,* JOANNE SHAY, M.D.,† K. G. CHUA, M.D.‡

In the early hours following an acute myocardial infarction (AMI), coronary angioplasty and/or thrombolytic therapy may be indicated in an attempt to restore blood flow to ischemic myocardium.[1] Such therapy is increasingly available to hospitalized patients. Unfortunately patients who suffer an intraoperative AMI are often deprived of this form of treatment due to difficulties in detection of the infarction and problems of interdisciplinary communication. We describe a case in which intraoperative electro- and echocardiographic changes suggested AMI during noncardiac surgery, and balloon angioplasty was carried out immediately postoperatively with a successful outcome. Our purpose in presenting this case is to alert anesthesiologists to the logistics involved in carrying out angioplasty postinfarction and to summarize the importance and benefits of invasive therapy for an acute intraoperative myocardial infarction.

CASE REPORT

A 47-yr-old man with diabetes mellitus, hypertension, and a long history of smoking underwent wide excision of the left anterior knee structure and gastrocnemius flap reconstruction for a poorly differentiated sarcoma of the patella. Medications included propranolol 40 mg twice a day, chlorpropramide 500 mg daily, and enalapril 5 mg daily. He had occasional chest pain at rest. He weighed 92 kg, his lungs were clear, and no heart murmurs or S3 were audible. Arterial blood pressures of 170/90–115 were recorded preoperatively. The ECG showed inverted T waves in lead III and left ventricular hypertrophy by voltage criteria.

The morning of surgery the patient received 10 mg diazepam, 40 mg propranolol, and 5 mg enalapril orally. Preoperative arterial blood pressure was 180/105 mmHg with a heart rate of 70 bpm. The an-

* Assistant Professor, Department of Anesthesia and Critical Care.
† Resident, Department of Anesthesia and Critical Care.
‡ Associate Professor, Department of Medicine (Cardiology).

Received from the Departments of Anesthesia and Critical Care and Medicine (Cardiology), University of Chicago Medical Center, 5841 South Maryland Avenue, Box 428, Chicago, Illinois 60637. Accepted for publication March 16, 1989.

Address reprint requests to Dr. Roth.

Key words: Complications: myocardial ischemia. Monitoring: two dimensional transesophageal echocardiography.

Downloaded from http://asa2.silverchair.com/anesthesiology/article-pdf/71/2/296/634806/0000542-198908000-00021.pdf by guest on 10 April 2024