

## Cervical Sympathetic Blockade after Thoracic Intercostal Injection of Local Anesthetic

ROBERT H. BROWN, M.D.,\* PATRICIA A. TEWES, M.D.†

Intercostal nerve blockade is commonly used for intraoperative and postoperative analgesia, as well as an important diagnostic and therapeutic intervention for patients with chronic pain. The block is easy to perform and has a relatively low reported rate of complications,<sup>1</sup> including pneumothorax, subarachnoid injection, intravenous injection, and allergic drug reaction. Although Horner's Syndrome is a recognized complication of regional anesthesia involving thoracic<sup>2</sup> and even caudal<sup>3</sup> extradural procedures, to our knowledge, this is the first reported case of Horner's Syndrome following an intercostal block. This is important to anesthesiologists involved in pain management, because it suggests significant spread of local anesthetic to the sympathetic chain. This sympathetic blockade may invalidate the diagnosis of pain relief presumed secondary to individual intercostal nerve blockade.

## REPORT OF A CASE

A 47-yr-old white female was referred to our pain clinic for evaluation of her chronic abdominal pain. Her pain was described as constant and gnawing, and was located in the epigastric to left upper quadrant area. It was relieved by lying down and exacerbated by sitting and palpation of the rib tip. Intercostal blockade of the left 9th through 11th ribs was conducted on multiple occasions to confirm pain relief from temporary bupivacaine injections. On the third session, the patient was placed with her right side down, the 11th rib was palpated, and the skin was retracted cephalad. A 25-gauge, 1½-inch needle was inserted to the periosteum, at an angle of approximately 45° cephalad and 8 cm lateral to the spine. The needle was advanced off the caudal aspect of the rib as skin retraction was relieved. At the caudal aspect of the rib, the needle was inserted 3 mm further. After negative aspiration, 5 cc of 0.5% bupivacaine was injected and the needle removed. This procedure was repeated for the left 10th rib. The patient was instructed to sit up and assess her pain. She noted relief of the lower aspect of the area of pain but still had a small upper area of pain. The patient was again positioned right side down. The ninth rib was palpated and the skin retracted. A 25-gauge, 1½-inch needle was inserted to periosteum and advanced off the caudal aspect of the rib and then advanced 3 mm. After negative aspiration, 5 cc of 0.5% bupivacaine was injected and the needle removed. The patient was again instructed

to sit up and assess her pain. As she sat up, she noted a strange sensation in her left eye. She had no other signs or symptoms of thoracic sympathetic block or symptomatic complaints. Within 3 min of sitting, the patient was noted to have ptosis, miosis, and conjunctival injection of the left eye. Her chronic pain was relieved and she had a demonstrable area of anesthesia to cold and pinprick on the side in the T9 to T10 intercostal nerve distribution. The Horner's Syndrome resolved after 90 min and the patient was discharged from the clinic without further sequelae.

## DISCUSSION

Horner's Syndrome is a constellation of signs and symptoms including ptosis of the upper eye lid, enophthalmos, slight elevation of the lower lid, miosis, narrowing of the palpebral fissure, anhidrosis, and flushing of the affected side of the face. It is caused by interruption of the cervical sympathetic nerves.

Bronson *et al.*<sup>4</sup> discussed the uncertainty of the preganglionic outflow of sympathetic fibers to the pupil. He described observations of pupillary changes after direct stimulation of anterior roots during surgery. He concluded in his study of ten patients that sympathetic innervation to the eye traveled through one or more roots and between levels C8 and T4. Nunn and Slavin<sup>5</sup> studied the human intercostal space in cadavers, observing the spread of India ink to simulate spread of local anesthetic, within the intercostal space. They described the boundaries of the space. The external intercostal muscle is substantial with a clearly defined posterior intercostal membrane impermeable to India ink. The intercostalis intimal muscle is a flimsy structure composed of separate fascicles through which injected India ink passed freely to reach the subpleural space. It was then able to pass between ribs and pleura to reach the adjacent intercostal spaces, again passing through fibers of the intercostalis intimal muscle to reach the triangular compartment and the included nerves within these adjacent spaces.

They demonstrated that an injection of 3 cc easily spread medially into the paravertebral space of the same intercostal space, presumably blocking the sympathetic chain as well as several adjacent intercostal spaces. The demonstration of extensive spread of an intercostal injection by Nunn and Slavin, along with the sympathetic variability described by Bronson, could well account for our patient's complication, with a concentration of drug sufficient to block sympathetic fibers but not somatic fibers. More importantly, this case suggests that intercostal blockade may not be as accurate a diagnostic tool as pre-

\* Fellow in Regional Anesthesia and Pain Management.

† Assistant Professor in Anesthesia.

Received from the Department of Anesthesiology and Critical Care Medicine, The Johns Hopkins Medical Institutions, Baltimore, Maryland. Accepted for publication January 23, 1989.

Address reprint requests to Dr. Brown: Department of Anesthesiology and Critical Care Medicine, The Johns Hopkins Hospital, CMSC 550, 600 N. Wolfe Street, Baltimore, Maryland 21205.

Key words: Anesthetic techniques: intercostal block. Complications: stellate ganglion block. Syndromes: Horner's.

viously thought, for localization of pain to a single somatic nerve.

The authors wish to thank Carol A. Hirshman, M.D., for her review and comments.

#### REFERENCES

1. Cousins MJ, Bridenbaugh PO: Neural Blockade in Clinical Anesthesia and Management of Pain. Philadelphia, J. B. Lippincott Co., 1988, pp 515
2. Mohan J, Lloyd JW, Potter JM: Pupillary constriction following extradural analgesia. *Injury* 5:151-152, 1973
3. Mohan JJM: Pupillary constriction and ptosis following caudal epidural analgesia. *Anaesthesia* 30:769-773, 1975
4. Bronson, Ray S, Hinsey, Joseph C, Geohegan WA: Observations on the distribution of the sympathetic nerves to the pupil and upper extremity as determined by stimulation of the anterior roots in man. *Ann Surg* 4:647-655, 1943
5. Nunn JF, Slavin G: Posterior intercostal nerve block for pain relief after cholecystectomy: Anatomical basis and efficacy. *Br J Anaesth* 52:253-260, 1980

Anesthesiology  
70:1012-1015, 1989

## Myocardial Ischemia during Isoflurane Anesthesia: The Effect of Substituting Halothane

JEFFREY B. GROSS, M.D.\*

Recent laboratory<sup>1-3</sup> and clinical<sup>4-6</sup> reports suggest that isoflurane anesthesia may be associated with myocardial ischemia. However, they also imply that the risk of ischemia is essentially confined to patients with coronary artery disease who have "steal prone" coronary anatomy or who develop tachycardia during isoflurane anesthesia. Additionally, there is no evidence that isoflurane is more likely to cause ischemia than other potent inhalation anesthetics.<sup>7,8</sup> The case reported below demonstrates that isoflurane may cause electrocardiographic evidence of myocardial ischemia in patients at low risk for coronary artery disease and that these ECG changes may be reversed by replacing isoflurane with halothane.

#### REPORT OF A CASE

The patient was a 44-yr-old male, ASA physical status 1, undergoing facial reconstructive surgery. He had no history of coronary artery disease, and a normal preoperative 12-lead electrocardiogram. However, he was receiving estrogen therapy as part of a "gender reidentification" program. Routine monitoring included noninvasive BP, pulse oximetry, time-shared mass spectrometry of airway gas concentrations (SARA), and five-lead electrocardiogram (Spacelabs model 511, 3dB bandwidth = 0.2-50 Hz, standard AHA limb and V5 lead placement). Intermittently, when indicated by changes in the oscillographic trace, permanent recordings of the ECG (10 mm/mV scale) were made.

On arrival in the operating room, his BP was 140/90 mmHg, and his ECG was normal as shown in figure 1. After inducing anesthesia with thiopental, anesthesia was maintained with nitrous oxide, oxygen, and isoflurane. Succinylcholine was administered to facilitate tracheal intubation. Mechanical ventilation kept the end-tidal carbon dioxide tension between 25 and 30 mmHg.

Three hours later, because of persistent bleeding in the operative field, the surgeons requested that we deliberately decrease the patient's blood pressure. Hydralazine, 10 mg iv, transiently reduced the blood pressure from 90/60 to 80/50 mmHg, while the heart rate remained stable at 90 beats/min. Thirty minutes after he received the hydralazine, (3½ h after induction of anesthesia), the patient's blood pressure had returned to 101/58 and his heart rate was 99 beats/min; the hemoglobin oxygen saturation was 97%, and the end-tidal isoflurane

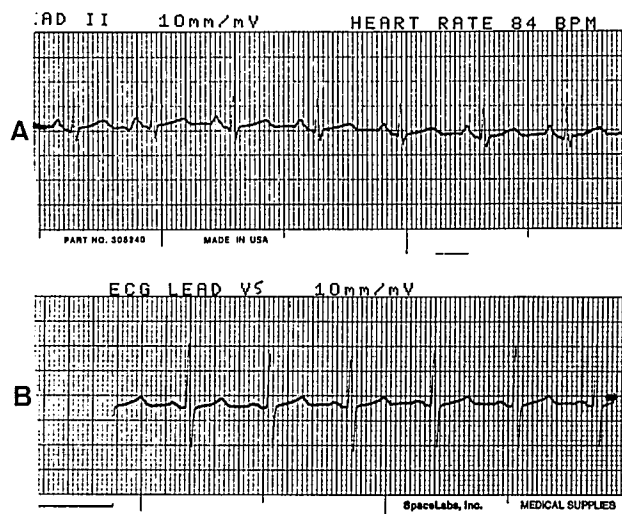


FIG. 1. Preoperative ECG (BP = 140/90 mmHg). Note that these and all subsequent ECG strips are recorded at a standard gain of 10 mm/mV. A. Lead II. B. V5.

\* Associate Professor of Anesthesia.

Received from the Departments of Anesthesia, University of Pennsylvania and Philadelphia VA Medical Center, Philadelphia, Pennsylvania.

Address reprint requests to Dr. Gross: Department of Anesthesia (112), Philadelphia VA Medical Center, University and Woodland Avenues, Philadelphia, Pennsylvania 19104.

Key words: Anesthetics, volatile: halothane; isoflurane. Heart: myocardial ischemia.