

Transtacheal Doppler: A New Procedure for Continuous Cardiac Output Measurement

Jerome H. Abrams, M.D.,* Roland E. Weber, Ph.D.,† Kenneth D. Holmen, M.D.‡

An endotracheal tube with a 5 mm diameter ultrasonic transducer incorporated into its distal end was inserted into the tracheas of six anesthetized dogs. The device provides for ultrasound measurement of aortic diameter and blood velocity in the ascending aorta to obtain cardiac outputs. Because measurements are made proximal to the origins of the aortic arch vessels, total cardiac output is obtained. Procedures for measurement of aortic diameter, aortic blood velocity, and cardiac output are discussed. The resulting data were used to empirically determine the angle of incidence of the ultrasound beam that gave the best least squares fit over a range of thermodilution cardiac outputs. For an angle of incidence of 62.3° , the relationship between cardiac output determined by thermal dilution and by transtacheal Doppler was transtacheal Doppler cardiac output = $-.69 + 1.19$ thermal dilution cardiac output. $R^2 = .82$. The results from this preliminary assessment of the feasibility of measuring cardiac output in dogs using transtacheal Doppler suggest that additional studies should be pursued. Additional issues that require investigation include confirmation of constancy of human anatomy and demonstration of lack of tracheal trauma from the Doppler equipped endotracheal tube. (Key words: Measurement technique, cardiac output: transtacheal Doppler.)

THE IMPORTANCE OF MEASURING cardiac output is well established,¹⁻³ and several methods for its determination exist. Indicator dilution techniques,⁴ which are commonly used, require invasion of the vascular system and provide intermittent measurements of cardiac output that reflect instantaneous conditions of preload, afterload, or inotropy. The direct Fick method⁵ is best used in awake, alert, and hemodynamically stable patients and may not be suitable for the operating room or intensive care unit. Transthoracic electrical impedance⁶ requires placement of electrodes that may interfere with surgical procedures. Doppler ultrasound probes placed at the suprasternal notch⁷ and the esophagus⁸ have been used for continuous cardiac output determination. The suprasternal notch may not be accessible during certain surgical procedures, such as open heart surgery, and the procedure requires

an estimate of the diameter of the ascending aorta. The esophageal Doppler probe measures blood velocity in the descending aorta, distal to the origins of the aortic arch vessels. It requires ascending aorta velocity calibration, obtained by a suprasternal notch probe, and an estimate of the ascending aortic diameter.

A new procedure for continuous measurement of cardiac output, in which a Doppler ultrasound probe is placed in the trachea, is proposed in this paper. The dimensions of the ascending aorta and the blood velocity in the ascending aorta, proximal to the origins of the aortic arch vessels, are measured. In particular, an ultrasound probe is combined with an endotracheal tube. The benefits of this procedure include: 1) the measurement is made in the ascending aorta proximal to the origins of the aortic arch vessels; 2) the relationship between the ascending aorta and trachea should be more constant than that between the descending aorta and esophagus; and 3) no additional instruments need be inserted into the patient for cardiac output determination.

The requirements and possible limitations for transtacheal Doppler cardiac output monitoring are: 1) the Doppler probe must be inserted low enough into the trachea to aim below the aortic arch and the aortic arch vessels but remain safely above the carina; 2) since ultrasound is highly attenuated in certain tissues, the cartilage of the trachea wall must be studied for ultrasound transmission characteristics; and 3) the dimension of and the blood velocity in the ascending aorta must be measured, a problem that reduces to determining the angle of intersection of the ultrasound beam with the aorta. This paper reports preliminary investigations into these requirements and the feasibility of cardiac output measurement in dogs using a Doppler probe incorporated as part of an endotracheal tube.

Materials and Methods

Since the ultimate application of transtacheal Doppler is measurement of cardiac output in humans, the anatomic relationships of the ascending aorta and trachea must be known in detail. Although described in many standard anatomic references,^{9,10} the details of this relationship and the possibility of placing a transducer within the trachea above the carina, but low enough to allow the ultrasound beam to intersect the ascending aorta proximal to the origins of the arch vessels, could not be determined with certainty. Thus, dissections of the thoracic contents of

* Instructor, Department of Surgery; and Associate Director, Critical Care, University of Minnesota.

† Applied Biometrics, Inc., Minnetonka, Minnesota.

‡ Staff Anesthesiologist, United Hospital.

Received from the Departments of Surgery and Critical Care, University of Minnesota, Minneapolis, Minnesota 55455; Applied Biometrics, Incorporated, Minnetonka, Minnesota 55345; and the Department of Anesthesiology, United Hospital, St. Paul, Minnesota 55102. Accepted for publication August 22, 1988.

Address reprint requests to Dr. Abrams: Department of Surgery, Box 11, University of Minnesota, 420 Delaware Street, S.E., Minneapolis, Minnesota 55455.

autopsy specimens were performed which verified that the anatomy was favorable for appropriate transducer placement in humans.[§]

Transmission of ultrasound through tracheal tissue was tested in an *ex vivo en bloc* preparation of pig ascending aorta, aortic arch, descending aorta, and trachea. A colloid suspension was pumped through the aorta to simulate red blood cells. To verify that the ultrasound transmission characteristics of the trachea were acceptable, an ultrasound transducer was placed in the trachea and ultrasound signals reflected from the flowing colloid suspension in the aorta were measured.

A transtracheal Doppler probe was developed (fig. 1). It embodies two important features. The first is the inclusion of a 5 mm diameter ultrasonic transducer at the distal end of the endotracheal tube. The transducer is a lead zirconate titanate piezoelectric crystal designed to operate at 5 mHz. The transducer is mounted in a molded, polyvinyl chloride holder to maintain a fixed angle with respect to the longitudinal axis of the endotracheal tube. The second feature, since ultrasound is highly attenuated in air, is a balloon cuff to assure acoustic contact of the transducer with the anterolateral wall of the trachea. The cuff has been fabricated to be a prolate ellipsoid with its major axis displaced with respect to the longitudinal axis of the endotracheal tube. When inflated, the cuff forces the transducer into contact with the tracheal wall. The electrical leads from the transducer are contained within the wall of the endotracheal tube.

The electronics unit used to drive the transducer and process the Doppler ultrasound information was an Applied Biometrics® ABCOM cardiac output computer. The unit operates in a pulsed Doppler mode with a carrier frequency of 5 mHz. When driven by the Applied Biometrics electronics unit, the ultrasound power output was below the FDA guidelines for cardiac ultrasound use. The continuous cardiac output data were digitized and accumulated for 20-s time intervals to average over the variation due to the ventilator cycle.

The volume flow rate of blood can be calculated from the blood velocity and the cross sectional area of the aorta as follows:

$$Q = \bar{v}A \quad (1)$$

where Q = volume flow rate of blood; \bar{v} = average blood velocity; and A = area of aortic cross section.

The blood velocity in the aorta and the dimensions of the aorta were measured with a pulsed Doppler ultrasound beam aimed at the aorta as shown in figure 2. The blood velocity was calculated from the Doppler shift using the following equations:¹¹⁻¹³

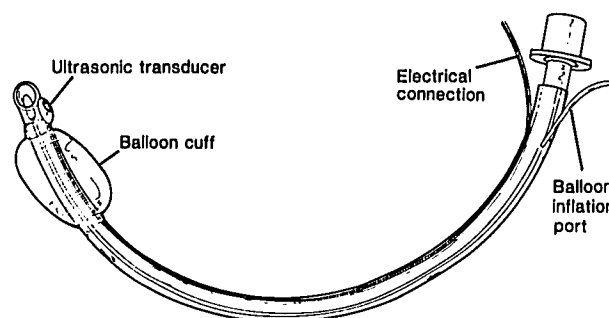


FIG. 1. Transtracheal Doppler probe mounted on an endotracheal tube.

$$\bar{v} = \frac{C\Delta f}{2f_0 \cos \phi} \quad (2)$$

where \bar{v} = average blood velocity; C = velocity of ultrasound in tissue; Δf = Doppler shift; f_0 = ultrasound carrier frequency; and ϕ = angle of ultrasound beam with respect to flow.

The cross-sectional area of the aorta was determined by range gating the Doppler signal in 1 mm steps in a direction perpendicular to the transducer through the aorta to ranges as far as 60 mm away from the transducer. Because wall motion has a distinctive audio quality, the walls of the aorta were located by audio representation of the Doppler shift. These findings were corroborated by a decrease in velocity to near background at the same distance where the audio representation of the Doppler shift changed. In this manner, the range r shown in figure 2 was determined. The cross-sectional area of the aorta was assumed to be circular and the diameter was calculated from the measured range by:

$$d = r \sin \phi \quad (3)$$

where d = diameter of aorta; r = range; and ϕ = angle of ultrasound beam with respect to flow.

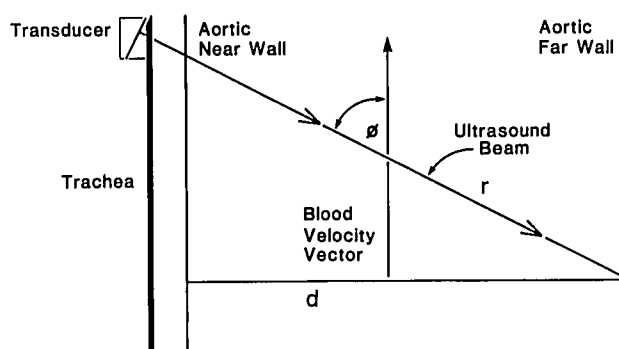


FIG. 2. Relationship of range obtained by range gating, r , to the actual aortic diameter, d , where $d = r \sin \phi$.

§ Abrams JH, Weber RE, Holmen KD: Unpublished data.

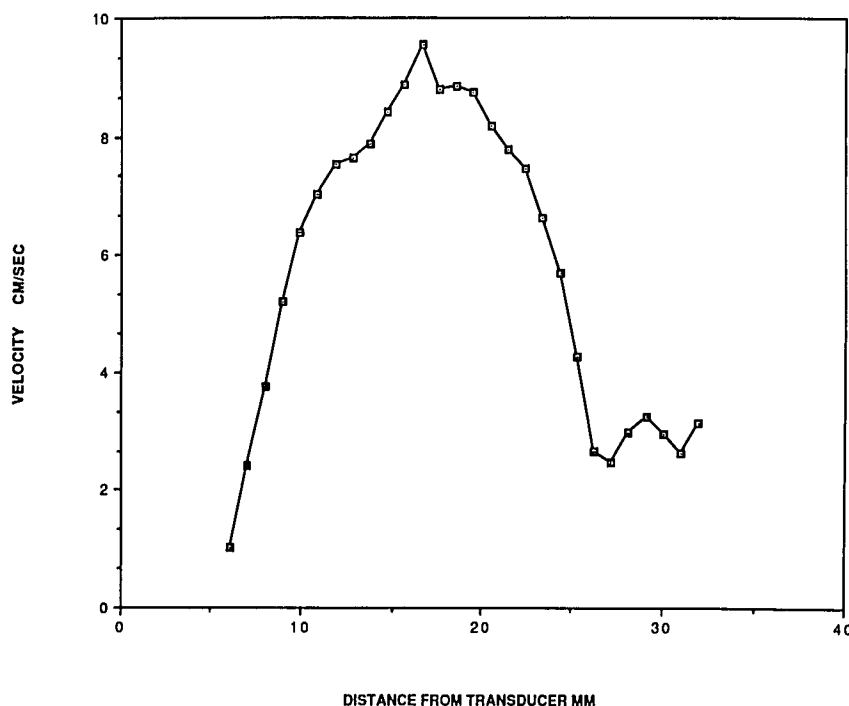


FIG. 3. Typical velocity profile obtained by transtracheal Doppler measurements. $\phi = 62.3^\circ$.

With this diameter, the area A can be calculated from:

$$A = \pi(d/2)^2 \quad (4)$$

The calculation of both velocity and area involve the angle ϕ , which must be determined empirically. A worst case was constructed by grouping all of the cardiac output data from all of the dogs. The measured variables, Q from thermodilution, Δf , and r were inserted into equations 1, 2, 3, and 4 and the angle ϕ was allowed to vary until a best least squares fit was obtained. The value of ϕ that produced a minimum residual sum of squares was used.

After obtaining institutional approval for animal studies, laboratory evaluation of the Doppler probe was done in six mongrel dogs, 20–43 kilograms. The dogs were anesthetized with pentobarbital, 30 mg/kg, and anesthesia was maintained using increments of pentobarbital. Following orotracheal intubation, the lungs were ventilated with a Harvard volume ventilator with tidal volumes of 15 ml/kg and respiratory rates of eight to ten breaths per minute. A 5-French pediatric pulmonary artery catheter with a thermistor for thermodilution cardiac output measurement was inserted *via* a jugular vein cutdown and positioned fluoroscopically. The dog was then positioned supine. The transtracheal Doppler probe (fig. 1) and the Applied Biometrics® ABCOM ultrasound monitor were used for all measurements. Because the human transtracheal Doppler probe was of insufficient length to reach proper position in the dog, tracheostomy was performed, and the transtracheal Doppler probe was inserted after

the standard endotracheal tube was removed. The procedure for inserting the transtracheal Doppler probe was the following. First, the transtracheal Doppler probe was inserted without regard to the position of the transducer. The cuff was inflated and the dogs' lungs ventilated. Second, after ventilating for 2 to 3 min, the balloon cuff was deflated and the tube positioned for maximum intensity of the audio representation of the Doppler shift. And, third, the balloon cuff was then re-inflated using the minimum air leak technique.

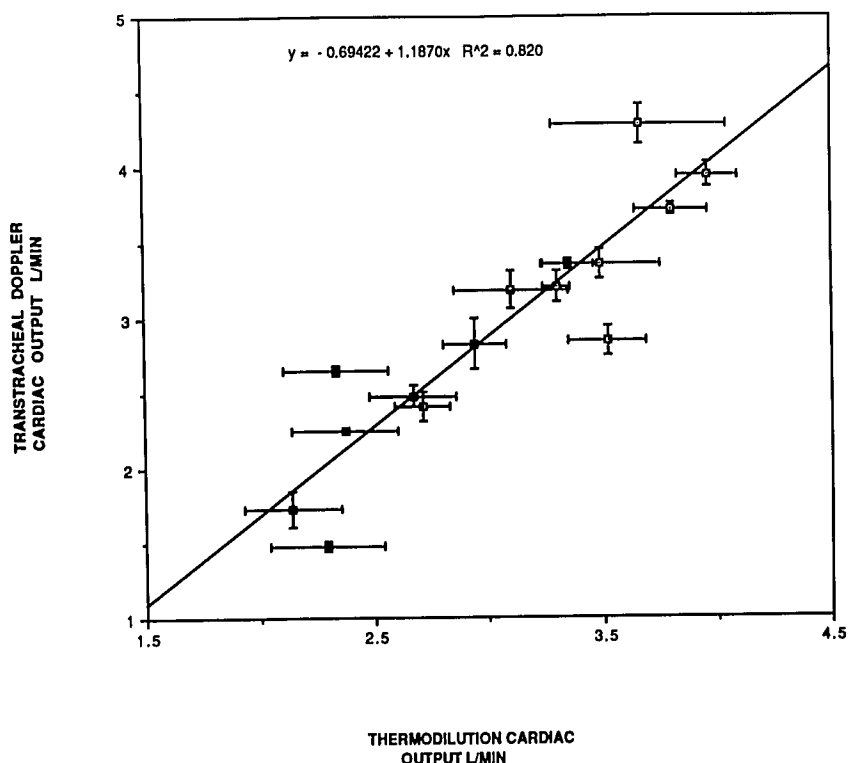
Using an Edwards Model #9200A cardiac output computer, thermodilution cardiac output was measured in triplicate and the average used for comparison with the transtracheal Doppler measurements.

Results

Position of the transtracheal Doppler probe above the carina and below the aortic arch vessels was verified by the presence of equal breath sounds bilaterally in the dogs and by autopsy examination of the position of the probe. Acoustic contact and ultrasound transmission through the trachea were adequate to allow measurements of aortic dimensions and of blood velocity in the ascending aorta.

Data obtained included a typical velocity profile, shown in figure 3. The ordinate is velocity as calculated by equation 2 from the Doppler shift. The abscissa is the distance from the transducer. Aortic dimensions were obtained from the velocity profile and the characteristic wall motion sound in the audio representation of the Doppler shift.

FIG. 4. Scatter plot of best least squares fit of transtracheal Doppler and thermodilution cardiac outputs.



In this example, the aortic near wall is at 6 mm and the far wall at 27 mm, typical dimensions for the dogs studied. Velocity data for the flow calculation were taken from the middle of the velocity profile.

Figure 4 shows a scatter plot of transtracheal Doppler cardiac outputs *versus* thermodilution cardiac outputs. The transtracheal Doppler cardiac outputs were calculated using the angle ϕ which gave the best fit using a least squares criterion. The residual sum of squares was a minimum for $\phi = 62.3^\circ$. Results are expressed as the average of triplicate determinations \pm standard deviation. The best fit equation is $y = -0.69 + 1.19x$. R^2 is 0.820.

Discussion

The present study was undertaken to demonstrate feasibility of the transtracheal Doppler procedure for continuous measurement of cardiac output. For the transtracheal Doppler procedure to work, several conditions must be met. First, the anatomy must be suitable. Since the ultimate goal is use of the transtracheal Doppler procedure in humans, the anatomic suitability of the trachea and ascending aorta was verified by the dissection of autopsy thoracic contents. These dissections suggested that a transducer could be placed in the trachea of a human, at a safe distance from the carina, and still emit an ultrasound beam that would intersect the ascending aorta

proximal to the origins of the aortic arch vessels. Second, acoustic contact must be adequate, and tracheal tissue must transmit ultrasound with suitable signal-to-noise characteristics. Satisfactory transmission of the ultrasound beam through the trachea has been verified in both *ex vivo* and *in vivo* experiments at power levels well below the FDA guidelines for cardiovascular ultrasound devices. No thermal damage to the trachea was noted in the dogs on bronchoscopic examination or at autopsy.

Third, ascending aortic dimensions and blood velocity measurements are required. The data presented in figure 3 demonstrate that the near and far walls of the ascending aorta and the velocity of blood in the ascending aorta can be determined using pulsed Doppler technology with a transducer placed in the trachea. An empirical angle, ϕ , can be fit to the data. The observers chose a worst case for analysis. The data from all of the dogs were analyzed together without regard to size of the dog or species of the dog. An angle was then empirically found using a least squares criterion. That the data can be fit over a size range of dogs, from 20–43 kg, and over a range of cardiac outputs, from 2.33–4.32 l/min, suggests that mediastinal anatomy is sufficiently reproducible and that the probe positioning procedure is suitable for cardiac output measurement in animals of vastly different sizes.

The largest source of error is that from determining aortic diameter by range gating. Since area is proportional

to the radius squared, the error increases rapidly. In figure 4, the error bars reflect the standard deviation for triplicate measurements for the thermodilution and transtracheal Doppler cardiac outputs. Of note is the small variance in cardiac outputs obtained by the transtracheal Doppler procedure for repeated measurements.

The results presented are clearly preliminary and are meant to show feasibility of the transtracheal Doppler procedure in dogs. For the ultimate application in humans, the anatomic relationships may be different. Thus, extensive work must be done in humans to confirm the constancy of the anatomy, ensure atraumatic contact of the transducer, and develop positioning procedures that do not interfere with the ventilation of the patient's lungs. In addition, further work must be done to compare dimension measurements with those obtained by B-mode echocardiography and cardiac output calculations with thermodilution cardiac outputs.

In summary, initial feasibility studies of the transtracheal Doppler procedure in dogs indicate that the procedure shows promise for measuring continuous cardiac outputs. Measurement of cardiac output can be done in dogs proximal to the origins of the aortic arch vessels. Acoustic contact can be satisfactorily maintained, and the lungs can be adequately ventilated during measurement of cardiac outputs. The transtracheal Doppler data can be fit to thermodilution cardiac outputs for a range of dog size, 20–43 kg, and of cardiac output, 2.33–4.32 l/min. The procedure raises the possibility of providing continuous cardiac output in humans. Patients for whom endotracheal intubation is necessary for other reasons could have continuous cardiac outputs obtained without additional risk.

The authors wish to thank E. J. Mikolajczyk and M. L. Olson for expert assistance and K. Kuchenmeister for tireless help in preparing this manuscript.

References

1. Weissman C: Measuring oxygen uptake in the clinical setting, Oxygen Transport and Utilization. Edited by Bryan-Brown CW, Ayres SM. Fullerton, Society of Critical Care Medicine, 1981, pp 25–64
2. Vender JS: Invasive cardiac monitoring. *Critical Care Clinics* 4: 455–477, 1988
3. Cerra FB: Hypermetabolism, organ failure and metabolic support. *Surgery* 101:1–14, 1987
4. Guyton AC, Jones CE, Coleman TG: *Circulatory Physiology: Cardiac Output and Its Regulation*. Philadelphia, WB Saunders, 1973, pp 4–80
5. Selzer A, Sudrann RB: Reliability of the determination of cardiac output in man by means of the Fick principle. *Circ Res* 6:485–490, 1958
6. Porter JM, Swain ID: Measurement of cardiac output by electrical impedance plethysmography. *J Biomed Eng* 3:222–231, 1987
7. Huntsman LL, Stewart DK, Barnes SR, Franklin SB, Colocousis JS, Hessel EA: Noninvasive Doppler determination of cardiac output in man, clinical validation. *Circulation* 67:593–602, 1983
8. Mark JB, Steinbrook RA, Gugino LD, Maddi R, Hartwell B, Shemin R, DiSesa V, Rida WN: Continuous noninvasive monitoring of cardiac output with esophageal Doppler ultrasound during cardiac surgery. *Anesth Analg* 65:1013–1020, 1986
9. Gray H: *Anatomy of the Human Body*, 30th edition. Edited by Clemente CD. Philadelphia, Lea & Febiger, 1985, pp 728–730
10. Hollinshead WH: *Textbook of Anatomy*, 4th edition. Philadelphia, Harper & Row, 1985, pp 520–522
11. Baker DW: Pulsed ultrasonic Doppler blood-flow sensing. *IEEE Transactions on Sonics and Ultrasonics*. SU17:170–185, 1970
12. Hartley CJ, Cole JS: An ultrasonic pulsed Doppler system for measuring blood flow in small vessels. *J Appl Physiol* 37:626–629, 1974
13. Blair AK, Lucas CL, Hsiao HS, Wilson BR: A removable extraluminal Doppler probe for continuous monitoring of changes in cardiac output. *J Ultrasound Med* 2:357–362, 1983