

trocardiographically to obtain a large, negative p-wave. When so positioned, the proximal orifice should be above the atrial-caval junction, and the distal tip should be near the mid right atrium.

#### REFERENCES

1. Munson ED, Paul WL, Perry JC, De Padua CB, Rhoton AL: Early detection of venous air embolism using a Swan-Ganz catheter. *ANESTHESIOLOGY* 42:223-226, 1975
2. Marshall WK, Bedford RF: Use of a pulmonary-artery catheter for detection and treatment of venous air embolism: A prospective study in man. *ANESTHESIOLOGY* 52:131-134, 1980
3. Rudehill A, Langerkranser M, Lindquist C, Gordon E: Effects of mannitol on blood volume and central hemodynamics in patients undergoing cerebral aneurysm surgery. *Anesth Analg* 62:875-880, 1983
4. Artru AA, Colley PS: Bunegin-Albin catheter improves air retrieval and resuscitation from lethal air embolism in prone dogs. *Anesth Analg* 66:991-994, 1987
5. Bowdle TA, Artru AA: Treatment of air embolism with a special pulmonary artery catheter introducer sheath in sitting dogs. *ANESTHESIOLOGY* 68:107-110, 1988
6. Bunegin L, Albin MS, Helsel PE, Hoffman A, Hung T-K: Positioning the right atrial catheter: A model for reappraisal. *ANESTHESIOLOGY* 55:343-348, 1981
7. Martin JT: Neuroanesthetic adjuncts for surgery in the sitting position III. Intravascular electrocardiography. *Anesth Analg* 49:793-805, 1970
8. Johans TG: Multiorificed catheter placement with an intravascular electrocardiographic technique. *ANESTHESIOLOGY* 64:411-413, 1986
9. Warner DO, Cucchiara RY: Position of proximal orifice determines electrocardiogram recorded from multiorificed catheter. *ANESTHESIOLOGY* 65:235-236, 1986
10. Artru AA, Colley PS: The site of origin of the intravascular electrocardiogram recorded from multiorificed intravascular catheters. *ANESTHESIOLOGY*, in press

Anesthesiology  
69:279-281, 1988

## Difficulty in Endotracheal Intubation Due to Congenital Tracheal Stenosis: A Case Report

ZEYNEP ESENER, M.D.,\* AYLÄ TÜR, M.D.,† BARIŞ DIREN, M.D.‡

Difficulty in endotracheal intubation is not uncommon, and can arise either from inability to visualize the larynx and/or from obstruction to the passage of the tracheal tube.<sup>1</sup> Difficulty in advancing the tube into the trachea after it has passed between the vocal cords is not common, and may be due to tracheal stenosis resulting from thyroid or mediastinal tumors, previous tracheostomy, prolonged intubation, or traumatic lesions.<sup>2-5</sup> Congenital tracheal stenosis may also cause serious problems, but is usually seen in early childhood in patients presenting with respiratory difficulties.<sup>3,6</sup> There is one report in which double lumen endobronchial tube placement was difficult due to congenital tracheal stenosis in the adult.<sup>7</sup> We present a patient in whom we were unable to insert an endotracheal tube into the trachea. In this asymptomatic patient, a diagnosis of congenital tracheal stenosis was made based on bronchoscopy, tracheobronchography, and serial computerized tomographic (CT) scans.

#### CASE REPORT

A 39-yr-old, 162 cm, 65 kg woman with cholelithiasis was scheduled for a cholecystectomy. Her medical history revealed no respiratory difficulties with daily activities, including climbing stairs and walking uphill, and she was not taking any medications. Preoperative chest radiography and routine laboratory findings were considered normal.

After receiving atropine 0.5 mg and meperidine 50 mg im, anesthesia was induced with thiopental, 400 mg iv, and succinylcholine, 100 mg iv. There was no difficulty in manually ventilating the lungs via a mask. The glottis was exposed by direct laryngoscopy, and a 34-Fr (OD 11.3 mm with cuff) endotracheal tube was inserted through the vocal cords with ease. However, the tip of the tube could not be advanced beyond approximately 2.5-3 cm distal from the vocal cords. The tube was withdrawn and smaller sizes were tried, but even a 28-Fr (9.3 mm OD) tube could not be advanced into the trachea, and the cuff was between the cords. Trying a smaller size was not considered appropriate at this stage, and the operation was postponed for further evaluation of the trachea. Manual ventilation was performed adequately until the neuromuscular blockade had been terminated.

Endoscopic examination, performed 2 days later, with a rigid bronchoscope (6.5 mm), revealed an annular stenosis starting 3 cm below the cords. This area was also slightly inflamed, probably due to the previous intubation attempts. The adult size bronchoscope, which was the narrowest of the adult range, could not be advanced further. The child size (3.5 mm) was passed through the narrow segment, and this segment was found to be approximately 3.5-4 cm in length and hourglass shaped. The carina and main bronchi were normal up to the lower lobe openings. Anti-inflammatory treatment was started, and the patient was called back a week later.

Serial CT scans of the neck and mediastinum revealed a segmental narrowing of the tracheal lumen (10 mm in diameter) at the level of 1/3 median segment of trachea (between C6-7 intervertebral disk and upper level of T<sub>2</sub> vertebra). The cross-section of the trachea was circular along this segment (fig. 1). The transverse diameter of the tra-

\* Professor of Anesthesiology.

† Assistant Professor of Anesthesiology.

‡ Assistant Professor of Radiology.

Received from the Departments of Anesthesiology and Radiology, Ondokuz Mayıs University Medical School, Samsun, Turkey. Accepted for publication March 16, 1988.

Address reprint requests to Dr. Esener: Department of Anesthesia, Ondokuz Mayıs University Medical School, PK 29-55001 Samsun, Turkey.

Key words: Intubation, endotracheal; congenital tracheal stenosis.

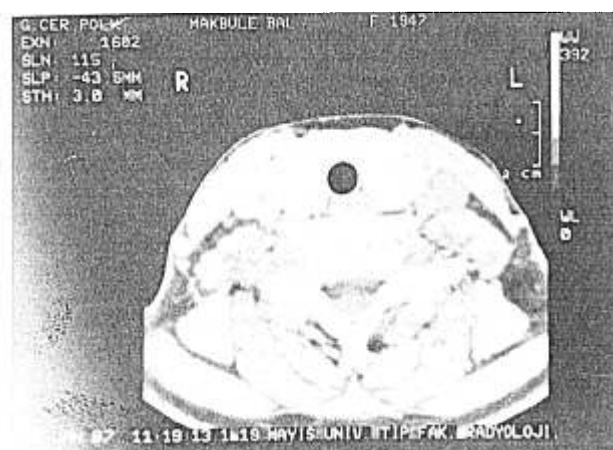

FIG. 1. The tracheal cross-section of the stenotic segment at the seventh cervical vertebra level.

cheal lumen in the same angled slice taken 15 mm proximal to the stenotic segment was 16 mm (fig. 2). Sagittal reconstructive image obtained from transaxial slices also clearly showed the stenotic segment (fig. 3). Conventional tracheo-bronchography also showed that the narrow segment of trachea was approximately 4 cm in length and the tracheal lumen's diameter was normal above and below this segment (fig. 4).

The patient was scheduled for surgery at a later date. Premedication and induction of anesthesia was planned as previously described. Again, we were unable to insert a 28-Fr endotracheal tube beyond the stenotic portion of the trachea. A smaller-sized tube was not considered, because of the resistance it might cause to respiration. A 32-Fr tube was placed into the normal portion of the trachea below the cords above the stenotic portion, and the cuff was not inflated. A piece of gauze was placed around the tube in the pharynx to prevent leakage. Anesthesia was uneventful, and there were no respiratory problems. The postoperative course was also uneventful, and the patient was discharged on the 8th postoperative day. For future anesthetic management, a detailed information sheet was given to the patient.

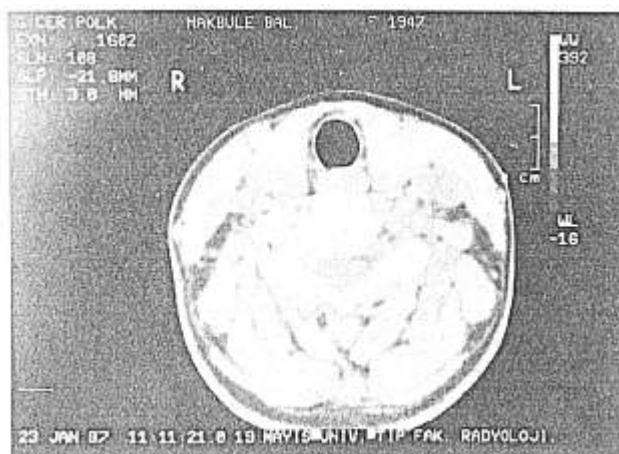

FIG. 2. The tracheal cross-section of the normal portion at the sixth cervical vertebra upper level.




FIG. 3. Sagittal reconstructive image obtained from transaxial slices shows the narrow segment. A-B: Just above carina; C-D: stenotic segment of the trachea at the level of the one-third mid portion; E-F: just below the cords (please disregard the dimensions and see the text).

## DISCUSSION

There are several causes of difficulty in intubating the trachea, mainly because of inadequate exposure of the vocal cords or difficult passage of the tube between the vocal cords into the trachea. The latter problem is not encountered often, but is usually predictable and anticipated by routine evaluation and the medical and clinical conditions of the patient before anesthesia. Tracheal lesions causing difficulty are mainly congenital and neoplastic, as well as injuries, infections, and post-intubation and post-tracheostomy injuries.<sup>2-5</sup> In our case, there was no clue to these problems in her medical history, and she was asymptomatic until we experienced difficulty with the endotracheal intubation. Examinations carried out afterwards revealed a narrow segment, 4 cm in length, along the middle portion of the trachea, but no intra- or extraluminal lesion causing stenosis could be seen. Therefore, mild congenital tracheal stenosis was thought to cause the problem.

Congenital tracheal stenosis is a quite rare entity, and the incidence is not known. The largest series reported is by Benjamin *et al.*,<sup>6</sup> who presented 21 cases, all of them infants or small children. Saito *et al.*<sup>7</sup> described an adult patient with congenital tracheal stenosis in whom the double lumen endobronchial tube could not be properly placed. Like ours, there was a stenotic segment in the trachea 3 cm in length 4 cm above the carina.

Benjamin *et al.*<sup>6</sup> classified the congenital tracheal stenosis into three types (*i.e.*, funnel-like, segmental, or generalized). Stenosis was segmental in our case, starting approximately 3 cm below the cords and extending 4 cm.

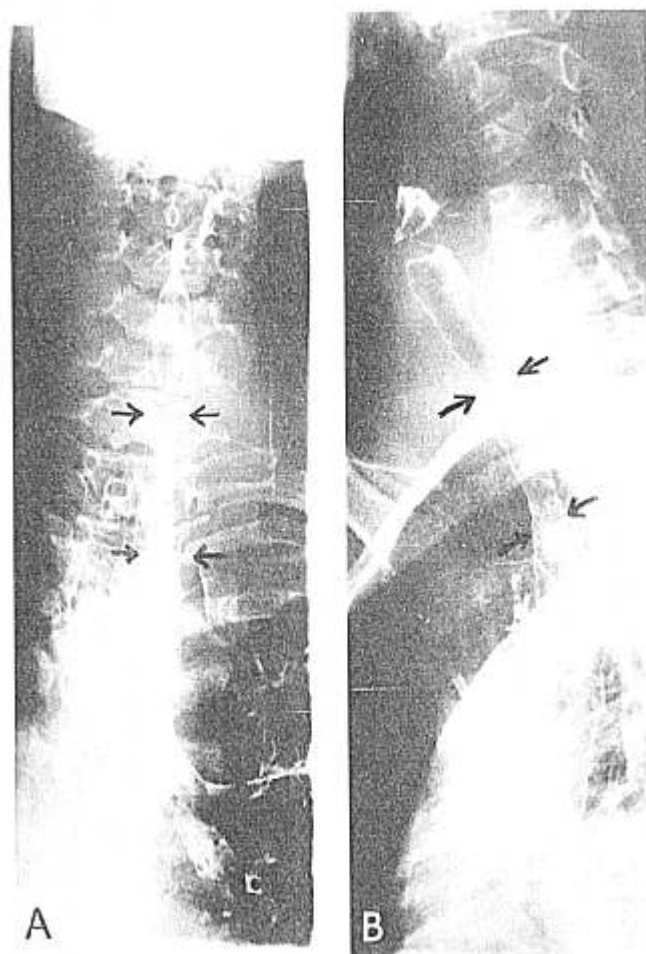


FIG. 4. Arrows show the narrow segment in lateral (A) and AP (B) views of the tracheo-bronchogram.

In congenital stenosis, the tracheal cartilages are smaller than normal and lack the normal structure of the posterior membranous trachea.<sup>8</sup> In the case reported by Saito *et al.*,<sup>7</sup> macroscopic examination of the trachea indicated that stenotic segment lacked its membranous portion. Macroscopic examination was not possible in our case, and the bronchoscopist failed to notice whether there were complete rings. However, the outline of the posterior wall of the narrow segment in lateral bronchograms and the circular shaped cross-section of the trachea suggested that membranous portion also may be lacking in our case. The incidence of circu-

lar shaped cross-section of the trachea is reported to be one in 200 cases by Mehta and Myat<sup>9</sup> and two in 111 cases by Mackenzie *et al.*<sup>10</sup> in autopsy specimens. However, in those patients, cross-section of trachea was circular along the whole length of the trachea, whereas, in our case, it was so only along the narrow segment.

The transverse diameter of the tracheal lumen in the slice taken from the stenotic segment was 10 mm, as opposed to the diameter of the normal segment, which was 16 mm. In the adult, mean transverse diameter of the tracheal lumen is 17.5 mm, with a range of 11–26 mm.<sup>2</sup> Therefore, the stenosis in our case may be considered mild.

Although the patient had no respiratory complaints related to the stenosis, this may be explained by lack of any extreme exertion by the patient. Still, inflammation or edema of any cause may lead to respiratory difficulty.

In conclusion, repeated failure of a suitable tube to enter the trachea after it passed through the vocal cords without difficulty should be considered to indicate the presence of airway narrowing and, possibly, congenital tracheal stenosis.

#### REFERENCES

1. Latto IP, Rosen M: Intubation procedure and causes of difficult intubation, *Difficulties in Tracheal Intubation*. London, Bailliere Tindall, 1985, pp 79–89
2. Fraser RG, Pare JAP: *Diagnosis of Diseases of the Chest*. Philadelphia, W.B. Saunders, 1977, p 56
3. Grillo HC: Congenital lesions, neoplasms and injuries of the trachea, *Surgery of the Chest*. Philadelphia, W.B. Saunders, 1976, pp 256–293
4. Grillo HC: Tracheal tumors, surgical management. *Ann Thorac Surg* 26:112–125, 1978
5. Kaplan JA: *Thoracic Anaesthesia*. New York, Churchill-Livingstone, 1983, p 426
6. Benjamin B, Pithin J, Cohen D: Congenital tracheal stenosis. *Ann Otol* 90:364–371, 1981
7. Saito S, Dohi S, Tajima K: Failure of double-lumen endobronchial tube placement: Congenital tracheal stenosis in an adult. *ANESTHESIOLOGY* 66:83–85, 1987
8. Greene DA: Congenital complete tracheal rings. *Arch Otolaryngol* 102:241–243, 1976
9. Metha S, Myat HM: The cross-sectional shape and circumference of the human trachea. *Ann Roy Coll Surg Eng* 66:356–358, 1984
10. Mackenzie CF, McAslan TC, Shin B, Schellinger D, Helrich M: The shape of the human adult trachea. *ANESTHESIOLOGY* 49:48–50, 1978