

The Site of Origin of the Intravascular Electrocardiogram Recorded from Multiorificed Intravascular Catheters

Alan A. Artru, M.D.,* Peter S. Colley, M.D.*

Successful retrieval of venous air emboli *via* central venous catheters requires accurate placement of the distal tip of the catheter. The distal tip of single-orificed central venous catheters can be precisely located using intravenous electrocardiography (IVECG). However, the site of origin of the IVECG complex with multiorificed central venous catheters is not well known. In this study, the site of origin of the IVECG complex deriving from the wire within a multiorificed Arrow® Antecubital Central Venous Catheterization Kit, the same Arrow® catheter type without wire, and a multiorificed Cook® Bunegin-Albin CVP Kit was determined in ten anesthetized dogs. The IVECG was found to originate from the distal portion of the Arrow® wire whether the distal tip of the wire was within the distal segment of the Arrow® multiorificed catheter, at the tip of the catheter, or protruding several cm from the tip of the catheter. When the Arrow® multiorificed catheter (without wire) was used to determine the IVECG, the mean site of origin of the IVECG was 1.7 ± 1.2 cm (mean \pm SD) proximal to the distal catheter tip. When the Cook® multiorificed catheter (without wire) was used to determine the IVECG, the mean site of origin of the IVECG was 2.5 ± 0.6 cm proximal to the distal catheter tip. Knowledge of the site of origin of the IVECG with the Arrow® and Cook® multiorificed catheters should permit the distal tips of these catheters to be placed in locations where efficient retrieval of venous air emboli is likely. (Key words: Embolism, air: venous. Equipment, catheters: central venous; right atrial. Heart, electrocardiography: intravascular. Monitoring: central venous; electrocardiography.)

VENOUS AIR EMBOLI (VAE) may be retrieved from the right atrium using a single-lumen, multiorificed catheter.¹ Two such catheters designed to be inserted *via* antecubital veins are the Cook® Bunegin-Albin CVP Kit (Cook Incorporated, Bloomington, IN) and the Arrow® Antecubital Central Venous Catheterization Kit (Arrow International Incorporated, Reading, PA). Efficient retrieval of VAE with multiorificed catheters is possible only with accurate positioning of the catheter tip relative to the right atrial (RA)-superior vena cava (SVC) junction (sinoatrial [SA] node). Bunegin *et al.* reported that the percentage of air recovered from a model of the human heart decreased from 63–81% to less than 28% when the tip of a multiorificed catheter was moved

Please see: Letter to the Editor, Johans TG: Arrow brachial CVP air aspirating catheter placement with the IVECG technique. ANESTHESIOLOGY 69:140–141, 1988.

* Associate Professor of Anesthesiology.

Received from the Department of Anesthesiology, School of Medicine, University of Washington, Seattle, Washington. Accepted for publication February 12, 1988.

Address reprint requests to Dr. Artru: Department of Anesthesiology, RN-10, University of Washington School of Medicine, Seattle, Washington 98195.

only 1.0–2.0 cm from the position of most efficient retrieval of VAE.¹

One means of accurate placement of single-orificed catheters relative to the SA node is intravascular electrocardiography (IVECG).² With single-orificed catheters, the IVECG clearly derives from the distal and only orifice. However, there have been no reports on the site of origin of the IVECG with the Cook® Bunegin-Albin or Arrow® Antecubital multiorificed catheters. Thus, it is not certain whether the IVECG derives from the proximal orifice, the distal orifice, or some intermediate point with these catheters. Consequently, accurate placement of the catheter tip relative to the SA node may not be achieved, and the potential for efficient retrieval of VAE may be lost.

The present study was designed to determine the site of origin of the IVECG with the Cook® Bunegin-Albin multiorificed catheter (14 gauge diameter, 60 cm in length, one distal orifice, and six side holes of 1.0 mm diameter) and the Arrow® Antecubital multiorificed catheter (16 gauge diameter, 91 cm in length, one distal orifice, and four oval side holes of 1.0×1.5 mm diameter) in anesthetized dogs. Because a J-wire is contained within the lumen of the Arrow® Antecubital catheter as the catheter is advanced intravascularly, the J-wire, rather than the catheter itself, may be used for IVECG.³ Accordingly, the present study also determined the site of origin of the IVECG with the J-wire within the Arrow® antecubital catheter. In contrast, when placing the Cook® Bunegin-Albin catheter, the J-wire is first inserted to a depth likely to place the tip within the heart, then the catheter is advanced over the wire, the wire is removed, and the position of the catheter is determined.⁴ Because the position of the wire tip relative to the catheter tip is not known when this placement technique is used, the present study did not seek to determine the site of origin of the IVECG with the J-wire within the Cook® Bunegin-Albin catheter.

Materials and Methods

ANIMAL PREPARATION

This study was approved by the Animal Care Committee of the University of Washington. Ten unmedicated mongrel dogs (weights 15–23 kg) were studied. Anesthesia was induced with halothane (>1.5%, inspired) and nitrous oxide (66%, inspired) in oxygen. The trachea was intubated and ventilation was con-

trolled. The right femoral artery was cannulated to permit arterial blood sampling for blood gas analysis and to permit continuous monitoring of systemic arterial pressure and heart rate. Mean arterial pressure (MAP) was determined by electronic integration. A urinary catheter was inserted, the right femoral vein was cannulated for fluid administration, expired CO₂ was continuously monitored, and temperature was monitored by a nasopharyngeal thermistor probe.

The method of determining the site of origin of the IVECG involved four steps: 1) a single-orificed catheter and the test catheter were inserted into the SVC with the catheters lying side-by-side and the distal tips aligned; 2) the IVECG was recorded from the single-orificed catheter and both catheters advanced so that both tips were located at the SA node; 3) the IVECG then was recorded from the test catheter, and the test catheter was advanced or withdrawn (single-orificed catheter held in place) until an IVECG similar to that recorded in step 2 *via* the single-orificed catheter was seen; and 4) the distance that the test catheter was moved (relative to the single orificed catheter) indicated how far from the distal tip was the site of origin of the IVECG as recorded *via* the test catheter. The details of these steps are presented in the following paragraphs.

An incision was made in the right external jugular vein, and a section of clear, flexible tubing (4.5 mm internal diameter, 35 cm in length) was inserted so that the distal tip was located in the SVC. Heparinized saline was injected into the open proximal end of the tubing to prevent clot formation. This tubing served as an "introducer sheath" for subsequent placement of single-orificed and Arrow® and Cook® multiorificed catheters into the right external jugular vein.

A single-orificed catheter (1.0 mm internal diameter, 60 cm in length) and either the Arrow® or Cook® multiorificed catheter were laid side-by-side with the distal tips aligned before being inserted into the dog. The single-orificed catheter and either the Arrow® or Cook® catheter were fastened together at the proximal end, and both catheters were marked at 5 cm intervals so that, when the catheters were simultaneously inserted into the jugular vein, it could be assured that the visible portions of the catheters were still aligned. Both catheters were filled with heparinized bicarbonate solution,⁵ then inserted through the large bore tubing, being still fastened side-by-side with the distal tips aligned. Once the catheter tips were beyond the distal tip of the large bore tubing, the chest lead of a six-lead ECG cable was attached to the proximal end of the single-orificed catheter *via* a metal stopcock. The other five leads of the ECG cable were attached at the standard four limb sites and one midline "ground" site using metal needles. The IVECG deriving from the distal tip of the

single-orificed catheter was displayed using an ECG amplifier and strip chart recorder (Gould Incorporated, Cleveland, OH).

ARROW® WIRE COMPARED TO SINGLE-ORIFICED CATHETER

The single-orificed and Arrow® catheters were advanced simultaneously until the IVECG deriving from the distal tip of the single-orificed catheter indicated that the catheter tips were located at the SA node. (Because the catheters were not attached at the distal end, it is possible that the tips of the two catheters separated from one another once they passed beyond the distal portion of the introducer sheath.) Catheter tips were considered to be at the SA node when: 1) the IVECG complex consisted of a negative deflection P wave with amplitude equal or greater than the negative deflection of the QRS, and 2) the negative deflection of the P wave became smaller in amplitude if the catheters were advanced or withdrawn.² After locating the catheter tips at the SA node using the single-orificed catheter, the wire for the Arrow® multiorificed catheter was inserted into the catheter so that the tip of the wire was located at the distal tip of the catheter. (The wire had previously been marked at the proximal end so that it could be inserted the proper distance to place the tip of the wire at the distal tip of the catheter.) The chest lead of the six-lead ECG cable was removed from the metal stopcock at the proximal end of the single-orificed catheter and attached to the proximal end of the wire within the Arrow® catheter *via* a metal clip. The IVECG was recorded with the wire 2 mm beyond the catheter tip for comparison with the IVECG complex recorded from the single-orificed catheter tip. The IVECG was then recorded from the Arrow® wire: 1) after the tip of the wire had been advanced 0.5, 1.0, 1.5, 2.0, and 2.5 cm from the position where the wire was located at the distal tip of the catheter, and 2) after the wire had been pulled back 0.5, 1.0, 1.5, 2.0, 2.5, and 3.0 cm from the position where the wire was located at the distal tip of the catheter (catheter position unchanged).

The chest lead of the six-lead ECG cable was removed from the Arrow® wire and attached to the metal stopcock at the proximal end of the single-orificed catheter. The single-orificed and Arrow® catheters were advanced simultaneously until the IVECG deriving from the distal tip of the single-orificed catheter indicated that the catheter tips were located at the mid-RA. Catheter tips were considered to be at mid-RA when: 1) the IVECG complex consisted of a large biphasic P wave with positive deflection equal in amplitude to negative deflection, and 2) the positive and negative deflections of the biphasic P wave became unequal in amplitude when the catheters were advanced or withdrawn.² After

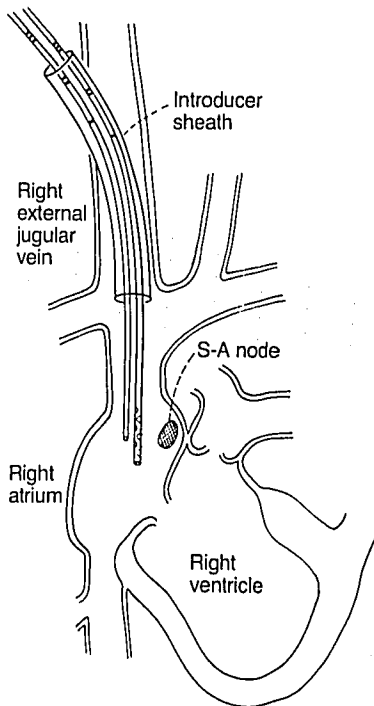


FIG. 1. The single-orificed and multiorificed catheters are attached so that the tips are aligned, and the IVECG is recorded from the single-orificed catheter. The attached catheters are advanced until an IVECG complex characteristic of the SA node (shown schematically, not anatomically) is obtained from the single-orificed catheter. The attachment between the catheters is cut and the IVECG is recorded from the multiorificed catheter. The single-orificed catheter position is fixed, and the multiorificed catheter is advanced (or withdrawn) until an IVECG complex characteristic of the SA node is obtained.

The difference between the marks on each catheter relative to proximal end of the introducer sheath indicates the difference between the catheter tips and, thus, the site of origin of the IVECG with the multiorificed catheter.

locating the catheter tips at the mid-RA using the single-orificed catheter, the wire for the Arrow® catheter was inserted so that the tip of the wire was located at the distal tip of the catheter. As at the SA node, the IVECG was recorded from the wire when it was located at the catheter tip and after the wire was advanced or withdrawn 0.5, 1.0, 1.5, 2.0, and 2.5 or 2.5 and 3.0 cm.

ARROW® CATHETER COMPARED TO SINGLE-ORIFICED CATHETER

The chest lead of the six-lead ECG cable was removed from the Arrow® wire and attached to the metal stopcock at the proximal end of the single-orificed catheter. The single-orificed and Arrow® catheters were simultaneously repositioned at the SA node. The IVECG was then recorded from the Arrow® wire to confirm that the catheter tips still were aligned. The wire was removed from the Arrow® catheter and the catheter was filled with a heparinized bicarbonate solution.⁵ The chest lead of the six-lead ECG cable was attached to the Arrow® catheter *via* the metal adapter at the proximal end of the catheter, and the IVECG was recorded. The position of the Arrow® catheter (proximal end) relative to both the large-bore tubing and the single-orificed catheter (proximal ends) was noted, the positions of the large-bore tubing and single-orificed catheter relative to the dog were stabilized, and the attachments between

the single-orificed and Arrow® catheters were cut. The Arrow® catheter was then advanced or withdrawn until an IVECG complex characteristic of the SA node was obtained (fig. 1). The distance that the Arrow® catheter had been moved to obtain an IVECG complex characteristic of the SA node was measured to the nearest 0.1 cm and recorded. This distance indicated how far proximal from the distal tip of the Arrow® catheter was the site of origin of the IVECG. The single-orificed and Arrow® catheters were again fastened together at the proximal end and simultaneously withdrawn from the introducer sheath. The catheters were laid side-by-side and the position of the tip of the single-orificed catheter relative to the tip of the Arrow® catheter was measured to the nearest 0.1 cm and recorded. This was done to verify the site of origin of the IVECG from the Arrow® catheter as determined by *in vivo* measurements.

COOK® CATHETER COMPARED TO SINGLE-ORIFICED CATHETER

The methodology for these comparisons was the same as that used for the Arrow® catheter compared to single-orificed catheter, above.

STATISTICAL ANALYSIS

Systemic variables were compared between conditions using analysis of variance for repeated measures. The distances that the Arrow® and Cook® catheters were inserted to obtain an IVECG characteristic of the SA node were compared to the distance that the single-orificed catheter was inserted to obtain an IVECG characteristic of the SA node. The mean and SD of those Arrow®-to-single-orifice and Cook®-to-single-orifice distances was computed. The distance that the Arrow® and Cook® catheters were advanced beyond the distal tip of the single-orificed catheters indicated how far proximal from the distal tip of the Arrow® and Cook® catheters was the site of origin of the IVECG complex.

Results

ARROW® WIRE COMPARED TO SINGLE-ORIFICED CATHETER

With the tip of the Arrow® multiorificed catheter located at the SA node, the IVECG complex obtained from the wire within the Arrow® catheter was characteristic of the SA node in all dogs only when the wire was located at the catheter tip (fig. 2). The IVECG obtained from the wire changed from a complex that was characteristic of the SA node to a complex with a small negative P wave when the tip of the wire was pulled back to a location within the multiorificed portion of the catheter (catheter tip still at the SA node). The

IVECG obtained from the wire changed to a complex with biphasic P wave when the tip of the wire was advanced several cm to a location beyond the tip of the multiorificed catheter (catheter tip still at the SA node).

With the tip of the Arrow® multiorificed catheter located at the mid-RA, the IVECG complex obtained from the wire within the Arrow® catheter was characteristic of the mid-RA in all dogs only when the wire was located at the catheter tip. The IVECG obtained from the wire changed from a complex that was characteristic of the mid-RA to a complex with a negative P wave when the tip of the wire was pulled back to a location within the multiorificed portion of the catheter (catheter tip still at the mid RA). The IVECG obtained from the wire changed to a complex with a small biphasic P wave whose negative deflection was only about 25% of the amplitude of the negative deflection of the QRS when the tip of the wire was advanced several cm to a location beyond the tip of the multiorificed catheter (catheter tip still at the SA node).

ARROW® CATHETER COMPARED TO SINGLE-ORIFICED CATHETER

When the tip of the single-orificed catheter was located at the SA node and the tip of the Arrow® catheter aligned with the tip of the single-orificed catheter, the IVECG complex recorded from the Arrow® catheter (without wire) was not characteristic of the SA node. Instead, the complex was characteristic of a location proximal to the SA node. An IVECG complex characteristic of the SA node was seen only if the Arrow® catheter was advanced so that its tip was 1.7 ± 1.2 cm (mean \pm SD) beyond the SA node.

COOK® CATHETER COMPARED TO SINGLE-ORIFICED CATHETER

When the tip of the single-orificed catheter was located at the SA node and the tip of the Cook® catheter aligned with the tip of the single-orificed catheter, the IVECG complex recorded from the Cook® catheter was not characteristic of the SA node. As with the Arrow® catheter, the complex was characteristic of a location proximal to the SA node. An IVECG complex characteristic of the SA node was seen only if the Cook® catheter was advanced so that its tip was 2.5 ± 0.6 cm beyond the SA node.

Systemic variables were not different between conditions (not tabulated).

Discussion

The results of this study indicate that, when the IVECG is recorded from the wire within the Arrow® catheter, the signal identifies the position of the tip of

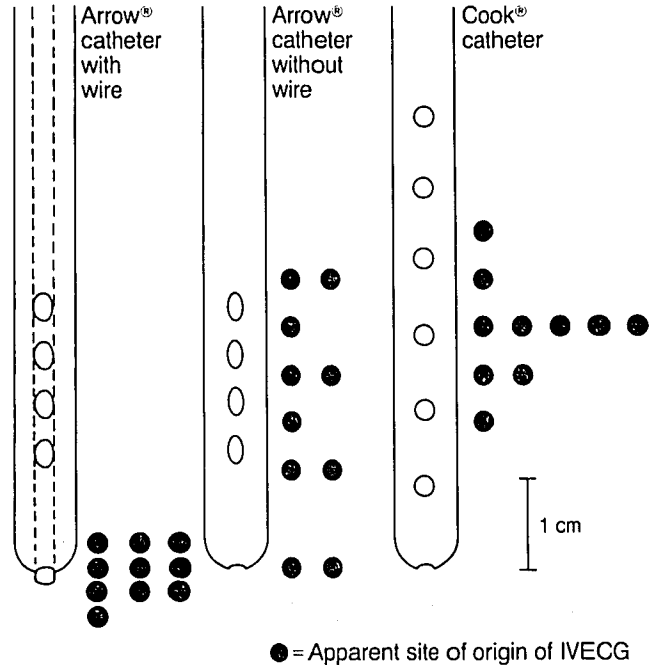


FIG. 2. Schematic versions of the Arrow® and Cook® multiorificed catheters show the location of the distal orifice and the side holes. The position of the solid circle relative to the longitudinal axis of the catheter (spaced at 0.5 cm intervals for clarity) shows the apparent site of origin of the IVECG. The number of solid circles at each position indicates the frequency of that location appearing to be the site of origin of the IVECG. When the IVECG was recorded from the wire (dashed lines) within the Arrow® catheter (tip of wire at tip of catheter), the complex originated from the distal end of the catheter. When the IVECG was recorded from the Arrow® catheter without wire, the site of origin of the complex varied from the proximal side hole to the distal orifice. When the IVECG was recorded from the Cook® catheter, the site of origin of the complex varied but was centered around the middle portion of the multiorificed area.

the catheter when the wire extends just to the tip of the catheter. The wire is located at the tip of the catheter when the hub at the proximal end of the wire is separated by 2.7 cm from the hub at the proximal end of the catheter. If the IVECG is recorded from the wire while the hub on the wire is fit snugly into the hub on the catheter, 2.7 cm length of wire (in a "J" configuration) will protrude from the tip of the catheter. The IVECG does not identify the position of the tip of the catheter in this case, but, rather, derives from a location a short distance distal to the catheter tip. If the IVECG is recorded from the wire while the hub on the wire is separated from the hub on the catheter by more than 2.7 cm, the tip of the wire will lie within the catheter. The IVECG does not identify the position of the tip of the catheter in this case, but, rather, derives from a location some distance proximal to the catheter tip.

When the Arrow® catheter (without wire) or Cook® catheter is used to record the IVECG, the signal derives from a location somewhere between the proximal and

distal orifices of the catheter. With both catheters, the mean location of the IVECG was at the middle orifice of the catheter. Specifically, the Arrow® catheter has five orifices, one each at distances 0, 1.2, 1.7, 2.2, and 2.7 cm from the distal tip of the catheter. The position of the middle orifice (1.7 cm from the catheter tip) corresponds to the mean location of the IVECG (1.7 ± 1.2 cm proximal to the catheter tip). The Cook® catheter has seven orifices, one each at distances 0, 0.8, 1.6, 2.4, 3.2, 3.9, and 4.7 cm from the distal tip of the catheter. The position of the middle orifice (2.4 cm from the catheter tip) corresponds to the mean location of the IVECG (2.5 ± 0.6 cm proximal to the catheter tip).

Assuming that the optimum location for the tip of a multiorificed catheter is 1.0 cm distal to the SA node,¹ and that the relationship between the site of origin of the IVECG and the catheter tip is similar in humans to that in dog, the results of this study suggest that Arrow® and Cook® catheters should be inserted as follows. When the Arrow® catheter is positioned using the wire to record the IVECG, the tip of the wire should be located at the distal tip of the catheter. An IVECG characteristic of the SA node should be obtained, then the catheter should be advanced 1.0 cm. When positioning the Arrow® catheter (without wire) *via* IVECG, an IVECG characteristic of the SA node should be obtained, then the catheter should be pulled back by a mean distance of 0.7 cm so that the catheter tip will be located 1.0 cm distal to the SA node. It should be emphasized that the mean distance of 0.7 cm is an average figure, and that the range that observed in this study was ± 1.5 cm. Because the range of values was so great with the Arrow® catheter (without wire), positioning of the catheter using the wire may be preferable.

When positioning the Cook® catheter *via* IVECG, and IVECG characteristic of the SA node should be obtained, then the catheter should be pulled back by a mean distance of 1.5 cm so that the catheter tip will be located 1.0 cm distal to the SA node. Accurate placement of the Cook® catheter may be more likely than accurate placement of the Arrow® catheter (without wire), because the range observed in this study for the Cook® catheter was ± 1.0 cm, less than that with the Arrow® catheter. It should be noted that the recommendation that the tips of multiorificed catheters should be located 1.0 cm distal to the SA node is based on *in vitro* data.¹ There are no *in vivo* studies to verify that recommendation. Thus, while the results of this study should be helpful to clinical practice by providing data on the average site of origin of the IVECG, there is

no indication that measurements as precise as those made here will improve clinical care.

The finding in this study that the IVECG recorded from a multiorificed catheter originates from a location proximal to the catheter tip is consistent with a previous report by Johans.³ In that study, a custom-designed, double-lumen catheter, with one distal orifice (size not given) in one lumen and 15 orifices (2.5 mm in diameter, personal communication) spaced over the distal 10 cm of the second lumen was examined in three patients. The IVECG of the multiorificed lumen was 10 cm proximal to that of the single-orificed lumen. The finding in this study that the IVECG from a multiorificed catheter originates from the midpoint of the multiple orifices is not consistent with the proposal that the IVECG originates from the most proximal orifice.^{3,6} Whether the IVECG originates from the most proximal orifice or from a point somewhere between the proximal and distal orifices may be influenced by the size and spacing of the orifices, and should be determined for each catheter type.

The range of the data for apparent site of origin of the IVECG is wide with the Arrow® catheter (without wire) and narrow and normally distributed with the Cook® catheter. The explanation for this is unknown. The different spacing of the orifices on the Arrow® and Cook® catheters, the difference in orifice sizes, or differences in materials or internal structures may account for the differences in the range of the IVECG data. The present results do not indicate whether these or other differences between the catheters account for the disparity in the range of IVECG data.

References

1. Bunegin L, Albin MS, Helsel PE, Hoffman A, Hung T-K: Positioning the right atrial catheter: A model for reappraisal. *ANESTHESIOLOGY* 55:343-348, 1981
2. Martin JT: Neuroanesthetic adjuncts for patients in the sitting position III. Intravascular electrocardiogram. *Anesth Analg* 49:793-808, 1970
3. Johans TG: Multiorificed catheter placement with an intravascular electrocardiographic technique. *ANESTHESIOLOGY* 64:411-413, 1986
4. Smith SL, Albin MS, Ritter RR, Bunegin L: CVP catheter placement from the antecubital veins using a J-wire catheter guide. *ANESTHESIOLOGY* 60:238-240, 1984
5. Colley PS, Artru AA: ECG-guided placement of Sorensen CVP catheters via arm veins. *Anesth Analg* 63:953-956, 1984
6. Warner DO, Cucchiara RF: Position of proximal orifice determines electrocardiogram recorded from multiorificed catheter. *ANESTHESIOLOGY* 65:235-236, 1986