

and the severity and frequency of the URI. Those who must be anesthetized should be given supplemental oxygen and have their oxygen saturation monitored in the recovery room and during transport.

REFERENCES

1. McGill WA, Coveler LA, Epstein BS: Subacute upper respiratory infection in small children. *Anesth Analg* 58:331-333, 1979
2. Tait AR, Nahrwold ML, LaBond VA, Knight PR: Anesthesia and upper respiratory viral infection. *ANESTHESIOLOGY* 57:A450, 1982
3. Tait AR, Ketcham TR, Klein MJ, Knight PR: Perioperative respiratory complications in patients with upper respiratory tract infections. *ANESTHESIOLOGY* 59:A433, 1983
4. Tait AR, Knight PR: Intraoperative respiratory complications in patients with upper respiratory tract infections. *Can J Anaesth* 34:300-333, 1987
5. Aldrete JA, Knovich KD: A post anesthetic recovery score. *Anesth Analg* 49:924-934, 1970
6. Berry FA: The child with the runny nose. *Anesthetic Management of Difficult and Routine Pediatric Patients*. New York, Churchill Livingstone, 1986, pp 349-368
7. Glazener C, Motoyama EK: Hypoxemia in children following general anesthesia. *Anesth Analg* 65:267-72, 1986

Anesthesiology
68:279-282, 1988

Pulse Oximeter Desaturation Due to Methemoglobinemia

JAMES B. EISENKRAFT, M.D.*

Pulse oximetry is widely used to provide a continuous estimate of arterial oxygen saturation (SpO_2). Pulse oximeters are inferential monitors. They measure the light absorbance of perfused tissues at two wavelengths (660 and 940 nm) and, from the ratio of the pulse-added absorbance signals at these two wavelengths, use an algorithm to estimate arterial oxygen saturation.^{1,2} Erroneous SpO_2 readings have been reported with the use of dyes^{3,4} and in the presence of carboxyhemoglobin.² A case is reported in which a low SpO_2 reading alerted us to the presence of unsuspected methemoglobinemia.

REPORT OF A CASE

A 20-yr-old woman was scheduled to undergo a total proctocolectomy. Six years prior to this admission, she had bloody diarrhea and abdominal pains and was diagnosed as having ulcerative colitis. She was treated with prednisone and asulfadine. Subsequently, she developed pyoderma of her left hand, which was treated by surgical drainage under uneventful general anesthesia 2 yr prior to this admission. Two months prior to admission, she developed pyoderma gangrenosum of the anterior tibial region bilaterally, and therapy with dapsone was begun. There was nothing else of note in her past medical history. At the time of admission, her medications included only prednisone 20 mg b.i.d. and dapsone 150 mg q.i.d.; the latter drug was discontinued upon admission. On physical examination, the patient was in no appar-

ent distress, was obese (72.72 kg, 160 cm), and had pyoderma of both shins. Arterial blood pressure was 128/70 mmHg, heart rate 100 bpm and regular, and respiratory rate noted as 22 breaths/minute. Physical examination was otherwise unremarkable, and, in particular, there was no evidence of cyanosis. Preoperative laboratory values were within normal limits (hemoglobin 10.9 g/dl, hematocrit 31.7%, blood CO_2 26 mEq/l). Chest radiograph was reported as normal.

On the third day of hospitalization, the patient was premedicated with morphine sulfate, 10 mg im and hydrocortisone, 100 mg iv. Upon arrival to the OR, monitoring was with an EKG, automated blood pressure monitoring device (DinamapTM), and a finger sensor connected to an Ohmeda Biox 3700 pulse oximeter (Ohmeda, Boulder, CO). With the patient awake, supine on the operating table, and breathing room air, the pulse oximeter read an SpO_2 of 89%. The sensor was checked and placed on a finger of the opposite hand, but the SpO_2 reading remained 89-90%. The sensor was placed on the author's finger, and the SpO_2 increased to 97%. The sensor was replaced on the patient's finger, and she was given 100% O_2 to breathe from the anesthesia circle system via a facemask. The pulse oximeter reading increased to, and remained steady at, an SpO_2 of 92-93%. Analysis of arterial blood gases with a FI_{O_2} of 1.0 showed pH_a 7.50, PaCO_2 29 mmHg, PaO_2 587 mmHg, calculated saturation (by nomogram) 99.9%, oxyhemoglobin percentage of total hemoglobin (% HbO_2) by an IL 282 laboratory co-oximeter (Instrumentation Laboratory, Lexington, MA) 92.8%, hemoglobin 10.5 g/dl, and hematocrit 34%. A second arterial sample was analyzed for the presence of dyshemoglobins. Methemoglobin was detected at a percentage concentration of 5%, and carboxyhemoglobin 2.0%, of total hemoglobin. Anesthesia was induced with thiarnylal sodium 300 mg iv, and paralysis was provided by succinylcholine 100 mg iv followed by iv increments of vecuronium. Anesthesia was maintained with $\text{N}_2\text{O}/\text{O}_2$ (41/21), isoflurane, and fentanyl. The anesthetic and surgical courses were uneventful. The trachea was extubated at the end of the procedure and the patient was transferred to the recovery room. While breathing an FI_{O_2} of 0.4 from a face mask, SpO_2 read 94%, pH_a was 7.40, PaCO_2 33 mmHg, PaO_2 139 mmHg, base excess -1.9 mEq/l calculated saturation 98.9%, measured % HbO_2 (by IL 282) 93.4%, methemoglobin 2.9%, and carboxyhemoglobin 0.3%. A blood sample sent for hemoglobin electrophoresis showed a normal pattern. The patient made an uneventful recovery from her surgery and was discharged home 2 weeks later.

* Associate Professor of Anesthesiology, Director of Anesthesia Research.

Received from the Department of Anesthesiology, The Mount Sinai School of Medicine, New York, New York. Accepted for publication August 26, 1987.

Address reprint requests to Dr. Eisenkraft: Department of Anesthesiology, Box 1010, The Mount Sinai Hospital, One Gustave L. Levy Place, New York, New York 10029.

Key words: Blood: methemoglobin. Measurement techniques: pulse oximetry. Monitoring: oxygen.

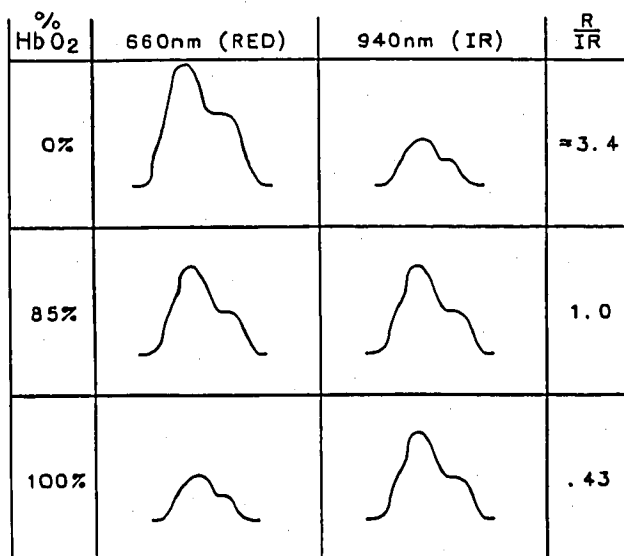


FIG. 1. Relative plethysmographic (pulse-added) signal amplitudes, assuming the transmission intensities are similar.

DISCUSSION

A pulse oximeter reading of 93% is unexpectedly low in a young awake patient breathing an $F_{I_{O_2}}$ of 1.0 and having a $P_{a_{O_2}}$ of 587 mmHg. The low Sp_{O_2} reading in this patient alerted us to the possible presence of dyshemoglobins, which may affect the accuracy of the pulse oximeter because only two wavelengths of light are used in this device.^{1,5}

The Ohmeda Biox 3700 pulse oximeter measures

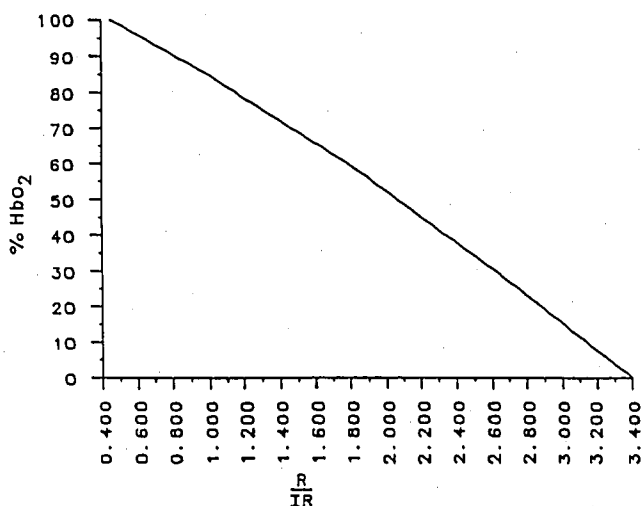


FIG. 2. Algorithm relating %HbO₂ as ordinate to the ratio of the plethysmographic signal amplitudes R/IR (or 660/940 nm), as abscissa.

oxyhemoglobin percentage† (amount of oxyhemoglobin expressed as a percentage of the amount of total hemoglobin) using an empirical algorithm built into the oximeter software. This algorithm was created by measuring the absorbances of light at 660 and 940 nm in the fingers and earlobes of healthy adult volunteers breathing various gas mixtures. At these sites, the light absorbance is constant except for the absorbance by the arterial pulse-added blood volume due to arterial pulsations. The varying pulse-added absorbances are converted into plethysmographic waveforms at the 660 and 940 nm wavelengths. The ratio of the amplitude of the waveform at 660 nm to that at 940 nm is directly related to oxyhemoglobin percentage (fig. 1) under the conditions in which the calibration algorithm was produced. Thus, the ratios of the absorbances at 660 to those at 940 nm were correlated with actual arterial oxyhemoglobin percentages (%HbO₂) as determined by simultaneous arterial blood sampling and measurement using a co-oximeter (fig. 2).² In the case of the Ohmeda Biox 3700, the adult volunteers upon whom the oximeter calibration is based had, on the average, carboxyhemoglobin levels of 1.7% and methemoglobin levels of 0.4% (J. A. Pologe, personal communication). Under these conditions, %HbO₂ is almost identical with the oxygen saturation of available hemoglobin† (total amount of hemoglobin available to bind oxygen, or SaO₂).

The effect of methemoglobin on the Sp_{O_2} reading is explained by reference to the algorithm (figs. 1, 2) and the spectrophotometric absorption characteristics of the hemoglobins present (fig. 3).⁶ In our patient ($P_{a_{O_2}}$ = 587 mmHg), and in the absence of dyshemoglobins, only oxyhemoglobin should be present, the ratio of absorbances 660/940 should be 0.43 (fig. 1), and the Sp_{O_2} should read 100%. The presence of 5% methemoglobin, which, at 660 nm, has an absorbance similar to that of reduced hemoglobin (fig. 3), causes an increase in the absorbance amplitude at 660 nm. Methemoglobin has a qualitatively similar but quantitatively smaller effect on the absorbance amplitude at 940 nm (fig. 3), so that, overall, the ratio of absorbances at 660/940 nm is increased. An increase in the ratio is interpreted as a decrease in %HbO₂, and Sp_{O_2} reads less than 100%.

If the $P_{a_{O_2}}$ were such that both reduced and oxyhemoglobin existed, the 660/940 nm ratio of absorbances would be greater than 0.43 (fig. 2). The additional presence of methemoglobin in this situation would tend to decrease the ratio towards 0.43 because, at 940 nm, methemoglobin has an absorbance greater than either reduced or oxygenated hemoglobins (fig. 3). The effect

† National Committee for Clinical Laboratory Standards, Villanova, PA. Vol 2 No 10, p. 342, 1982.

of decreasing the ratio is to cause an increase in the SpO_2 reading (fig. 2). As the percentage of methemoglobin increases, the 660/940 nm ratio of absorbances tends toward unity, and the SpO_2 approaches 80–85% regardless of the reduced or oxyhemoglobin percentages present.

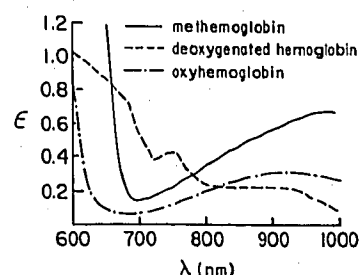
The low SpO_2 readings obtained in our patient were accurate in the presence of 2.9% methemoglobin ($\text{SpO}_2 = 94\%$, $\%\text{HbO}_2 = 93.4\%$) and 5% methemoglobin ($\text{SpO}_2 = 92\text{--}93\%$, $\%\text{HbO}_2 = 92.8\%$), and well within the accuracy (one standard deviation) of 1.5% reported for this device in the range of $\%\text{HbO}_2$ from 90–100%.[‡] However, SpO_2 did not read SaO_2 accurately in the presence of these levels of methemoglobin ($\text{SpO}_2 = 94\%$, $\text{SaO}_2 = 96.5\%$; $\text{SpO}_2 = 92\text{--}93\%$, $\text{SaO}_2 = 100\%$, at 2.9% and 5% methemoglobin, respectively).

Normal red cells contain less than 1% methemoglobin, which is formed when the heme iron in hemoglobin is oxidized from the ferrous to the ferric state. The condition of methemoglobinemia has been defined as existing when more than 1% of total hemoglobin is methemoglobin.⁷ Etiologies may be inherited or acquired. In this patient, the most likely cause was the dapsone therapy received by the patient prior to her admission.⁸ Other drugs and chemicals causing methemoglobinemia include nitrates, nitrites, chlorates, nitrobenzenes, antimalarials, amyl nitrate, nitroglycerine, sodium nitroprusside, prilocaine, benzocaine, and lidocaine.⁹

This patient had a methemoglobin percentage concentration of 5%, actual concentration of 0.525 g/dl ($\text{Hb } 10.5 \text{ g/dl} \times 5\%$), and was not clinically cyanosed. It has been stated⁵ that levels of methemoglobin that are sufficient to cause cyanosis (1.5 g/dl) should not affect the pulse oximeter readings, although no supporting data were provided. While a study quantifying the effects of increasing percentage concentrations of methemoglobin on SpO_2 remains to be reported, the theoretical considerations described indicate that increasing levels of methemoglobin will tend to cause an increase in the SpO_2 reading at low $\%\text{HbO}_2$ (J. A. Pologe, personal communication).

If high percentage concentrations of methemoglobin are present, patients may become symptomatic due to the diminished oxygen-carrying capacity of the blood and greater affinity of the remaining hemoglobin for oxygen (left-shift of the oxygen-hemoglobin dissociation curve). In this patient, the methemoglobinemia resolved spontaneously with cessation of the dapsone therapy. The usual therapy for methemoglobinemia, if indicated, is methylene blue, 1 mg/kg iv.⁷ Methylene

FIG. 3. Absorbance (ϵ) as ordinate plotted against wavelength (λ) for methemoglobin, reduced hemoglobin, and oxyhemoglobin. Data adapted from Van Assendelft OW: Spectrophotometry of Haemoglobin Derivatives. Springfield, Charles C Thomas, 1970, pp 55–60.



blue therapy will, of itself, cause spurious pulse oximeter desaturation, because this dye has a spectral absorption peak at 668 nm.⁴ Spuriously high SpO_2 (as compared to $\%\text{HbO}_2$ measured by the IL 282) readings are obtained in the presence of carboxyhemoglobin, which has recently been quantified in a dog model.²

The pulse oximeter is a valuable non-invasive monitor which, although not required by the Standards for Basic Intra-Operative Monitoring,[§] is by use becoming standard of care. The device is subject to certain limitations, however, and erroneous readings may occasionally be obtained. These are absolute indications for further investigation of the patient's status. If the SpO_2 reading is in doubt, an arterial blood sample should be drawn to confirm PaO_2 , SaO_2 , and $\%\text{HbO}_2$. The latter should be measured by a laboratory co-oximeter which, by reading light absorbance at several wavelengths, can also identify and quantify dyshemoglobins (laboratory co-oximeters, such as the IL 282, are also subject to certain errors and limitations).[¶] Since all pulse oximeters now available function at essentially the same wavelengths, all should be equally affected by similar amounts of methemoglobin.

The author is indebted to Jonas A. Pologe, Manager of Research, Ohmeda, and to Ohmeda for providing technical information (figs. 1, 2), and for reviewing the manuscript.

REFERENCES

1. Yelderman M, New W: Evaluation of pulse oximetry. *ANESTHESIOLOGY* 59:349–352, 1983
2. Barker SJ, Tremper KK: The effect of carbon monoxide inhalation on pulse oximetry and transcutaneous pO_2 . *ANESTHESIOLOGY* 66:677–679, 1987
3. Scheller MS, Unger RJ, Kehler MJ: Effects of intravenously administered dyes on pulse oximetry readings. *ANESTHESIOLOGY* 65:550–552, 1986
4. Kessler MR, Eide T, Humayun B, Poppers PJ: Spurious pulse oximeter desaturation with methylene blue injection. *ANESTHESIOLOGY* 65:435–436, 1986
5. Mihm FG, Halperin BD: Noninvasive detection of profound arterial desaturations using a pulse oximetry device. *ANESTHESIOLOGY* 62:85–87, 1985

[‡] Ohmeda Pulse Oximeter Operating/Maintenance Manual, p. 31, 1986.

[§] Approved by The ASA House of Delegates on October 21, 1986.
[¶] IL 282 CO-Oximeter Manual, p. 1.1, 1985.

6. Van Assendelft OW: Spectrophotometry of Haemoglobin Derivatives. Springfield, Charles C Thomas, 1970, pp 55-60
7. Orkin FK: Acquired methemoglobinemia and sulfhemoglobinemia, Complications in Anesthesiology. Edited by Orkin FK, Cooperman LH. Philadelphia, JB Lippincott Co., 1983, pp 495-504
8. Gilman AG, Goodman LS, Rall TW, Murad F: Goodman and Gilman's The Pharmacological Basis of Therapeutics. New York, Macmillan, 1985, pp 1212-1213
9. Smith RP, Olson MV: Drug-induced methemoglobinemia. *Semin Hematol* 10:253-268, 1973

Anesthesiology
68:282-285, 1988

Transesophageal Atrial Pacing for the Treatment of Dysrhythmias in Pediatric Surgical Patients

WILLIAM J. GREELEY, M.D.,* J. G. REVES, M.D.†

Cardiac dysrhythmias occur frequently in pediatric patients with congenital heart defects during general anesthesia, and may cause hemodynamic instability.¹ Urgent treatment of hemodynamically significant dysrhythmias in children during surgery heretofore has required antiarrhythmic therapy where efficacy is unpredictable. Alternatively, emergency transvenous cardiac pacing, which is highly invasive and technically difficult, is possible. We report two cases where transesophageal atrial pacing was successfully performed in pediatric surgical patients in the treatment of hemodynamically significant dysrhythmias during general anesthesia.

REPORT OF TWO CASES

Case 1. A 4-day-old, 3.1-kg neonate with Ebstein's anomaly (right ventricular dysplasia, tricuspid regurgitation, and Wolff-Parkinson-White syndrome) and pulmonary atresia was anesthetized for a right modified Blalock-Taussig (BT) shunt. At the time of the procedure, the patient had severe hypoxemia due to reduced pulmonary blood flow despite prostaglandin E₁ therapy. Chest radiograph showed cardiomegaly and echocardiogram demonstrated generalized hypertrophy of both ventricles in addition to the abovementioned structural defects. The electrocardiogram showed right atrial enlargement, biventricular hypertrophy, and pre-excitation syndrome (WPW). Prior to surgery, the patient developed several episodes of a wide QRS tachycardia (heart rates 240-260 bpm associated with hypotension) which was diagnosed as a reentrant supraventricular tachycardia (SVT) with antegrade conduction along the accessory pathway. These episodes were initially treated with cardioversion; the patient was then given a loading dose of procainamide (6 mg/kg iv), and a continuous iv infusion of procainamide (50 µg · kg⁻¹ · min⁻¹) was begun. Digoxin was

contraindicated because of the tendency to accelerate conduction in the accessory pathway; propranolol was inadvisable because of the presence of cardiomegaly and signs of congestive heart failure; and verapamil was not administered because of the propensity of this drug to produce significant hypotension in infants. Upon achieving therapeutic levels of procainamide, the episodes of SVT were well controlled.

General anesthesia was induced and maintained with sufentanil (10 µg/kg) and pancuronium (0.1 mg/kg) iv with a FIO₂ of 1.0. Ventilation was controlled, and the patient was placed in a left lateral position for the surgical procedure. In addition to standard noninvasive monitoring, a radial artery catheter was inserted for the continuous measurement of arterial blood pressure and monitoring of arterial blood gases. A 12-French cardioesophagoscope (Portex Inc., Wilmington, MA) was placed in the esophagus to the point of maximal atrial waveform, as previously reported, and used for dysrhythmia detection, as well as auscultation of heart and breath sounds.¹ During dissection of the pulmonary artery and surgical manipulation of the heart, sudden onset of a wide QRS tachycardia at 240 bpm associated with hypotension (mean arterial pressure = 30-35 mmHg) was observed (fig. 1A). Immediate cardioversion was indicated, but internal defibrillation required extension of the incision across the midline and external defibrillation required immediate breakdown of the sterile surgical field. Therefore, an urgent attempt at esophageal pacing was performed. The two esophageal electrode wires at the proximal end of the cardioesophagoscope were attached to a pacing pulse generator, and atrial pacing with the esophageal catheter was begun at a rate of 320 bpm and a pulse width of 3 ms. The current was increased until capture was achieved at 10 mA. The pacing artifact obscured the QRS, and pacing was confirmed by monitoring the arterial pressure waveform. Atrial overdrive pacing was continued for 5 s, and then the pulse generator was turned off. We observed the immediate return of the rhythm to a sinus mechanism at a rate of 150 bpm on the ECG limb leads and the return of the arterial blood pressure to normal (fig. 1B). A second, similar intraoperative episode of SVT was observed and successfully treated in the same manner. The remainder of the operative course was uneventful, and the patient was taken to the pediatric intensive care unit in satisfactory condition.

The postoperative course was marked by persistent respiratory failure due to congestive heart failure and right hemidiaphragm paralysis requiring mechanical ventilation. On the 6th postoperative day, the patient underwent an uneventful fiberoptic bronchoscopy under general anesthesia to determine reversible causes of respiratory failure. At the time of bronchoscopy, the entire esophagus was directly examined through the bronchoscope, and no evidence of esophageal injury was visualized. Because of the paradoxical motion of the paralyzed right diaphragm during spontaneous breathing contributing to ventilatory dependency, the patient was scheduled for a diaphragmatic plication at

* Assistant Professor of Anesthesiology and Pediatrics; Associate in Pediatric Cardiology.

† Professor of Anesthesiology; Director of Cardiac Anesthesia.

Received from the Division of Cardiothoracic Anesthesia, Department of Anesthesiology, Duke University Medical Center, Durham, North Carolina. Accepted for publication August 31, 1987.

Address reprint requests to Dr. Greeley: Department of Anesthesiology, Duke University Medical Center, Box 3094, Durham, North Carolina 27710.

(Key words: Anesthesia: cardiac; pediatric. Complications: dysrhythmia. Heart: pacemakers; transesophageal.)