

Anesthesiology  
67:985-986, 1987

## Anesthesia for an Infant with Severe Hyperinsulinism Treated by Pancreatectomy

MASAO YAMASHITA, M.D.,\* SATORU TSUNETO, M.D.†

Hyperinsulinism, although rare, is considered to be one of the most common causes of severe persistent hypoglycemia in infancy.<sup>1,2</sup> Recently, early surgical treatment for pancreatic hyperinsulinism in infancy has been advocated<sup>2-5</sup> in an effort to prevent mental retardation secondary to severe hypoglycemia. We describe our anesthetic experience associated with subtotal pancreatectomy for hyperinsulinism in an infant.

### CASE REPORT

A 31-day-old, 5.3-kg female infant was to undergo subtotal pancreatectomy for control of hyperinsulinism and hypoglycemia. The infant had an uncomplicated, spontaneous term delivery at a private maternal hospital to a non-diabetic, slightly toxemic mother. Birth weight was 4.0 kg. Attacks of sweating and convulsion associated with severe hypoglycemia (no color changes on Dextrostix<sup>TM</sup>) were first noted at 44 h of age. The attacks recurred despite infusion of 5% glucose in water. At 66 h of age, the infant was transferred to the neonatal ICU. On admission, generalized tonic convulsion was observed, associated with a blood glucose of 21 mg/dL, which was successfully treated by 5 ml of 20% glucose iv. Hypoglycemic episodes recurred until an intravenous glucose infusion rate reached up to 16 mg · kg<sup>-1</sup> · min<sup>-1</sup>. At this rate, blood glucose levels were approximately 60 mg/dL. The plasma insulin level shortly after the admission was excessively high (140 μU/ml; levels of insulin greater than 10 μU/ml in the presence of hypoglycemia are abnormal).

At 5 days of age, oral feeding was started and the glucose infusion rate was reduced slightly. At 14 days of age, a central venous catheter was placed via the subclavian vein for infusion of hypertonic glucose solution. General anesthesia was induced with ketamine and succinylcholine, and maintained with nitrous oxide and d-tubocurarine.

No clinical or laboratory improvement was observed following oral diazoxide (8-10 mg · kg<sup>-1</sup> · day<sup>-1</sup>). Glucose infusion rate was maintained around 12 mg · kg<sup>-1</sup> · min<sup>-1</sup>. Subtotal pancreatectomy was scheduled at 31 days of age. Oral diazoxide was continued until the morning of the surgery.

An arterial line was inserted in the evening before the surgery for frequent blood glucose determinations and continuous blood pressure monitoring. In addition to the central line, through which 12 mg · kg<sup>-1</sup> · min<sup>-1</sup> of glucose was infused, a peripheral venous line was established preoperatively. No premedication was administered. At the induction of anesthesia, the arterial blood pressure was 74/59 mmHg, heart rate 140 bpm, and blood glucose 72 mg/dL. While

breathing 100% oxygen, anesthesia was induced with atropine 0.1 mg, and ketamine 10 mg iv, following which arterial blood pressure increased to 103/78 mmHg. Orotracheal intubation was accomplished with succinylcholine 10 mg iv, and anesthesia was maintained with 0.2-0.4% enflurane, 67% nitrous oxide in 33% oxygen, and continuous infusion of d-tubocurarine (3 μg · kg<sup>-1</sup> · min<sup>-1</sup>) for 10 h. Arterial blood glucose and insulin were measured at frequent intervals (fig. 1). At no time did laboratory or clinical evidence of hypoglycemia develop. Infusion of glucose was maintained at 12 mg · kg<sup>-1</sup> · min<sup>-1</sup> until the removal of 95% of the pancreas, then the rate was reduced to 8 mg · kg<sup>-1</sup> · min<sup>-1</sup> (fig. 1). Severe bleeding occurred from the splenic vessels, and splenectomy was performed. The intraoperative blood loss reached 700 ml, which was replaced with 400 ml of packed red cells and 320 ml of fresh frozen plasma. In addition, 660 ml of lactated Ringer's solution was infused during anesthesia. At the end of anesthesia, neuromuscular blockade was not antagonized, and the orotracheal tube was replaced with a nasotracheal tube to facilitate postoperative mechanical ventilation.

Postoperatively, the infant experienced transient hyperglycemic rebound (maximum blood glucose 489 mg/dL), which was treated with an iv insulin infusion. Pathological examination of resected specimens showed diffuse nesidioblastosis (proliferation of islet cells arising from the pancreatic ductular tissue).

Starvation test on 20th postoperative day revealed an almost normal insulin response without hypoglycemia after 8 h.

### DISCUSSION

The maintenance of adequate blood glucose levels during the preoperative and operative period is of primary importance in the anesthetic management of hyperinsulinism in infants, as well as in adults. In adult cases of insulinoma, limiting glucose infusion rate<sup>6</sup> to 1.7 mg · kg<sup>-1</sup> · min<sup>-1</sup>, or even withholding glucose infusion<sup>7</sup> during surgery, has been advocated. However, in our case, glucose infusion rate of 12 mg · kg<sup>-1</sup> · min<sup>-1</sup> was necessary to maintain adequate blood glucose levels during the operation, at least before the manipulation of the pancreas. Because the immediate danger related to hypoglycemia exceeds that related to hyperglycemia, we think that glucose should be infused at the same rate, at least initially, during anesthesia and surgery. Infusion rate can be adjusted according to the intraoperative blood glucose responses.

A number of pharmacologic agents, including corticosteroids, diazoxide,<sup>1,8</sup> glucagon,<sup>9</sup> growth hormone,<sup>10</sup> somatostatin,<sup>9</sup> and diltiazem,<sup>11</sup> have been used to prevent hypoglycemia preoperatively in hyperinsulinism. Diazoxide, a nondiuretic benzothiazide derivative with potent vasodilator activity, has a direct inhibitory action on release of pancreatic insulin. Burch and McLeskey<sup>6</sup>

\* Anesthetist-in-Chief.

† Chief Resident in Anesthesia.

Received from the Department of Anesthesia, Ibaraki Children's Hospital, 3-3-1, Futaba-dai, Mito, 311-41, Japan. Accepted for publication June 1, 1987.

Address reprint requests to Dr. Yamashita.

Key words: Anesthesia; pediatric. Hormones: insulin. Metabolism: diazoxide; hyperinsulinism; hypoglycemia. Surgery: pancreatectomy.

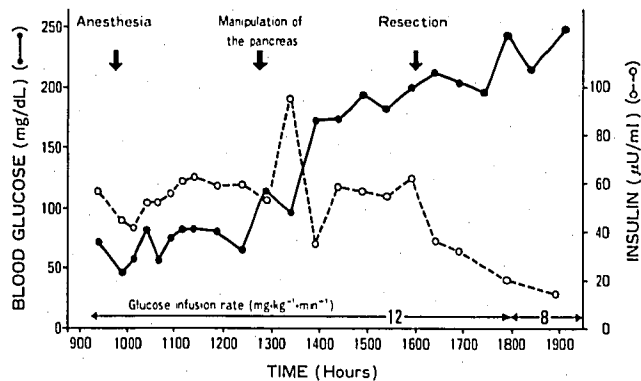


FIG. 1. Blood glucose, plasma insulin levels, and glucose infusion rate during surgical resection of the pancreas for hyperinsulinism in an infant.

reported marked hypotensive episodes related to thiopental induction in two patients with hyperinsulinism treated with oral diazoxide, and postulated drug interactions at plasma protein binding sites. A bolus of thiopental could displace diazoxide from its protein binding sites, thereby releasing pharmacologically active diazoxide to attach to arterial smooth muscle receptor sites.<sup>6</sup> We have previously reported the safe use of ketamine for induction in a 1-y-and-8-month-old boy with hyperinsulinism treated with oral diazoxide.<sup>12</sup> In our case, no hypotensive episode occurred after ketamine induction of anesthesia. Thus, ketamine may be preferred to thiopental as an induction agent for pediatric patients treated with diazoxide. Other side effects of diazoxide include congestive heart failure<sup>8</sup> due to water retention, and extrapyramidal symptoms.<sup>8</sup> Preoperative water retention and excessive iv water leading to cardiac failure must be carefully watched for in infants with hyperinsulinism treated with diazoxide and high-dose glucose infusion. Although there are no reports of worsening of extrapyramidal symptoms caused by diazoxide combined with droperidol, it may be prudent to avoid droperidol in this situation.

In summary, an anesthetic experience of subtotal

pancreatectomy for infantile hyperinsulinism is reported. Ketamine induction seemed to prevent the hypotensive episode reported to occur with thiopental induction in patients treated with diazoxide. Frequent determinations of blood glucose are essential, and, in our infant case, a much higher intraoperative glucose infusion rate was required than that reported in adult cases.

The authors are grateful to Dr. Takeki Hirano for his thoughtful review.

## REFERENCES

1. Stanley CA, Baker L: Hyperinsulinism in infants and children: Diagnosis and therapy. *Adv Pediatr* 23:315-355, 1976
2. Schiller M, Krausz M, Meyer S, Lijovetzky G, Landau H: Neonatal hyperinsulinism—Surgical and pathological considerations. *J Pediatr Surg* 15:16-20, 1980
3. Carcassonne M, DeLarue A, LeTourneau JN: Surgical treatment of organic pancreatic hypoglycemia in the pediatric age. *J Pediatr Surg* 18:75-79, 1983
4. Langer JC, Filler RM, Wesson DE, Sherwood G, Cutz E: Surgical management of persistent neonatal hypoglycemia due to islet cell dysplasia. *J Pediatr Surg* 19:786-792, 1984
5. Gough MH: The surgical treatment of hyperinsulinism in infancy and childhood. *Br J Surg* 71:75-78, 1984
6. Burch PG, McLeskey CH: Anesthesia for patients with insulinoma treatment with oral diazoxide. *ANESTHESIOLOGY* 55:472-475, 1981
7. Suffecool SL: Anesthetic management for insulinoma resection, *Anesthesia and the Patient with Endocrine Disease*. Edited by Brown B. Philadelphia, FA Davis, 1980, pp 11-17
8. McGraw ME, Price DA: Complications of diazoxide in the treatment of nesidioblastosis. *Arch Dis Child* 60:62-64, 1985
9. Bougneres PF, Landier F, Garnier P, Job JC, Chaussain JL: Treatment of insulin excess by continuous subcutaneous infusion of somatostatin and glucagon in an infant. *J Pediatr* 106:792-794, 1985
10. Hocking MD, Newell SJ, Payner PHW: Use of human growth hormone in treatment of nesidioblastosis in a neonate. *Arch Dis Child* 61:706-707, 1986
11. Taniguchi H, Murakami K, Morita S, Kazumi T, Yoshino G, Maeda M, Baba S: Calcium antagonist (diltiazem) for reversal of hypoglycaemic symptoms in insulinoma. *Lancet* II:501, 1977
12. Yamashita M, Motokawa K, Hirano T: Ketamine induction for a patient with hyperinsulinism treated with oral diazoxide (correspondence). *Can Anaesth Soc J* 33:685-686, 1986