

## Use of an Endotracheal Tube Without Radiopaque Marker for Cervical CT-scans

*To the Editor:*—We have anesthetized several pediatric patients undergoing cervical CT-myelography. One radiologist asked whether the beam-hardening artifact

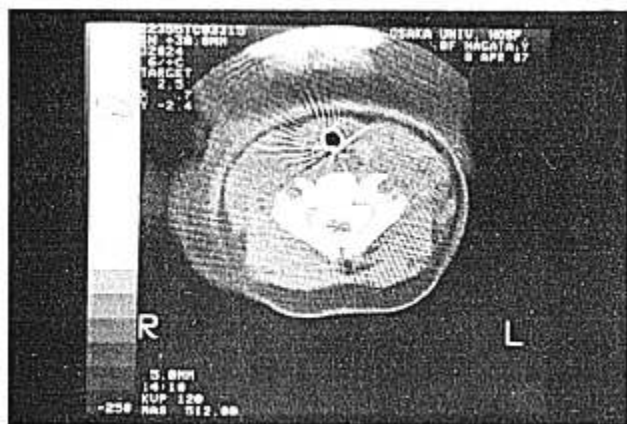


FIG. 1. Transverse CT-scan of cervical myelography at C5 level. The artifact is observed to radiate from radiopaque marker of the tracheal tube.

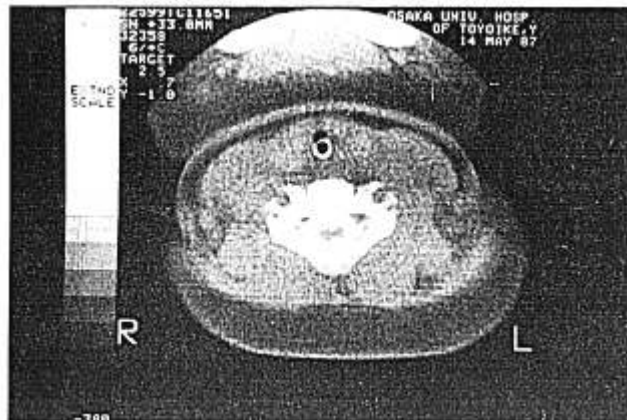


FIG. 2. Transverse CT-scan of cervical myelography at C5 level in a different patient. No artifact was observed when our hand-made tube was used.

or the fringe radiating from the endotracheal tube (fig. 1) could be reduced to obtain clear CT-scans. The artifact was assumed to be originating from the x-ray detectable marker of the tracheal tube (Blueline, Portex, England). However, a tracheal tube without a radiopaque marker was not available, inasmuch as ISO 5361/1-1984 stated that tracheal tubes should be readily detectable by x-ray either by the nature of the material of which they are made or by the provision of a marker on the tube.\* Therefore, we decided to use commonly used esophageal stethoscopes (Portex, England) for tracheal tubes. The esophageal stethoscope made of polyvinyl chloride was cut to an appropriate length. They were kept in a curved position for 4 h while the plasticizer was eluted with anhydrous alcohol. After the tubes had become rigid and set in a curved position, the bevel's surface was smoothed by treatment with tetrahydrofuran. Our special tubes did not interfere with CT-scans (fig. 2). We suggest the use of endotracheal tubes without the radiopaque marker in cases such as that described above.

\* International Organization for Standardization: Tracheal tubes—Part 1: General Requirements. ISO 5361/1-1984(E), First edition, 1984, pp 1-3

CHIKARA TASHIRO, M.D.  
*Associate Professor*

MASAHARU YAGI, M.D.  
*Instructor*

*Department of Anesthesiology  
Osaka University Medical School  
Osaka 553, Japan*

HISAO KINOSHITA  
*Technical Manager and Clinical Engineer  
Japan Medico Co., Ltd.  
Nagoya 465, Japan*

(Accepted for publication September 1, 1987.)

## Epidural Anesthesia and Analgesia in High-risk Surgical Patients. I.

*To the Editor:*—As a surgeon, I have long been interested in the reduction of surgical complications, but available measures are few and, generally, only margin-

ally effective. Both the recent article by Yeager *et al.*<sup>1</sup> and its accompanying editorial<sup>2</sup> suggest a major advantage of epidural anesthesia and analgesia in high-risk