

injected drugs or fluids. Sensitivity occurs infrequently, and a sensitivity test just prior to use has been advised.⁹ Hyaluronidase has been studied as an adjuvant for epidural analgesia.¹⁰ The use of 125 units of hyaluronidase in 25 ml 2% lidocaine with epinephrine 1/200,000 was associated with a decrease in both intensity and duration of neural blockade. In fact, the quality of analgesia with hyaluronidase was inadequate for surgery. This study demonstrated that hyaluronidase, rather than enhancing neural uptake of drugs from the epidural space, effected a dramatic reduction of concentration of local anesthetic at its spinal site of action. The effect of hyaluronidase on increasing the overall vascular uptake of a drug has been amply demonstrated by Mushin.¹¹ He showed that intramuscular gallamine with hyaluronidase had a five-fold faster onset time with double the intensity of neuromuscular block than the equivalent im dose of gallamine without hyaluronidase.

In conclusion, accidental drug administration into the epidural space is a rare problem which has caused severe neurological damage. We describe a case in which no neurologic sequelae followed a mistaken epidural administration of 1% methohexital. Treatment consisted of dilution in combination with steroid and hyaluronidase administration, the effectiveness of which is impossible to evaluate.

Anesthesiology
67:848-851, 1987

REFERENCES

1. Lin D, Becker K, Shapiro HM: Neurologic changes following epidural injection of potassium chloride and diazepam: A case report with laboratory correlations. *ANESTHESIOLOGY* 65:210-212, 1986
2. Shanker KB, Palkar NV, Nishkala R: Paraplegia following epidural potassium chloride. *Anaesthesia* 40:45-47, 1985
3. Forestner JE, Raj PP: Inadvertent epidural injection of thiopental: A case report. *Anesth Analg* 54:406-407, 1975
4. Bromage PR: Epidural Analgesia. Philadelphia, WB Saunders, 1978, p 662
5. Usubiaga JE: Neurological complications following epidural analgesia. *Int Anesth Clin* 13(2):19,50, 1975
6. Steen PA, Michenfelder JD: Neurotoxicity of anesthetics. *ANESTHESIOLOGY* 50:437-453, 1979
7. Macintosh RR, Heyworth PSA: Intra-arterial injection of pentothal. *Lancet* (2)571, 1943
8. Van der Post CWH: Report of a case of mistaken injection of pentothal sodium into an aberrant ulnar artery. *Anesth Analg* 21:58-59, 1942
9. Marshall BE, Woollman H: General anesthetics. *The Pharmacological Basis of Therapeutics*, 6th edition. Edited by Goodman, Gillman. New York, MacMillan, 1980, p. 960-961
10. Bromage PR, Burfoot MF: Quality of epidural blockade: Influence of physicochemical factors: Hyaluronidase and potassium. *Br J Anaesth* 38:857-864, 1966
11. Mushin WW: Intramuscular gallamine with hyaluronidase. *Anaesthesia* 11:135-137, 1965

Air Embolism Associated with Veno-venous Bypass during Orthotopic Liver Transplantation

GEORGE F. KHOURY, M.D.,* MARTIN E. MANN, M.D.,† MARC J. POROT, M.D.,‡
IMAD H. ABDUL-RASOOL, M.D., PH.D.,* RONALD W. BUSUTTIL, M.D., PH.D.‡

Prior to 1982, the anhepatic phase of orthotopic liver transplantation (OLT) was performed by cross-clamping the inferior vena cava (IVC) and portal vein. This resulted in significantly decreased venous return with subsequent decreases in cardiac output. Concomitantly, the venous pressure in the portal circulation was in-

creased, leading to visceral engorgement and the possibility of bowel ischemia, as well as increased bleeding from the adhesions of previous surgeries. The introduction of non-heparinized veno-venous bypass decreased the morbidity and mortality of OLT by partially restoring the cardiac output and decreasing visceral bleeding.¹ The portal vein and IVC are drained by cannulae which are connected to a centrifugal force pump, and venous flow is returned to the superior vena cava *via* the left axillary vein (fig. 1).

Liver transplantation is a technically difficult procedure for both surgeons and anesthesiologists; many opportunities for complications present themselves. An incident possibly due to venous air embolism (VAE) resulting in severe hemodynamic deterioration during OLT has previously been described, although not related to veno-venous bypass.² We wish to report a case

* Assistant Professor of Anesthesiology.

† Fellow in Anesthesiology.

‡ Professor of Surgery.

Received from the Departments of Anesthesiology and Surgery, University of California, Los Angeles, California. Accepted for publication June 17, 1987.

Address reprint requests to Dr. Khoury: Department of Anesthesiology, UCLA School of Medicine, 10833 Le Conte Avenue, Los Angeles, California 90024.

Key words: Embolism: air. Surgery: liver transplantation.

of air embolism resulting in cardiovascular deterioration using veno-venous bypass.

REPORT OF A CASE

A 57-yr-old woman with a diagnosis of chronic active non-A non-B viral hepatitis was scheduled for OLT. Anesthesia was induced with thiamylal and succinylcholine iv, and was maintained by inhalation of isoflurane, nitrous oxide, O₂, and iv fentanyl. Monitors included radial artery and flow-directed pulmonary artery catheters, ECG, esophageal stethoscope, and analysis of inspired and expired gases using a mass spectrometer. Use of a precordial doppler to monitor VAE is not possible in OLT due to the extensive surgical preparation of chest and abdomen. Despite the typical blood loss encountered during the dissection phase of the operation (2300 ml over a 3-h period), the patient was hemodynamically stable prior to venous bypass (systemic blood pressure 120/70 mmHg, pulmonary artery [PA] pressure 28/15 mmHg, central venous pressure 10 mmHg). After approximately 2 min of partial veno-venous bypass (fig. 1), arterial systolic and pulse pressures dropped rapidly (*i.e.*, 70/65 mmHg) and pulmonary artery pressures increased (*i.e.*, 70/55 mmHg) (fig. 2). Inspection of the veno-venous bypass by the perfusionist revealed no obvious abnormality with flow maintained at 2 l/min. The bypass pump was stopped empirically, and large amounts of air were noted to be present in the pump head, as well as both inlet and outlet cannulae. Nitrous oxide was discontinued, and the patient placed in Trendelenburg position with left lateral tilt. End-tidal CO₂ was noted to be decreased significantly (fig. 3). Vasopressors were administered with gradual improvement of the patient's hemodynamic status, which returned to within normal limits within 5 min. No apparent source of embolism was discovered. After evacuation of air from the pump system, the patient was cautiously placed on total veno-venous bypass (IVC and portal vein to left axillary vein). After completion of suprahepatic and infrahepatic vena caval anastomoses, the portal vein was clamped and its cannula was removed to allow for the portal vein anastomosis. Hemodynamic changes similar to the previous embolism were noted, and the pump was stopped. Air was once again noted in the pump, and the patient was treated with Trendelenburg position and left lateral tilt, resulting in hemodynamic values returning to normal within 8 min; vasopressors were not required. In both instances of embolism, attempts were made at air recovery by aspirating both central venous and PA ports of the pulmonary artery catheter. All attempts at aspirating air were unsuccessful, except for the recovery of 2 ml of air from the central venous port during the second occurrence of embolism. As the venous bypass apparatus was removed, the clamp holding the portal vein cannula was noted to be defective, allowing air entrainment. The procedure continued without bypass and without further incident. The trachea was extubated the following day, and the patient was discharged from the hospital 6 weeks later with no apparent neurological, cardiac or pulmonary sequelae.

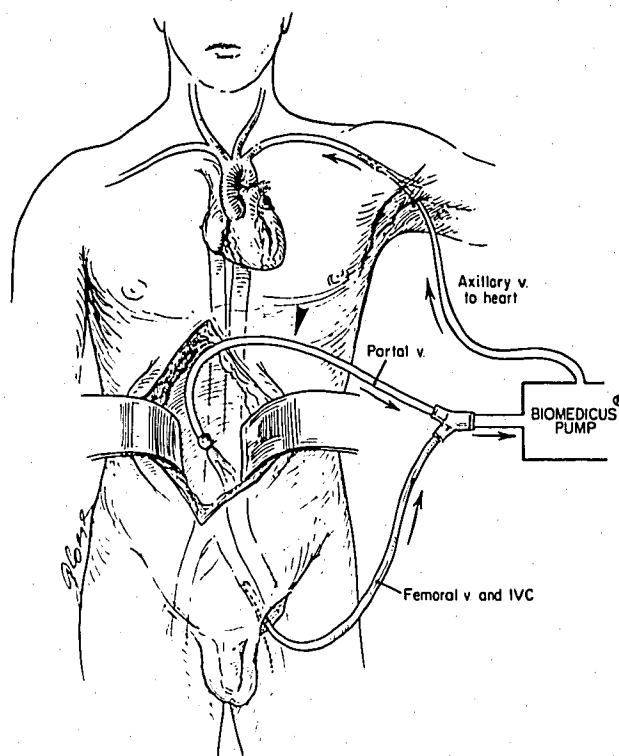


FIG. 1. Veno-venous bypass. Cannulae placed in the IVC and portal veins join and their drainage is directed to a centrifugal force pump. Blood is returned to the systemic venous circulation via the left axillary vein. Partial bypass is IVC to axillary vein drainage. Total bypass is IVC plus portal vein to axillary vein drainage.

DISCUSSION

Cross-clamping of the portal vein and IVC during OLT results in decreased venous return and cardiac output, hypertension of portal and systemic venous beds, and release of acidic metabolites from the lower extremities and viscera when the cross-clamps are removed.¹ In the absence of venous bypass, surgery during the anhepatic period is rushed to minimize hemodynamic instability and venous congestion of structures drained by the portal circulation.³ In an effort to allevi-

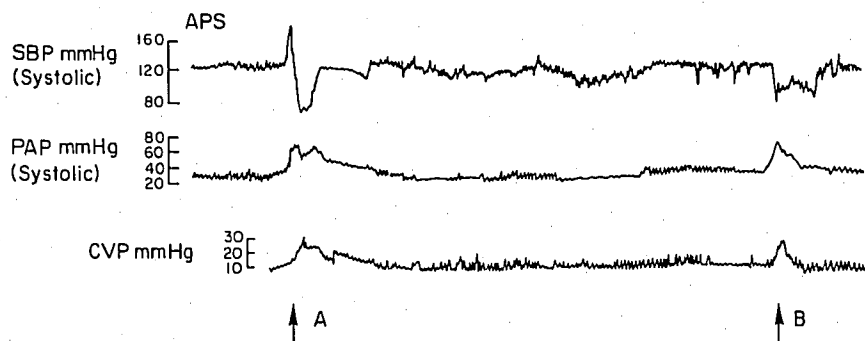


FIG. 2. Trend recordings of arterial systolic pressure (asp), pulmonary artery systolic pressures (pas), and central venous pressures (cvp) illustrating changes during the episodes of venous air embolism (arrows). The time interval between the two episodes of embolism is approximately 95 min.

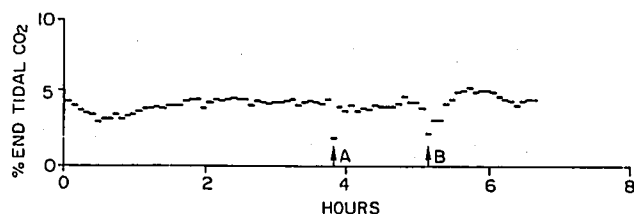


FIG. 3. Trend recording of end-tidal CO₂ measurements illustrating the marked decreases during the episodes of venous air embolism.

ate these problems, bypass of the portal vein and IVC to the external jugular veins *via* passive shunts (*i.e.*, without pump) has been attempted, resulting in an unacceptably high incidence of thrombotic pulmonary embolism.⁴ Femoral artery to femoral vein partial cardiopulmonary bypass was introduced in 1975;⁵ however, systemic heparinization is required, and this technique does not decompress the portal circulation. Venous bypass using a cardiotomy reservoir and roller head pump also requires systemic heparinization in these patients with pre-existing coagulopathies, and intraoperative deaths from uncontrolled hemorrhage have occurred.³ These experiences have led to the current technique of veno-venous bypass routinely used during adult OLT in most centers. Developed and refined by Shaw *et al.*,¹ it consists of portal venous and IVC drainage to a centrifugal blood pump at flows of 1.5–6 l/min and return to an axillary vein. Heparin bonded shunt tubing successfully retards thrombus formation, and systemic heparinization is not necessary. Shaw *et al.* have reported a series of 57 liver transplant patients using this technique with consequent stable intraoperative hemodynamics, decreased intraoperative blood loss, improved postoperative renal function, and increased 30-day patient survival.¹ No major complications resulting from the bypass procedure were reported.

The blood pump used (Bio-Console® 520C, Bio-Medicus, Inc., Minnetonka, MN) functions on a centrifugal force-vortex pumping principle. Blood is rotated in a cone creating an area of relative reduced pressure in the center into which the venous drainage is directed; relative increased pressure occurs at the periphery of the base of the cone, and blood flows from here to the axillary vein. Although the manufacturer cautions against introduction of air into the system, it is claimed that small volumes of air may be trapped within the center of the vortex, while large volumes of air will produce a vapor lock in the tubing with cessation of flow (Bio-Console model 520 series operator's manual, Biomedicus, Inc.). We have found that the pump is capable of introducing enough air into the venous system to cause cardiovascular compromise in less than 2 min. Presumably air entrained in the venous drainage was

disrupted into micro-bubbles at the pump head, where the pump rotates up to 4000 RPM, and returned to the patient in an air-blood slurry.

A disturbing aspect of this cause of air embolism is that the entrained air is not visible to operating room personnel due to the opaque heparin bonded tubing and the rapid rotation of the blood within the pump head. Only after our patient's hemodynamic deterioration led us to empirically discontinue bypass did it become evident that air was present in the system. While it is possible to add a cardiotomy reservoir to trap air, this is not compatible with a non-heparinized system, which must be as streamlined as possible to avoid thrombus formation. Rather than change the bypass structure, we feel it is sufficient to realize that this potential complication exists. Surgeons must take special care to ensure that the cannulae connections are air-tight, and anesthesia personnel must continually monitor for signs of air embolism.

Although nitrous oxide was used to augment anesthesia in this case report, we have come to believe that the hazards of N₂O administration during veno-venous bypass are significant. Embolic air is in intimate contact with blood containing N₂O; therefore, intravascular gas volume increases at a much greater rate than in any other gas cavity. In addition, air bubbles embolized in the pulmonary prearteriolar capillaries are believed to be enlarged by alveolar N₂O.⁶ We do not know how much effect embolus expansion had on our patient's hemodynamic status, but it is conceivable that it was significant.

Another concern is the possibility of paradoxical systemic embolization through a probe patent foramen ovale or through the pulmonary circulation. A recent canine study has shown that 0.40 ml · kg⁻¹ · min⁻¹ of air introduced into the venous system results in the transpulmonary passage of air in 71% of cases;⁷ given our patient's hemodynamic response, we assume that the rate of VAE exceeded 0.40 ml · kg⁻¹ · min⁻¹. Additionally, patients with chronic liver disease are at an increased risk of paradoxical embolization due to the greater incidence of arteriovenous anastomoses in the lung.⁸ It is of interest that no evidence of postoperative morbidity from systemic embolization was noted in our patient. This is consistent with a recent report of 255 neurosurgical procedures in which VAE was not found to be a significant factor in perioperative morbidity and mortality, despite the fact that VAE was detected in 77 of these procedures.⁹

The final aspect of this case concerns the efficacy of the pulmonary artery catheter in removing venous embolic air. Previous reports have indicated that only small amounts of air can be recovered from either the central venous or PA ports of a pulmonary artery catheter.^{10–12}

In a prospective study of neurosurgical procedures, Marshall and Bedford¹¹ have speculated that early detection of VAE prompted attempts at air removal before large volumes were embolized, and, hence, only small amounts were recoverable. They suggested that a pulmonary artery catheter is useful for both the diagnosis and treatment of VAE. In our case of VAE, we were also unable to remove significant amounts of air from either the central venous or PA ports of the pulmonary artery catheter, and must conclude that this is not an effective therapeutic modality.

In summary, we have found that significant air embolism is possible in the system of veno-venous bypass most frequently used in OLT; surgeons, anesthesiologists, and perfusionists should be aware of this possibility for adequate prevention, monitoring, and therapy. The risks of N₂O use during veno-venous bypass appear to outweigh its benefits, and, while a pulmonary artery catheter is effective in detecting VAE, it should not be relied on as an effective method of removing embolized venous air.

REFERENCES

1. Shaw BW, Martin DJ, Marquez JM, Kang YG, Bugbee AC, Iwatsuki S, Griffith BP, Hardesty RL, Bahnson HT, Starzl TE: Venous bypass in clinical liver transplantation. *Ann Surg* 200:524-534, 1984
2. Kutt JL, Gelb AW: Air embolism during liver transplantation. *Can Anaesth Soc J* 31:713-715, 1984
3. Shaw BW, Martin DJ, Marquez JM, Kang YG, Bugbee AC, Iwatsuki S, Griffith BP, Hardesty RL, Bahnson HT, Starzl TE: Advantages of venous bypass during orthotopic transplantation of the liver. *Semin Liv Dis* 5:344-348, 1985
4. Starzl TE, Marchioro TL, Von Kaulla KN, Hermann G, Brittain RS, Waddall WR: Homotransplantation of the liver in humans. *Surg Gynecol Obstet* 117:659-676, 1963
5. Calne RY, Smith DP, McMaster P, Craddock GN, Rolles K, Farman JV, Lindop M, Bethune DW, Wheeldon D, Gill R, Williams R: Use of partial cardiopulmonary bypass during the anhepatic phase of orthotopic liver grafting. *Lancet* 2:612-614, 1979
6. Munson ES: Effect of nitrous oxide on the pulmonary circulation during venous air embolism. *Anesth Analg* 50:785-793, 1971
7. Butler BD, Hills BA: Transpulmonary passage of venous air emboli. *J Appl Physiol* 59:543-547, 1985
8. Bertholot P, Walker JG, Sherlock S, Reid L: Arterial changes in the lungs in cirrhosis of the liver-lung spider nevi. *New Engl J Med* 274:291-297, 1966
9. Young ML, Smith DS, Murtagh F, Vasquez A, Levitt J: Comparison of surgical and anesthetic complications in neurosurgical patients experiencing venous air embolism in the sitting position. *Neurosurgery* 18:157-161, 1986
10. Munson ES, Paul WC, Perry JC: Early detection of venous air embolism using a Swan-Ganz catheter. *ANESTHESIOLOGY* 42:223-226, 1975
11. Pershau RA, Munson ES, Chapin JC: Pulmonary interstitial edema after multiple venous air emboli. *ANESTHESIOLOGY* 45:364-368, 1976
12. Marshall WK, Bedford RF: Use of a pulmonary-artery catheter for detection and treatment of venous air embolism: A prospective study in man. *ANESTHESIOLOGY* 52:131-134, 1980

Anesthesiology
67:851-853, 1987

Sensitivity of the Adductor Pollicis and Diaphragm Muscles to Atracurium in a Hemiplegic Patient

J. R. D. LAYCOCK, B.A., M.Sc., F.F.A.R.C.S.,* C. E. SMITH, B.Sc., M.D.,†
F. DONATI, Ph.D., M.D., F.R.C.P. (C),‡ D. R. BEVAN, M.B., M.R.C.P., F.F.A.R.C.S.§

Resistance to the action of non-depolarizing muscle relaxants (NDMRs) occurs in patients with upper motor neuron lesions,^{1,2} and may extend to the normal, as well

as the paretic, limbs.³ Disuse atrophy is also associated with resistance to NDMRs. In dogs, decreased sensitivity to pancuronium has been found in an immobilized leg compared with the contralateral limb.⁴ The diaphragm is normally resistant to the action of NDMRs,^{5,6} and, in guinea pigs' diaphragm, sensitivity to d-tubocurarine does not change with limb immobilization.⁷ Thus, it might be predicted that the sensitivity of the diaphragm may be normal in patients who are hemiplegic because of a cerebrovascular accident.

We report a case where neuromuscular function was monitored at the diaphragm and at both adductor pollicis muscles in a patient with hemiplegia. Dose-response curves of atracurium were determined at these three sites.

* Clinical Fellow.

† Chief Resident.

‡ Assistant Professor.

§ Professor and Chairman.

Received from the Departments of Anaesthesia, Royal Victoria Hospital and McGill University, Montreal, Quebec, Canada. Accepted for publication June 17, 1987.

Address reprint requests to Dr. Donati: Royal Victoria Hospital, Department of Anaesthesia, Room S5.05, 687 Pine Avenue West, Montreal, Quebec, Canada, H3A 1A1.

Key words: Brain: hemiplegia; stroke. Neuromuscular relaxants: atracurium.