

Anesthesiology
67:255-257, 1987

Endobronchial Intubation: A Preventable Complication

ROBERT L. OWEN, M.B.A., R.R.T.,* FREDERICK W. CHENEY, M.D.†

A major complication of endotracheal intubation is accidental migration of the tube tip into a mainstem bronchus. If unrecognized, endobronchial intubation can lead to hypoxemia secondary to collapse of the contralateral lung and hyperinflation of the intubated lung with resultant tension pneumothorax. In the ICU setting, poor radiographic placement relative to the carina has been reported in a number of studies,¹⁻⁶ with a significant increase in morbidity due to right mainstem intubation reported in one.¹ The standard bedside method for diagnosis of endobronchial intubation is bilateral auscultation of the chest. This is not always satisfactory, as breath sounds can be transmitted to the opposite side of the chest in the presence of endobronchial intubation.⁷

We designed a study to test the hypothesis that proper placement of the tip of an oral endotracheal tube with respect to the carina could be accomplished by referencing the measurements printed on the tube's side.

METHODS

We studied 578 adult patients admitted to our 22-bed multidisciplinary adult Critical Care Center (CCC). There were 388 men and 190 women entered into the study. The majority of these were postoperative open heart patients who had been intubated in the operating room. A few endotracheal intubations were performed elsewhere in the hospital on a more emergent basis. Of this total, 304 were assigned to the study group and 263 to the control group. We arbitrarily defined the "normal range" of height as 168-184 cm in males and

158-174 cm in females.⁸ Data collected on patients whose height fell outside of these ranges was excluded.

In the study group, endotracheal tubes in men were positioned at the 23-cm mark measured at the upper incisor teeth, and women had their endotracheal tubes positioned at the 21-cm mark.⁹ Endotracheal tubes in edentulous patients were similarly positioned, using the upper anterior gums as reference. The endotracheal tubes of all study group patients were positioned immediately after their admission to the CCC by respiratory therapists prior to the initial post-intubation chest radiograph.

Patients enrolled in the study were initially intended to be randomized into either the study or control groups. However, patients randomly assigned to both groups began arriving in the ICU from surgery with their endotracheal tubes correctly pre-positioned according to the study group protocol. The anesthesia housestaff, informed of our project, began placing the tubes of all patients according to our experimental protocol, thus skewing the results. In order to avoid bias, we then reviewed historical records and chest radiographs of all patients who had been admitted to the CCC the previous year.

In evaluating endotracheal tube position relative to the carina, no attempt was made to correct the measured distance for radiologic magnification. The radiograph was always taken anterior-posterior with the patient in the supine or semi-recumbent position, and no attempt was made to standardize the head position as the radiograph was taken. Of the 578 patients enrolled, 11 were excluded due either to poor visual clarity of the film or because the patient fell outside of our predetermined height parameters. We used Goodman's criteria,[‡] according to which the ideal position of the endotracheal tube within the trachea is 5 ± 2 cm (mean \pm SD) from the carina. This radiographic measurement was uncorrected for magnification, and made with the head in the neutral position.[‡]

Continuous variables were summarized as mean \pm SD and range. Student's unpaired *t* test was used to compare means. Frequency histograms of endotracheal

* Senior Clinical Specialist, Physio-Control Corporation; and Supervisor, Respiratory Care Services, University Hospital.

† Professor, Anesthesiology, University of Washington, School of Medicine; and Director, Critical Care Center and Respiratory Care Services, University Hospital.

Received from the Physio-Control Corporation, Redmond, Washington; the University of Washington, School of Medicine, Seattle, Washington; and the Critical Care Center and Respiratory Care Services, University Hospital, Seattle, Washington. Accepted for publication March 5, 1987.

Address reprint requests to Dr. Cheney: Department of Anesthesiology, University of Washington, School of Medicine RN-10, Seattle, Washington 98195.

Key words: Intubation; endobronchial; endotracheal.

‡ Goodman LR, Conrardy PA, Laing F, Singer MM: Radiographic evaluation of endotracheal tube position. *Am J Roentgenol* 127:433-434, 1976

TABLE 1. Patient Height

	National Average	Control Group	Study Group	Range: Control and Study Groups
Men	172 cm	173 ± 4 cm	173 ± 4 cm	168-184 cm
Women	162 cm	163 ± 3 cm	162 ± 3 cm	158-174 cm

Mean values ± SD for patient height in control and study groups.

tube distance from the carina were constructed using class intervals of 1.0 cm. Differences in frequency between the control and study groups were tested using chi-square analysis with Yates' correction for continuity. A significance level of $P < 0.05$ was used throughout.

RESULTS

There was no difference between the heights of patients in the study group and control group ($P < .01$) (table 1). The mean distance of the endotracheal tube tip from the carina of the study group was 6.2 ± 1.4 cm (mean ± SD), and 4.8 ± 1.6 cm for the control group ($P < .001$). In the 263 control patients, there were seven right mainstem intubations; in eight other patients, the tip of the endotracheal tube was less than 2 cm from the carina (fig. 1). In another 20 patients in the control group, the tip of the tube was between 2 and 3 cm from the carina (fig. 1). There were no endobronchial intubations in the study group, and in only two instances was the end of the tube closer than 3 cm from the carina (fig. 1). In both of these latter patients, the end of the tube was greater than 2 cm from the carina (fig. 1). Thus, in the control group, the tip of the endotracheal tube was too close to the carina by our predetermined criteria[‡] in 35 (13%) of the patients, compared to only two (<1%) of those in the study group ($P < .001$).

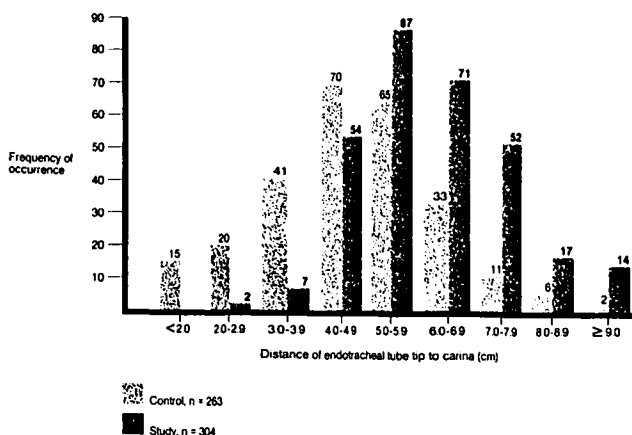


FIG. 1. Distance of the oral endotracheal tube tip from the carina in control and study groups.

The tips of the endotracheal tubes tended to be placed higher in the trachea in the study group. Eighty-three patients in the study group (27%) and 19 patients in the control group (7%) had the end of the endotracheal tube 7 cm or higher from the carina ($P < .001$). In spite of the higher placement in the study group, the endotracheal tube cuff did not impinge on the vocal cords of any patient by radiograph, nor were there any accidental extubations.

DISCUSSION

Positioning an oral endotracheal tube by referencing the marks on the side of the tube would seem to be a better method of preventing endobronchial intubation than auscultation of the chest, which was presumably performed in the control group by the individual intubating the patient. In addition to the seven patients in the control group with endobronchial intubation, eight others, who had the tip of the endotracheal tube closer than 2 cm from the carina, would also be at very high risk for this complication (fig. 1). Conrardy *et al.*¹⁰ reported that neck flexion from a neutral head position can advance the tube up to 3.1 cm toward the carina (mean = 1.9 cm). If patients with the end of their oral endotracheal tubes closer to the carina than 3 cm are considered at high risk for endobronchial intubation, then 35 patients were at risk in the control group, compared to only two patients in the study group (fig. 1).

The risks of assessing proper placement of oral endotracheal tubes by the criterion used in this study seem to be mainly that of leak from the placement of the cuff between the vocal cords or accidental extubation. In no case in the study group was the cuff noted to be at the level of the vocal cords by x-ray, and subsequent migration of the cuff between the cords would be easily recognized by the presence of an air leak with positive pressure ventilation. Although the tip of the endotracheal tube has been reported by Conrardy *et al.*¹⁰ to move up to 5.2 cm away from the carina with neck extension from neutral head position, we did not experience any accidental extubations. Our failure to observe problems with higher tube placements in the study group may be related to the fact that there was a tendency for the patients' heads to be in extension during the performance of the portable chest radiograph in the CCC. Thus, the radiograph may have been taken with the tip of the endotracheal tube in a higher position than it would have been after the film plate had been removed.

The results of this study can be applied in both the operating room and in the intensive care setting. In case of development of sudden hypoxemia in an intubated patient in the operating room or intensive care unit, a rapid assessment of the likelihood of endobronchial in-

tubation as the cause can be made by checking the centimeter markings on the side of the tube. If endotracheal tube placement is the only indication for a chest radiograph, then it would seem an unnecessary expense if the tube has been secured as we describe in the average-sized adult. A portable chest radiograph costs approximately \$82 at present in our institution, so the savings are not trivial.

Finally, the question arises as to the proper method of positioning the endotracheal tube relative to the carina in patients whose body length does not lie within the average adult range. Dornette¹¹ has described an anatomical method for determining placement of the endotracheal tube which can be used for either oral or nasal intubation. The endotracheal tube is placed alongside the patient's face and neck with the tip of the tube lying at the suprasternal notch. The tube is aligned to conform externally to the position of a nasal or oral endotracheal tube. The centimeter markings at which the tube intersects with the teeth or gums (oral intubation) or the nares (nasal intubation) are noted, and the tube secured in that position after intubation. This is the method we utilize in adult patients whose body lengths lie outside the normal range.

In summary, we have shown that securing oral endotracheal tubes at the upper incisor teeth or gums at the 23-cm mark in men and the 21-cm mark in women of average adult size significantly reduces the likelihood of inadvertent endobronchial placement of an endotracheal tube.

Anesthesiology
67:257-262, 1987

Use of Midazolam Infusion for Sedation following Cardiac Surgery

LYNN M. WESTPHAL, B.A.,* EUGENE Y. CHENG, M.D.,† PAUL F. WHITE, PH.D., M.D.,‡
ROBERT N. SLADEN, M.B., M.R.C.P (UK), F.R.C.P.(C),§ MYER H. ROSENTHAL, M.D.,¶ MAN-LING SUNG, M.S.**

A major challenge after cardiac surgery is to provide adequate sedation, analgesia, and hemodynamic stability without prolonging recovery time. Determining the

The authors thank Dr. Robert Caplan for valuable assistance with the statistical analyses.

REFERENCES

1. Zwillich CW, Pierson DJ, Creagh CE, Sutton FD, Schatz E, Petty TL: Complications of assisted ventilation: A prospective study of 354 consecutive episodes. *Am J Med* 57:161-170, 1974
2. Bekemeyer WB, Crapo RO, Calhoun S, Cannon CY, Clayton PD: Efficacy of chest radiography in a respiratory intensive care unit. *Chest* 88:691-696, 1985
3. Henschke CI, Pasternack GS, Schroeder S, Hart KK, Herman PG: Bedside chest radiography: Diagnostic efficacy. *Radiology* 149:23-26, 1983
4. Stauffer JL, Olson DE, Petty TL: Complications and consequences of endotracheal intubation and tracheostomy: A prospective study of 150 critically ill patients. *Am J Med* 70:65-76, 1981
5. Strain DS, Kinasevitz GT, Vereen LE, George RB: Value of routine daily chest x-rays in the medical intensive care unit. *Crit Care Med* 13:534-536, 1985
6. Taryle DA, Chandler JE, Good JT, Potts DE, Sahn SA: Emergency room intubations: Complications and survival. *Chest* 75:541-543, 1979
7. Pollard BJ, Junius F: Accidental intubation of the oesophagus. *Anaesth Intensive Care* 8:183-186, 1980
8. Food and Nutrition Board: Recommended dietary allowances. 8th ed. National Academy of Sciences—National Research Council, Washington D.C., 1974, p 129
9. Dronen S, Chadwick O, Nowak R: Endotracheal tip position in the arrested patient (letter). *Ann Emerg Med* 11:116-117, 1982
10. Conrardy PA, Goodman LR, Lainge F, Singer MM: Alteration of endotracheal tube position. *Crit Care Med* 4:8-12, 1976
11. Dornette WHL: Anatomy for the Anesthesiologist. Springfield, Charles C. Thomas, 1963, pp 73-77

* Medical Student, Research Assistant in Anesthesia.
† Research Fellow, Critical Care Medicine.
‡ Associate Professor of Anesthesia; Chief, Outpatient Anesthesia Service.

§ Associate Professor of Anesthesia (Clinical); Associate Medical Director, Intensive Care Units.

¶ Professor of Anesthesia, Surgery, and Medicine (Clinical); Medical Director, Intensive Care Units.

** Laboratory Research Assistant in Anesthesia.

Received from the Department of Anesthesia, Stanford University School of Medicine, Stanford, California.

optimal dose of sedative or analgesic medication after cardiac surgery is difficult because the presence of an endotracheal tube and residual neuromuscular blockade complicate efforts to communicate with the patient. The physiologic response to pain includes an increase in sympathetic activity (with tachycardia, hypertension, and increased systemic vascular resistance), which can

Address reprint requests to Dr. White: Department of Anesthesia, S-268, Stanford University Medical Center, Stanford, California 94305.

Key words: Anesthetics, intravenous: midazolam. Critical care unit. Pharmacodynamics: midazolam. Pharmacokinetics: midazolam. Sedation: midazolam. Techniques: continuous infusion.