

systemic heparinization, it was very moderate. In our human study, clot formation in the gas exchanger (after nearly 9 days) was equally moderate and found at exactly the same places as in the animal study.

To meet hemodynamic requirements, we believe that gas exchangers should be reconstructed; in the meantime, heparin should be administered iv in quantities that maintain an APT at about 45 s and a WCT at about 15 min. By introducing the new CBAS heparinization technique, it is our hope that extracorporeal carbon dioxide elimination can be applied in a safer manner and, thereby, earlier than is the case today where the method is merely a last-chance therapeutic tool. In this way, it should be possible on a broader basis to establish the effect and the right entry criteria of this method.

#### REFERENCES

1. Kirby RR, Downs JD, Civetta JM, Modell JH, Dannemiller FJ, Klein EF, Hodges M: High level positive end-expiratory pressure (PEEP) in acute respiratory insufficiency. *Chest (Suppl)* 67:156-163, 1975
2. Kolobow T, Spagg RG, Pierce JE: Massive pulmonary infarction

- during total cardiopulmonary bypass in unanesthetized spontaneously breathing lambs. *Int J Artif Organs* 4:76-81, 1981
3. Fein AM, Goldberg SK, Lippman ML, Fischer R, Morgan L: Adult respiratory distress syndrome. *Br J Anaesth* 54:723-736, 1982
4. Kolobow T, Gattinoni L, Solca M, Pesenti A: A new approach to the prevention and the treatment of acute respiratory failure in the adult and the neonate, *Applied Physiology in Clinical Respiratory Care*. Edited by Prakash O. The Hague, Boston, London, Martinus Nijhoff Publishers, 1982, pp 177-190
5. Larm O, Larsson R, Olsson P: A new non-thrombogenic surface prepared by selective covalent binding of heparin via a modified reducing terminal residue. *Biomater Med Devices Artif Organs* 2:161-173, 1983
6. Bindsvlev L, Gouda I, Inacio J, Kodama K, Lagergren H, Larm O, Nilsson E, Olsson P: Extracorporeal elimination of carbon dioxide using a surface-heparinized veno-venous by-pass system. *Trans Am Soc Artif Intern Organs XXXII*, 1986
7. Nunn JF: *Applied Respiratory Physiology*, 2nd edition. London, Boston, Butterworths, 1977, pp 277-281
8. Nunn JF: *Applied Respiratory Physiology*, 2nd edition. London, Boston, Butterworths, 1977, pp 227-228
9. Arnander C, Dryjski M, Larsson R, Olsson P, Swedenborg J: Thrombin uptake and inhibition on endothelium and surfaces with a stable heparin coating. A comparative in vitro study. *J Biomed Mater Res* 20:235-246, 1986

Anesthesiology  
67:120-122, 1987

## Arnold-Chiari Malformation Type I Appearing after Tonsillectomy

MAI-LI DONG, M.D.\*

Acquired torticollis is often considered to be a benign transient muscle spasm. Persistent acquired torticollis, however, indicates an underlying disorder, such as a skeletal-muscular abnormality or a neurologic lesion. Hyperextension of the neck under anesthesia, especially during paralysis, in a patient with undiagnosed congenital cervical anomaly may be of potential harm. The following case illustrates the appearance of persistent torticollis after an elective tonsillectomy due to primary cerebellar tonsil herniation without cervical displacement of the medulla (Arnold-Chiari malformation type I).

#### REPORT OF A CASE

An otherwise healthy, 8-year-old, 47-kg boy was admitted for persistent, painful right-sided torticollis. The torticollis developed during the first 24 h after a routine elective tonsillectomy at an outlying hospital 8 weeks before admission. The history was otherwise unremarkable except for a family medical history of multiple sclerosis. The physical examination was significant for obesity, painful right-sided torticollis, and no apparent gross neurologic defects. Otolaryngology consultation ruled out inflammation in the peritonsillar area. Initial reading of the radiograph and computed tomogram (CT) of the cervical spine showed no subluxation or osteitis. The patient was brought to the operating room for cervical traction by halo vest under general anesthesia to alleviate the torticollis. Anesthesia was uneventfully induced with thiopental, atracurium, and fentanyl iv, and maintained by inhalation of nitrous oxide and isoflurane; the trachea was intubated without cervical extension. The patient was discharged home the next day.

The neurosurgical consultant readmitted the patient a week later for further study. The neurologic examination revealed mild clonus, right-greater-than-left, bilateral hyperactive deep tendon reflexes in the lower extremities, and slight loss of fine movements in the right fingers. The halo vest was removed with resolution of the torticollis. Review of the CT scan revealed an Arnold-Chiari malformation (ACM) type I. Magnetic resonance studies delineated downward her-

\* Assistant Professor of Anesthesiology.

Received from the Department of Anesthesiology, University of Pittsburgh School of Medicine, Children's Hospital of Pittsburgh, Pittsburgh, Pennsylvania. Accepted for publication January 28, 1987.

Address reprint requests to Dr. Dong: Department of Anesthesiology, Children's Hospital of Pittsburgh, One Children's Place, 3705 Fifth Avenue at DeSoto Street, Pittsburgh, Pennsylvania 15213.

Key words: Anesthesia; pediatric. Complications: acquired torticollis; Arnold-Chiari malformation type I.

niation of both cerebellar tonsils, right-greater-than-left to the level of the second cervical vertebra (C<sub>2</sub>) with a very tight atlanto (C<sub>1</sub>)-occipital junction. Hydromyelia was present at C<sub>2</sub>-C<sub>5</sub> (figs. 1, 2). Subsequently, the patient underwent suboccipital decompression, posterior laminectomy at C<sub>1</sub>-C<sub>2</sub>, duraplasty, and ventricular subarachnoid drainage under nitrous oxide-narcotic anesthesia with intraoperative somatosensory evoked potential monitoring at the median nerves. Intraoperatively, restrictive arachnoid fibrosis was found around the foramen magnum and along the cervical portion over the cerebellar tonsils. The right-sided nerve roots at C<sub>1</sub>-C<sub>2</sub> were compressed by the herniated cerebellum. He recovered uneventfully and was discharged 1 week later with only a residual discrete right-ankle clonus.

## DISCUSSION

Acquired torticollis is considered a sign of an underlying disorder. Disorders that can cause torticollis include skeletal abnormalities, muscular and soft tissue disorders, neurologic lesions, and functional disorders.<sup>1-4</sup> In the initial differential diagnosis of this patient, musculoskeletal abnormalities, such as retropharyngeal infection<sup>4-6</sup> and spontaneous rotary subluxation at C<sub>1</sub>-C<sub>2</sub>, were considered.<sup>4,7</sup> Painful torticollis from retropharyngeal or mandibular abscess is not uncommon, and usually resolves after incision and drainage. Oropharyngeal infections can produce contiguous edema of ligaments and erosive osteitis which facilitate spontaneous subluxation. The incomplete development of the vertebrae and ligaments in the neonate and infant also makes the atlanto-occipital junction potentially unstable and prone to rotary subluxation.<sup>7</sup> This case of persistent torticollis in an older child after a routine tonsillectomy is unusual. After musculoskeletal abnormalities had been ruled out by examination, laboratory results, and roentgenographic studies, the torticollis was treated symptomatically with traction. Further evaluation by neurosurgeons altered the diagnosis to Arnold-Chiari malformation (ACM) type I.

Primary cerebellar tonsil herniation is considered the adult manifestation of congenital ACM. The most common ACM in pediatric patients is type II, distinguished by cervical displacement not only of the cerebellum, but also of the medulla, and association with meningocele or spina bifida. Of 154 patients with ACM type I reported in five series, only 20 were younger than 20 yr old, and none were younger than 10 yr old. The incidence in the pediatric population of symptomatic ACM type I not associated with other anomalies, as described in the present case, may be less. Some of the series cited described associated cervical spine malformation and symptomatic spina bifida, most probably occurring in the younger patients.

Torticollis as the initial presentation of ACM type I is not common. The major presenting symptoms are similar to those of syringomyelia, which frequently accompanies ACM type I.<sup>9</sup> In most series, the chief complaint

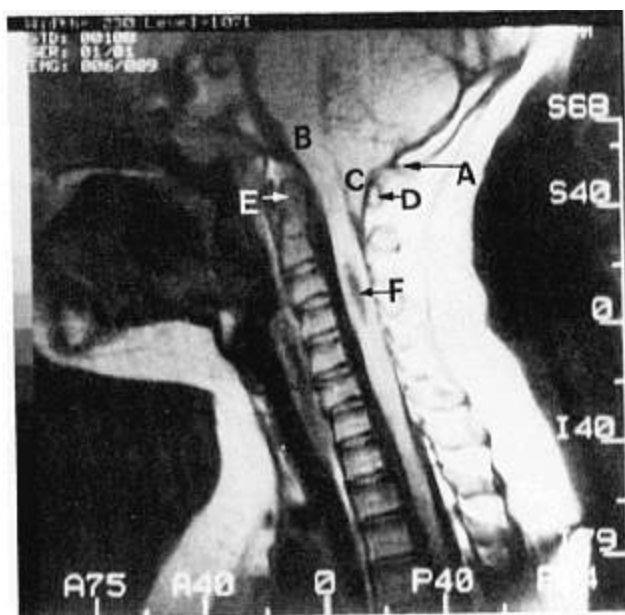


FIG. 1. Magnetic resonance image of the mid-sagittal brain and spinal cord in this child with Arnold-Chiari malformation type I. A = foramen magnum; B = medulla; C = cerebellar herniation; D = atlas-posterior arch; E = odontoid process; F = hydromyelia within cervical spinal cord.

is pain, usually burning along the neck and upper extremities, and suboccipital headaches. The other usual findings are limb weakness, spasticity, cranial nerve

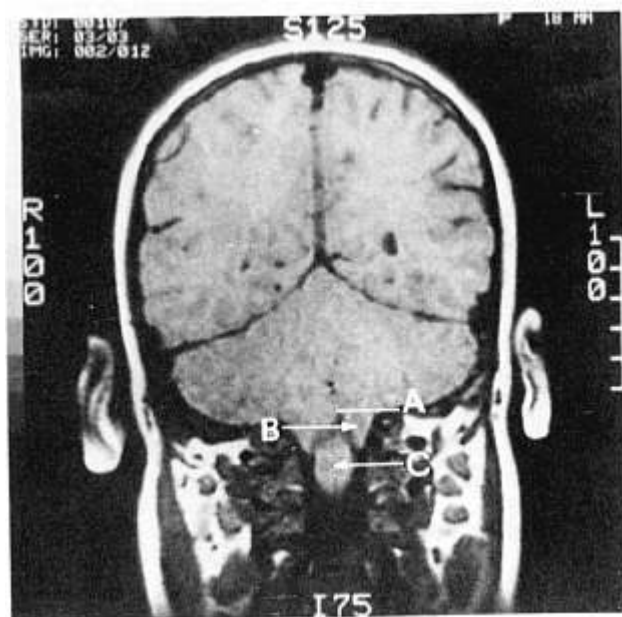


FIG. 2. Magnetic resonance image of the mastoid coronal section in this child with Arnold-Chiari malformation type I. A = foramen magnum level; B = cerebellar herniation; C = spinal cord.

dysfunction, and hydrocephalus. One series of 60 patients<sup>11</sup> cites only two patients with torticollis among 19 categories of preoperative neurologic findings. Congenital cerebellar herniation can be viewed as a type of extrinsic cervical cord "tumor." Seven pediatric patients with intrinsic cervical cord tumor discussed by Visudhiphan *et al.*<sup>4</sup> and Kiwak *et al.*<sup>2</sup> presented with torticollis.

The mechanism that promotes torticollis is unknown. Perhaps the spinal nerve that exits along C<sub>1</sub>-C<sub>2</sub>-C<sub>3</sub> nerve roots is irritated by compression, causing an imbalance of muscle tone to the sternocleidomastoid and trapezius muscles. In this patient, the hyperextended position of the atlanto-occipital junction during tonsillectomy probably accentuated the irritative compression and precipitated symptoms. Theoretically, a previously asymptomatic patient with ACM type I might suddenly manifest symptoms after whiplash injury.

In conclusion, acquired persistent torticollis is not necessarily a benign condition of muscle spasm. As this case illustrates, a thorough evaluation is indicated to uncover and treat the underlying disorder. Unrelated elective surgery probably should be postponed in a patient with persistent acquired torticollis pending a thorough neurologic examination. Sustained hyperextension of the neck under anesthesia, especially when muscle relaxants are used, may be hazardous to any patient who may be harboring a yet undiagnosed cervical instability or congenital anomaly.

Anesthesiology  
67:122-125, 1987

## REFERENCES

1. Clark RN: Diagnosis and management of torticollis. *Pediatr Ann* 5:231-239, 1976
2. Kiwak KJ, Deray MJ, Shields WD: Torticollis in three children with syringomyelia and spinal cord tumor. *Neurology* 33:946-948, 1983
3. McDaniel A, Hirsch BE, Kornblut AD, Armbrustmacher VM: Torticollis in infancy and adolescence. *Ear Nose Throat J* 63:478-487, 1984
4. Visudhiphan P, Chiemchanya S, Somburanasin R, Dheandhanoo D: Torticollis as the presenting sign in cervical spine infection and tumor. *Clin Pediatr (Phila)* 21(2):71-76, 1982
5. Ballenger JJ: Diseases of the Nose, Throat, Ear, Head and Neck, 13th edition. Philadelphia, Lea and Febiger, 1985, p 267
6. Mercer RD: Atlas-axis dislocation following cervical adenitis. *Cleve Clin Q* 11:161-165, 1952
7. Gilles FH, Bina M, Sotrel A: Infantile atlanto-occipital instability. The potential danger of extreme extension. *Am J Dis Child* 133:30-37, 1979
8. Appleby A, Foster JB, Hankinson J, Hudgson P: The diagnosis and management of the Chiari anomalies in adult life. *Brain* 91:131-140, 1968
9. Banerji NK, Millar JHD: Chiari malformation presenting in adult life. *Brain* 97:157-168, 1974
10. Gardner WJ, Goodall RJ: The surgical treatment of Arnold-Chiari malformation in adults. *J Neurosurg* 7:199-206, 1950
11. Saez RJ, Onofrio M, Yanagihara T: Experience with Arnold-Chiari malformation, 1960 to 1970. *J Neurosurg* 45:416-422, 1976
12. Mohr PD, Strang FA, Sambrook MA, Boddie HG: The clinical and surgical features in 40 patients with primary cerebellar ectopia (adult Chiari malformation). *Q J Med* 181:85-96, 1977

## Histamine Release by Vancomycin: A Mechanism for Hypotension in Man

JERROLD H. LEVY, M.D.,\* NANCY KETTLEKAMP, B.A.,† PETER GOERTZ, M.D.,‡ JEANNE HERMENS, M.D.,‡  
CAROL A. HIRSHMAN, M.D.§

Vancomycin, a glycopeptide antibiotic, produces hypotension and flushing during rapid administration in individuals without previous exposure.<sup>1,2</sup> Primary myocardial depression has been suggested as the mechanism

responsible for the hypotension.<sup>3,4</sup> However, in this report, we found elevated plasma histamine levels in two patients who became hypotensive following vancomycin administration, and histamine release by vancomycin in dispersed human cutaneous mast cells. We now believe that nonimmunologic histamine release by vancomycin, not the vancomycin *per se*, is the mechanism responsible

\* Assistant Professor of Anesthesiology, Emory University School of Medicine.

† Research Assistant, Oregon Health Sciences University School of Medicine.

‡ Resident in Anesthesiology, Oregon Health Sciences University School of Medicine.

§ Professor of Anesthesiology and Pharmacology, Oregon Health Sciences University School of Medicine.

Received from the Division of Cardiothoracic Anesthesia, Emory Clinic, Department of Anesthesiology, Emory University School of

Medicine; and the Department of Anesthesiology, Oregon Health Sciences University School of Medicine. Accepted for publication January 30, 1987.

Address reprint requests to Dr. Levy: Department of Anesthesiology, Emory University Hospital, 1364 Clifton Road NE, Atlanta, Georgia 30322.

Key words: Complications: hypotension. Histamine. Pharmacology: vancomycin.