

to about 130% of the level present in erythrocytes of non-pregnant women.² In this study, the actual and the standardized P 50 were increased to about 2.5–3.0 mmHg. Moreover, hormonal changes during pregnancy could affect the red cell metabolism, *e.g.*, the 2,3 DPG level has been shown to be sensitive to changes in the concentration of thyroxin and prostaglandin.^{2,3}

Furthermore, the authors did not discuss the leftward shift of the oxyhemoglobin dissociation curve in preeclamptic parturients. One explanation for the leftward shift could be hypophosphatemia which increases oxygen affinity of hemoglobin.⁴ This electrolyte imbalance could be induced by excessive loss of phosphate, which occurs when hypokalemia is provoked by diuretic therapy in these patients. In any case, this remarkable observation should be commented upon.

WOLFGANG HESS
Assistant Professor of Anesthesiology

Anesthesiology
66:855, 1987

In Reply:—The effect of normal pregnancy on oxyhemoglobin dissociation (OHD) has been reported by several investigators. A leftward shift of OHD seen in preeclamptic pregnant women is new and surprising. Both normal and preeclamptic pregnancies are associated with complex changes in a variety of hormones, including prostaglandins. Several of these hormones are also known to cause shifts in OHD. We have discussed the possible causes for a leftward shift of OHD in a recent abstract describing the effect of pregnancy induced hypertension on OHD.¹ Evidence also suggests that there is increased red cell destruction in patients with toxemia of pregnancy.² In addition, we have recently reported that preeclamptic patients have significantly higher levels of carboxyhemoglobin compared with normal pregnant women.³ We believe that the increased level of carboxyhemoglobin is principally responsible for the observed leftward shift in OHD. Our preeclamptic patients did not receive any diuretic therapy and, thus, hypophosphatemia from diuretic therapy is unlikely. Also, none of our patients at the time

Anesthesiology
66:855–856, 1987

*Department of Anesthesiology
University of Essen
Hufelandstr. 55
4300 Essen 1 Federal Republic of Germany*

REFERENCES

1. Kambam JR, Handte RE, Brown WU, Smith BE: Effect of normal and preeclamptic pregnancies on the oxyhemoglobin dissociation curve. *ANESTHESIOLOGY* 65:426–427, 1986
2. Rorth M, Brake NE: 2,3 DPG in human pregnancy, Oxygen affinity of Hemoglobin and Red Cell Acid Base Status. Edited by Rorth M, Astrup P. New York, Academic Press, 1971, pp 692–695.
3. Synder LM, Reddy WJ: Mechanism of action of thyroid hormones on erythrocyte 2,3-diphosphoglyceric acid synthesis. *J Clin Invest* 49:1993–1998, 1970
4. Sladen RN: The oxyhemoglobin dissociation curve, Clinical Aspects of Oxygen. Edited by Brodsky JB. Boston, Little Brown and Company 1981, pp 39–70

(Accepted for publication February 24, 1987.)

of the study was receiving any other drug that could possibly cause a shift in OHD.

J. REDDY KAMBAM, M.D.
*Assistant Professor of Anesthesiology
Department of Anesthesiology
Vanderbilt University
Nashville, Tennessee 37232*

REFERENCES

1. Kambam JR, Handte RE, Brown WU, Smith BE: Effect of pregnancy induced hypertension on oxyhemoglobin dissociation. *ANESTHESIOLOGY* 59:A396, 1983
2. Entman S, Richardson LD, Killam AP: Altered ferrokinetics in toxemia of pregnancy. A possible indicator of decreased red cell survival. *Clin Exp Hypertens B2*: 171–178, 1983
3. Kambam JR, Entman S, Mouton S, Linn J, Smith BE: Effect of preeclampsia (PIH) on carboxyhemoglobin levels: A mechanism for shift of P50 to the left (Abstract) *ANESTHESIOLOGY* 65: A393, 1986

(Accepted for publication February 24, 1987.)

pH-adjusted Lidocaine Does Not “Sting”

To the Editor:—The widespread practice at our institution of adding sodium bicarbonate to lidocaine solutions (ratio 1:10) to improve the success rate of regional anesthesia¹ has led to the observation that these pH-adjusted

solutions do not “sting” when injected intradermally or subcutaneously. The improvement in comfort when providing cutaneous anesthesia is striking. Starting an iv in a child, for example, is greatly facilitated when pH-ad-

justed lidocaine is slowly injected intradermally via a 27-gauge needle using the technique of gently scratching the skin to minimize the discomfort of needle placement.² The actual injection of pH-adjusted lidocaine is painless.

GREGG A. KORBON, M.D.
Assistant Professor of Anesthesiology

DAVID P. HURLEY, M.D.
Chief Resident
Department of Plastic Surgery

GAYLORD S. WILLIAMS, M.D.
Professor of Plastic Surgery

Anesthesiology
66:856-857, 1987

University of Virginia
Charlottesville, Virginia 22908

REFERENCES

1. DiFazio CA, Carron H, Grosslight KR, Moscicki JC, Bolding WR, Johns RA: Comparison of pH-adjusted lidocaine solutions for epidural anesthesia. *Anesth Analg* 65:760-764, 1986

2. Bourke DL: Counter-irritation reduces pain during needle insertion (letter). *Anesth Analg* 64:377-382, 1985

(Accepted for publication March 3, 1987.)

A Tracheal Divider for Differential Lung Ventilation in Dogs

To the Editor:—Many investigators are aware of technical difficulties inherent in the differential lung ventilation in dogs.¹⁻²

In a previous report,³ we used a right-sided Robertshaw tube which was passed into, and seated in, the left main bronchus for differential lung ventilation. However, at autopsy, only 55% (22 cases among a total of 40) of the tubes were confirmed to be in the proper location. In the remaining cases, there was partial obstruction of the left upper lobe bronchus.

TABLE 1. Distance from the Carina to Proximal Edge of Each Lobe Orifice (Mean ± SD) (fig. 1, a-d) in mm

	Mean ± SD (mm) (n = 18)
a	-4.4 ± 3.3
b	12.4 ± 7.0
c	24.4 ± 6.5
d	17.9 ± 1.9

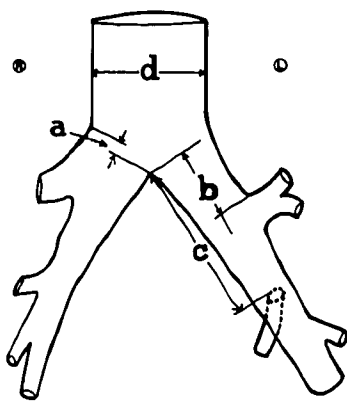


FIG. 1. Diagram of trachea and major bronchial divisions in dogs, showing the measured positions and distances from the carina to the origin of the right upper lobe orifice (a), to the left upper lobe orifice (b), to the left middle lobe (lingula) orifice (c), and the diameter of the trachea (d).

To develop a tube which would more reliably separate the lungs in studies requiring differential ventilation, measurements of the tracheo-bronchial tree near the carina were performed in 18 dogs. Mean distances (±SD) in mm from the carina to right upper lobe orifice (a), to left upper lobe orifice (b), and to left middle lobe orifice (c) are shown in table 1 and figure 1. A striking anatomical feature of the canine tracheal bifurcation is that the mean

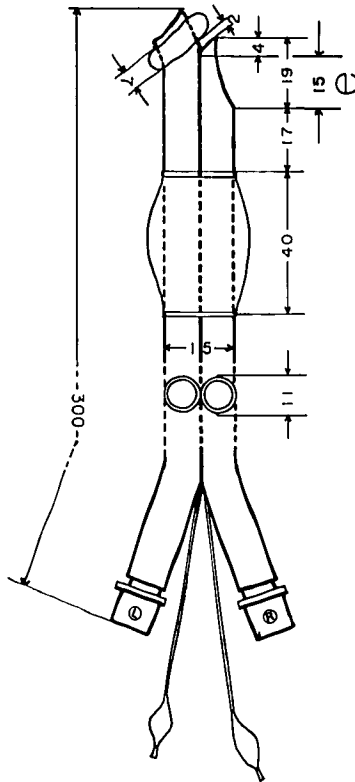


FIG. 2. A scale drawing of the tube (MKP-divider). The tube is made of polyvinyl chloride (PVC) of medical grade, and is soft and pliable, yet has sufficient stiffness to allow manipulation and control during placement. To prevent the tube from being displaced laterally and passing too far into the tracheobronchial tree, a carinal crotch, which is formed by the distal end of the right side of the tube and the projection to the left, is indispensable. The larger balloon separates the right lung from the outside, while the left main-stem bronchial balloon separates the left lung from the right. The length of the right lung ventilation slot (e) is 15 mm (table 1, mean value of a plus 3 x SD), to prevent partial obstruction of the right upper lobe orifice.