

of this complication is understandable. The value of EEMG is unquestionable. Evoked electromyography is of prognostic value, and is advisable even in a case where trauma is the only plausible explanation.

LAWRENCE SPEILBERGER, M.D.
*Department of Anesthesiology
New York University Medical Center
550 First Avenue
New York, New York 10016*

REFERENCES

1. Glauber DT: Facial paralysis after general anesthesia. *ANESTHESIOLOGY* 65:516-517, 1986

Anesthesiology
66:711, 1987

In Reply:—Dr. Spielberger misinterprets me when he implies that I recommend discarding the practice of providing anesthesia *via* a mask and indiscriminately encouraging the “exercising of prowess” at non-indicated tracheal intubation.

The point is that, if it becomes necessary to exercise sustained and strong forward pressure behind the mandible in order to maintain a clear airway, then there is a small but significant risk of encountering this complica-

Anesthesiology
66:711-712, 1987

Monitoring Bilateral Breath Sounds

To the Editor:—Every anesthesiologist is aware of the importance of bilateral breath sounds (BBS) as a diagnostic tool of intraoperative complications, such as endobronchial intubation, obstructed airway, and pneumothorax.¹⁻⁴ Continuous auscultation using a weighted chest stethoscope bell or esophageal stethoscope has become the standard technique for monitoring breath sounds and heart tones.¹⁻⁶ However, intermittent auscultation using a stethoscope is still required to determine the presence of BBS. Unfortunately, limited access to the chest during surgical procedures (*e.g.*, thoracic or head and neck cases) does not allow for easy detection of BBS. Furthermore, head movement may displace an endotracheal tube, leading to inadvertent endobronchial intubation, a complication not recognizable by continuous esophageal auscultation. The small preterm infant is at a considerable risk of intraoperative endobronchial intubation due to their particular anatomical characteristics. Their tracheal length has been measured at only 3 cm,⁷⁻¹⁰ while lateral head tilt may displace the endotracheal tube tip 1.2 cm. To deal with this challenging and common problem, we

2. Spielberger L, Mazzia VDB: Anesthesia and Bell's Palsy: Current research. *Anesth Analg* 56(1):77-82, 1971
3. May MD: The facial nerve (correspondence). *Am J Otol* 6:524-525, 1985
4. *Textbook of Otolaryngology*, 6th edition. Edited by DeWeese DD, Saunders WH. St. Louis, CV Mosby Company, 1982, pp 416-419
5. *Williams Obstetrics*, 17th edition. Edited by Pritchard PC, McDonald PC, Gant M. Norwalk, Appleton-Century-Crofts, 1985, p 610
6. Adour K, Hiesinger RL Jr, Callan EJ: Facial paralysis and Bell's Palsy: A protocol for differential diagnosis. *Am J Otol (Suppl)*: 68-73, 1985
7. Silverstein H, McDaniel AB, Hyman SM: Evoked serial electromyography in the evaluations of the paralyzed face. *Am J Otol (Suppl)*:80-87, 1985

(Accepted for publication January 15, 1987.)

tion. In these circumstances, early endotracheal intubation is recommended.

DENNIS T. GLAUBER, M.D.
*Department of Anesthesiology, RN-10
University Hospital
University of Washington School of Medicine
Seattle, Washington 98195*

(Accepted for publication January 15, 1987.)

have developed a simple, inexpensive method to monitor BBS using readily available OR supplies.

The method employs 2 iv extension tubes which are

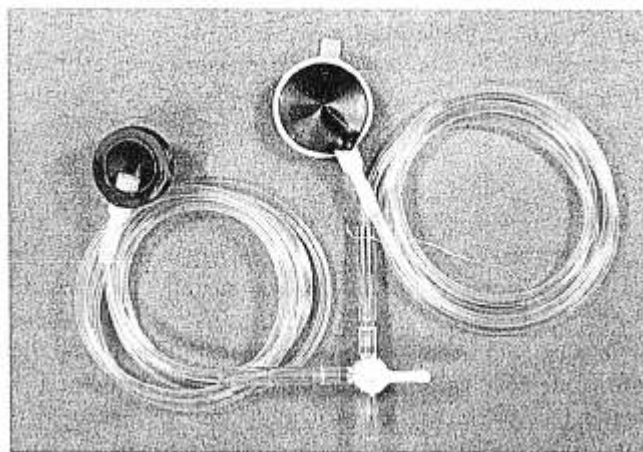


FIG. 1. The photograph details two disposable chest pieces connected *via* extension tube to a three-way stopcock.