

## REFERENCES

1. Finkelstein F, Kreeft J: Massive lidocaine poisoning. *New Eng J Med* 301:50, 1979
2. Nobel J, Kennedy DJ, Latimer RD, Hardy I, Bethune DW, Collis JM, Wallwork J: Massive lignocaine overdose during cardiopulmonary bypass. *Br J Anaes* 56:1439-1441, 1984
3. Antonelli D, Ben-Ami M, Weiss Z: Sinus standstill following accidental lidocaine overdose. *Am Heart J* 107:1042-1044, 1984
4. Bryant CA, Hoffmann JR, Nichter LS: Pitfalls and perils of IV lidocaine. *West J Med* 139:528-530, 1983

5. Pearl WR: Massive lidocaine overdose. *Am Heart J* 103:1083, 1982
6. Badui E, Garcia-Rubi D, Estanol B: Inadvertent massive lidocaine overdose causing temporary complete heart block in myocardial infarction. *Am Heart J* 102:801-803, 1981
7. Burlington B, Freed C: Massive overdose and death from propylactic lidocaine. *JAMA* 243:1036-1037, 1980
8. Brown DL, Skiendzielewski JJ: Lidocaine toxicity. *Ann Emerg Med* 9:627-629, 1980

(Accepted for publication July 31, 1986.)

Anesthesiology  
65:565, 1986

## Pulse Oximetry during Shoulder Arthroscopy

*To the Editor:*—Arthroscopy has become increasingly popular as a means of diagnosing joint disease including arthroscopy of the shoulder. A 25-yr-old male medical student was to undergo left shoulder arthroscopy for recurrent dislocation under general anesthesia. He was positioned as in figure 1. A satisfactory check for capillary filling and pulse was made and skin cleansing was started. After 10 min, the fingers were blue and pulseless. The

weights were removed, and a pulse oximeter was attached to the index finger. After return of adequate perfusion, weights were reapplied and manipulated until the pulse remained steady.

An 18-yr-old male was scheduled for right shoulder arthroscopy. The trachea was intubated, and the patient was positioned as in figure 1; a pulse oximeter was applied to one of the fingers and was used as a guide to adjust rope tension. Early warning of the need to reposition the arm intraoperatively was given by loss of the pulse form. Repositioning was accomplished quickly, and sterility was not compromised.

We believe pulse oximetry monitoring during shoulder arthroscopy provides a simple, inexpensive, and convenient early-warning system of excessive traction and brachial artery compression.

ZVI J. HERSCHMAN, M.D.  
*Resident*

ELIZABETH A. M. FROST, M.D.  
*Professor*

PAUL L. GOLDINER, M.D.  
*Professor and Chairman*

*Department of Anesthesiology  
Albert Einstein College of Medicine  
1300 Morris Park Avenue  
Bronx, New York 10461*

(Accepted for publication July 31, 1986.)

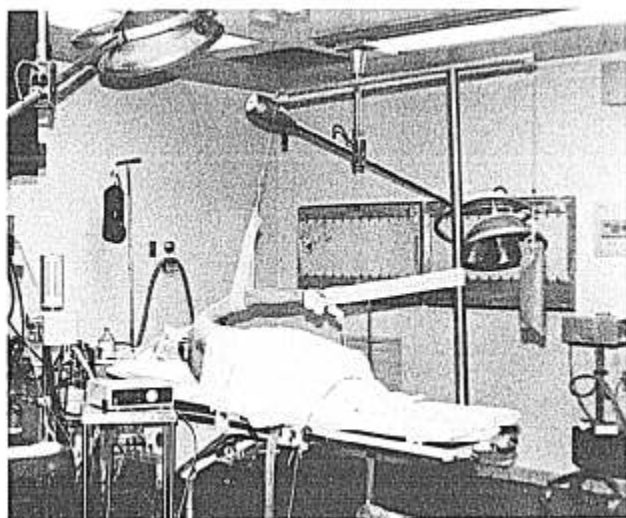


FIG. 1. One frequently used set-up for shoulder arthroscopy with pulse oximeter attached.

Anesthesiology  
65:565-566, 1986

## A Simpler Design for Mass Spectrometer Monitoring of the Awake Patient

*To the Editor:*—We share with Drs. Norman and Ibarra and their colleagues<sup>1,2</sup> their interest in monitoring of the awake patient with a mass spectrometer.

Our technique for this purpose is as satisfactory, but simpler. We use an ordinary plastic iv catheter (gauge 14, 1 ¼ in), inserting the iv catheter through one of the side

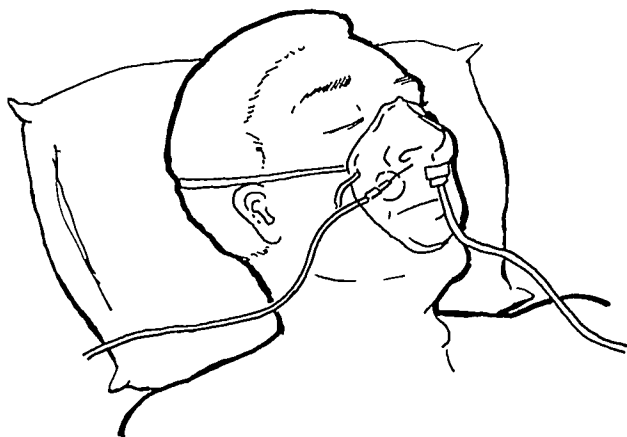


FIG. 1. Position of sampling catheter within green O<sub>2</sub> mask.

ports of a green disposable oxygen mask to a point close to, but not irritating, the patient's nose. We then secure the catheter to the mask with adhesive tape and connect it to the mass spectrometer sampling tube (fig. 1).

In addition to obtaining satisfactory end-tidal CO<sub>2</sub> es-

timations in both awake and sedated patients, this technique provides the following advantages: 1) it uses readily available equipment without modification, thus saving time and the reusable sampling tube; 2) the sampling catheter is outside the patient's airway, so it will not be obstructed with secretions, nor will it irritate the patient; and 3) it enables the patient to receive a high oxygen mixture and does not require bilateral patency of the nostrils.

CHARLOTTE T. HUNTINGTON, M.D.  
HWA-KOU KING, M.D.  
Department of Anesthesiology  
King/Drew Medical Center  
12021 South Wilmington Avenue  
Los Angeles, California 90059

#### REFERENCES

1. Norman EA, Zeig NJ, Ahmad I: Better designs for mass spectrometer monitoring of awake patient. *ANESTHESIOLOGY* 64: 664, 1986
2. Ibarra E, Less DE: Mass spectrometer monitoring of patients with regional anesthesia. *ANESTHESIOLOGY* 63:572-573, 1985

(Accepted for publication August 8, 1986.)

Anesthesiology  
65:566, 1986

### A Modification of Laryngoscopy Technique

*To the Editor:*—Gandhi and Burgos<sup>1</sup> suggest inserting a detached laryngoscope blade into the mouth when intubating massively obese patients or patients with a barrel-shaped chest or rigid neck, because if attached, the laryngoscope handle may impinge upon the patient's chest. After the blade is in the mouth, the handle is then attached.

We have tried this technique and there are occasions when the laryngoscope handle still impinges upon the

chest during attempts to reattach the handle to the blade. We therefore have modified our intubation technique in these patients by turning and lowering the laryngoscope handle toward the right side of the patient's neck and inserting the blade laterally into the mouth (fig. 1) (a tongue blade is usually helpful), then raising and turning the handle forward.

This modification not only saves the time and trouble of detaching and reattaching the laryngoscope blade to the handle, but it also avoids the possibility of having one's finger caught in the hinge.

HWA-KOU KING, M.D.  
LONG-FONG WANG, M.D.  
AHSANUL K. KHAN, M.D.  
Department of Anesthesiology  
King/Drew Medical Center  
12021 South Wilmington Avenue  
Los Angeles, California 90059

#### REFERENCE

1. Gandhi, SK, Burgos, L: A technique of laryngoscopy for difficult intubation. *ANESTHESIOLOGY* 64:528-529, 1986

(Accepted for publication August 8, 1986.)

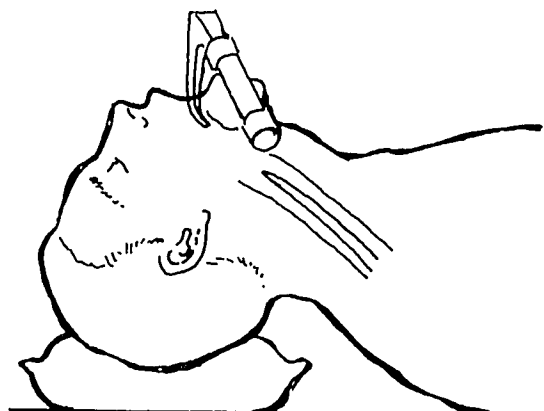


FIG. 1. Modified laryngoscopy technique with blade inserting laterally.