

6. Riehle RA, Fair WR, Vaughan ED: Extracorporeal shock-wave lithotripsy for upper urinary tract calculi. *JAMA* 15:2043-2048, 1986
7. Josephson ME, Seides SF: Clinical cardiac electrophysiology. Philadelphia, Lea and Febiger, 1979, pp 23-59, 147-245
8. Atlee JL: Perioperative cardiac dysrhythmias. Chicago, Year Book Medical Publishers, 1985, pp 221-271
9. Zipes DP: Specific arrhythmias: Diagnosis and treatment, Heart Disease, 2nd edition. Edited by Braunwald E. Philadelphia, WB Saunders, 1984, pp 683-743

Anesthesiology  
65:523-525, 1986

## Bronchoscopic Administration of Nebulized Racemic Epinephrine to Facilitate Removal of Aspirated Peanut Fragments in Pediatric Patients

LOIS L. BREADY, M.D.\* MALCOLM D. ORR, M.D., PH.D.,† CATHY PETTY, M.D.,‡  
FREDERICK L. GROVER, M.D.,§ KENT HARMAN, M.D.¶

Aspiration of foreign bodies, such as peanuts or other foods, causes significant morbidity and mortality in children.<sup>1-8</sup> When these organic foreign bodies have been in the airway for a prolonged period of time, mucosal edema develops that traps the fragments, and bronchoscopic extraction may be difficult or impossible. Diluted racemic epinephrine is frequently nebulized to reduce laryngotracheal edema associated with laryngotracheobronchitis (LTB)<sup>9,10</sup> and after tracheal extubation.<sup>11,12</sup> We used an extremely dilute solution of nebulized racemic epinephrine, administered directly through the bronchoscope, to reduce mucosal swelling and thus facilitate extraction of firmly impacted peanut fragments from three small children.

### REPORT OF THREE CASES

*Case 1.* A 2½-yr-old boy was admitted with a history suggestive of peanut aspiration. Rigid bronchoscopy under general anesthesia was performed and repeated the next day. Although the peanut fragment was visualized in the right lower lobe (RLL) bronchus, it could not be extracted because of severe swelling of bronchial mucosa. The child developed RLL pneumonia, and fluids and clindamycin administration iv did not result in clinical improvement. He was scheduled for a third rigid bronchoscopy under general anesthesia to be followed by right lower lobectomy if the peanut could not be removed.

The child was anesthetized with enflurane in N<sub>2</sub>O/O<sub>2</sub>. Direct laryngoscopy was performed, a 5.0-mm rigid bronchoscope introduced,

and ventilation controlled. Anesthesia was maintained with enflurane in oxygen given through the sidearm of the bronchoscope. Examination of the tracheobronchial tree was normal except for the RLL bronchus, where marked erythema and swelling were noted. An impacted peanut fragment was visualized in the RLL bronchus, but the mucosal edema was so extensive that extraction was impossible despite multiple attempts by several individuals. A solution of racemic epinephrine (0.1 ml of 2.25% in 5 ml of saline) was nebulized through the bronchoscope and given directly into the RLL bronchus (fig. 1). Arterial blood pressure and heart rate remained unchanged, and no dysrhythmias were noted. Rapid resolution of the edema occurred, and the peanut fragment was then readily extracted. Enflurane was discontinued, and ventilation was controlled through the sidearm of the bronchoscope until spontaneous ventilation was sufficient to permit tracheal extubation. The child had an uneventful recovery.

*Case 2.* A 2-yr-old girl presented with a 10-week history of productive cough after possible aspiration of a peanut. Physical examination and chest roentgenogram showed left lower lobe (LLL) and lingular bronchopneumonia. She was treated with antibiotics and scheduled for bronchoscopy.

Anesthesia was induced with halothane in N<sub>2</sub>O/O<sub>2</sub>. After surgical anesthesia was achieved, isoflurane was substituted for halothane and N<sub>2</sub>O discontinued. Bronchoscopy was performed with a rigid 4.0-mm bronchoscope and continued for 90 min. Ventilation was controlled through the sidearm of the bronchoscope. The left main bronchus was totally occluded with a purulent exudate. Racemic epinephrine (0.1 ml of a 2.5% solution in 5 ml of normal saline) was nebulized through the bronchoscope directly at the occluded left main bronchus (fig. 1). A total of three doses of nebulized racemic epinephrine were administered during the 60-min bronchoscopy. The exudate became liquefied, the diameter of the bronchus increased, erythema was reduced, and a peanut fragment was extracted. Arterial blood pressure and heart rate remained unchanged, and no dysrhythmias were noted. Isoflurane was discontinued and the trachea was extubated. The patient had an uneventful recovery and was discharged home within 24 h of bronchoscopy.

*Case 3:* A 16-month-old girl was scheduled for bronchoscopy under general anesthesia 2 weeks after a suspected peanut aspiration. She was febrile despite treatment with erythromycin and had a physical examination and chest roentgenogram suggestive of right middle lobe (RML) foreign body.

Anesthesia was induced with halothane in N<sub>2</sub>O/O<sub>2</sub>, isoflurane was subsequently substituted for halothane, and N<sub>2</sub>O was discontinued. Rigid bronchoscopy was performed, revealing purulent exudate and erythema of the RML bronchus. Racemic epinephrine (0.1 ml of 2.25% solution in 5 ml normal saline) was nebulized into the bronchus through

\* Associate Professor, Anesthesiology.

† Professor, Anesthesiology.

‡ Clinical Assistant Professor, Anesthesiology.

§ Professor, Surgery.

¶ Assistant Professor, Surgery.

Received from the Department of Anesthesiology and the Department of Surgery, Division of Cardiothoracic Surgery, The University of Texas Health Science Center at San Antonio, 7703 Floyd Curl Drive, San Antonio, Texas 78284-7838. Accepted for publication June 10, 1986.

Address reprint requests to Dr. Bready.

Key words: Airway; aspiration, peanut. Pharmacology: racemic epinephrine. Surgery: bronchoscopy.

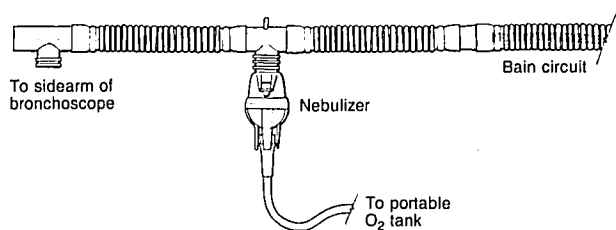


FIG. 1. The apparatus used to nebulize racemic epinephrine.

the bronchoscope (fig. 1). A total of three doses of nebulized racemic epinephrine was administered during the 115-min bronchoscopy. Arterial blood pressure and heart rate remained unchanged, and no dysrhythmias were noted. Numerous peanut fragments were extracted, followed by dramatic improvement in the child's condition.

### DISCUSSION

Because of its size, shape, and smooth surface, an aspirated peanut readily obstructs the small child's mainstem bronchus. Smaller fragments may obstruct more distally in the tracheobronchial tree. Chemical inflammation caused by the peanut oil, proteins, and fatty acids<sup>13</sup> leads to mucosal irritation and the formation of significant mucosal edema that traps the peanut fragments. The edema may be more severe with peanut aspiration than with other aspirated foreign bodies. In addition, fragments absorb water and swell. The result may be a softened, friable particle firmly trapped within an inflamed, edematous segmental bronchus, which is quite difficult to remove. In many cases, bronchoscopy<sup>14</sup> or conservative therapy (bronchodilators, postural drainage, and chest percussion<sup>3,4</sup>) are successful for removal of the fragments. Use of the Fogarty catheter has facilitated removal of recently aspirated peanuts and other foreign bodies.<sup>15,16</sup> In a few instances, however, bronchotomy is necessary for removal of the peanut that, if allowed to remain in the bronchus, causes pneumonia, abscess, and bronchiectasis. In our cases, one patient had undergone two previous unsuccessful attempts at bronchoscopic removal of the peanut fragment and was scheduled to undergo thoracotomy and lobectomy if the third bronchoscopy did not result in extraction of the peanut; in the other two patients the peanuts had been present for 2–10 weeks.

Nebulized dilute racemic epinephrine has been used for nearly two decades to reduce mucosal edema associated with laryngotracheobronchitis (LTB)<sup>9,10</sup> and airway edema after tracheal extubation.<sup>11,12</sup> Racemic epinephrine is given for its vasoconstrictor effect on mucosa, rather than a bronchodilator effect. Only the l-isomer of epinephrine is pharmacologically active. The racemic mixture is associated with a lesser incidence of cardiac effects compared with the active l-isomer. When administered through a hand-held nebulizer, with the nebulized mixture inhaled through the mouth, a typical dose is 0.5 ml

of 2.25% racemic epinephrine diluted with 2.5–3 ml of saline or water.<sup>10</sup> For direct administration through the bronchoscope, an extremely dilute mixture (0.1 ml of 2.25% racemic epinephrine diluted in 5 ml of saline) was employed. In adults, the use of topical epinephrine (diluted<sup>17</sup> or undiluted<sup>18</sup>) for vasoconstriction during bronchoscopy has been recommended. Liquid epinephrine, however, is rapidly absorbed from the tracheobronchial tree and produces cardiovascular effects.<sup>19</sup> This extremely small and dilute dose of nebulized racemic epinephrine was selected with the hope that it would produce local vasoconstriction and reduction of mucosal edema in the affected bronchial mucosa and that the risk of generalized absorption of epinephrine from the bronchial tree would be minimal. To avoid unwanted cardiovascular and hemodynamic instability, a high fractional inspired O<sub>2</sub> content (FI<sub>O<sub>2</sub></sub>) and adequate ventilatory support were administered, and inhaled anesthetics that do not sensitize the myocardium to catecholamines (enflurane, isoflurane) were employed during the actual bronchoscopies.

In summary, extremely dilute racemic epinephrine was administered through the bronchoscope to facilitate removal of firmly impacted peanut fragments in three small children. The successful extraction of the peanuts and minimal associated cardiovascular changes suggest that the goals of producing vasoconstriction of the bronchial mucosa with minimal systemic absorption of epinephrine were accomplished. The released fragments were removed, and the patients did not require further surgery.

### REFERENCES

1. FDA Drug Bulletin 14:8–9, 1984
2. Baker SP, Fisher RS: Childhood asphyxiation by choking or suffocation. *JAMA* 244:1343–1346, 1980.
3. Ross AHM, McCormack RJM: Foreign body inhalation. *J R Coll Surg Edinb* 25:104–109, 1980
4. Kosloske AM: Bronchoscopic extraction of aspirated foreign bodies in children. *Am J Dis Child* 136:924–927, 1982
5. Brown TCK: Bronchoscopy for removal of foreign bodies in children. *Anaesth Intensive Care* 1:521–525, 1973
6. Burrington JD, Cotton EK: Removal of foreign bodies from the tracheobronchial tree. *J Ped Surg* 7:119–122, 1972
7. Chatterji S, Chatterji P: The management of foreign bodies in air passages. *Anaesthesia* 27:390–395, 1972
8. Keith FM, Charrette EJP, Lynn RB, Salerno TA: Inhalation of foreign bodies by children: A continuing challenge in management. *Can Med Assoc J* 122:52–57, 1980
9. Jordan WS: Laryngotracheobronchitis—Evaluation of new therapeutic approaches. *Rocky Mt Med J* 63:69, 1966
10. Adair JC, Ring WH, Jordan WS, Elwyn RA: Ten-year experience with IPPB in the treatment of acute laryngotracheobronchitis. *Anesth Analg* 50:649–655, 1971
11. Jordan WS, Graves CL, Elwyn RA: New therapy for postintubation laryngeal edema and tracheitis in children. *JAMA* 212:585–588, 1970
12. France NK: *Anesthesia for pediatric ENT*, Pediatric Anesthesia. Edited by Gregory GA. New York, Churchill Livingstone, 1983, pp 803–842

13. Fries JH: Peanuts: Allergic and other untoward reactions. *Ann Allergy* 48:220-226, 1982
14. Kosloske AM: Tracheobronchial foreign bodies in children: Back to the bronchoscope and a balloon. *Pediatrics* 66:321-323, 1980
15. Kam CA, Somasundaram K, Liew RPC: Bronchoscopic removal of peanut foreign body with Fogarty's catheter. *Anaesth Intensive Care* 5:272, 1977
16. Kosloske AM: The Fogarty balloon technique for the removal of foreign bodies from the tracheobronchial tree. *Surg Gynecol Obstet* 55:72-73, 1982
17. Zavala DC: Pulmonary hemorrhage in fiberoptic transbronchial biopsy. *Chest* 70:584-586, 1976
18. Sackner MA: Bronchofiberscopy. *Am Rev Resp Dis* 111:62-88, 1975
19. Chernow B, Holbrook P, D'Angona DS, Zaritsky A, Casey LC, Fletcher JR, Lake CR: Epinephrine absorption from intratracheal administration. *Anesth Analg* 63:829-832, 1984

Anesthesiology  
65:525-528, 1986

## Neuromuscular Blockade in a Patient with Stiff-baby Syndrome

WILLIAM P. COOK, M.D.,\* RICHARD F. KAPLAN, M.D.†

Stiff-baby syndrome (hyperekplexia) is a rare genetic syndrome characterized by marked muscle rigidity immediately after birth.<sup>1-3</sup> The muscle stiffness persists during early infancy but disappears gradually during the first few years of life. Because there are no reports of anesthesia for or the effect of neuromuscular blocking drugs on patients with stiff-baby syndrome, we describe the responses of a patient with stiff-baby syndrome to anesthesia, succinylcholine, and pancuronium.

### REPORT OF A CASE

A 5-month-old, 6.3-kg boy with stiff-baby syndrome was admitted for repair of bilateral inguinal hernias. At birth he had been noted to be stiff and to startle easily. His father and paternal grandmother had had the same condition at birth. Both father and grandmother had had surgery and general anesthesia several times without any known complications, but the medical records had been destroyed by fire. A study of the infant was undertaken with the parents' informed consent.

Physical examination revealed a tense, stiff infant with a pinched, "worried" facial expression. His body, which was straight and rigid, did not sag when he was held supine and supported only by his occiput and his heels, or by a single hand under his waist (fig. 1). His arms and legs passively resisted movement and reflexes were hyperactive. The rest of the physical examination was remarkable only for bilateral inguinal hernias and an umbilical hernia. Although the infant had some choking associated with eating, there were no symptoms of gastroesophageal reflux. Preoperative hematocrit (Hct) was 31.5%, and urinalysis was within normal limits.

No preoperative medication was given. Anesthesia was induced and maintained by inhalation of halothane (1% end-tidal concentration according to mass spectroscopy) in N<sub>2</sub>O (60%) and O<sub>2</sub> (40%). Atropine, 0.1 mg, was given as soon as an iv line was inserted. The trachea was

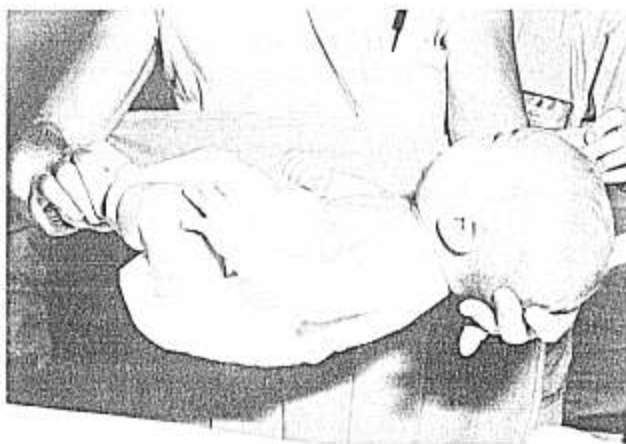
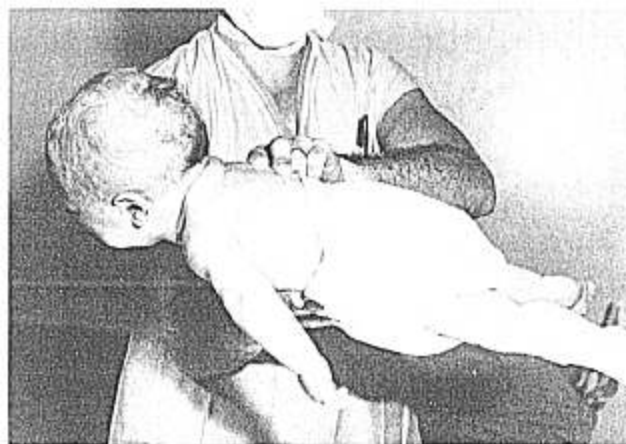


FIG. 1. The marked muscular rigidity of stiff-baby syndrome (hyperekplexia) in a 5-month-old boy.

\* Instructor and Special Fellow in Anesthesiology.

† Assistant Professor of Anesthesiology.

Received from the Department of Anesthesiology, University of Florida College of Medicine, Gainesville, Florida. Accepted for publication June 10, 1986.

Address reprint requests to Dr. Cook: Department of Anesthesiology, Box J-254, J. Hillis Miller Health Center, Gainesville, Florida 32610-0254.

Key words: Anesthesia: pediatric. Muscle, skeletal: hyperekplexia. Neuromuscular relaxants: pancuronium; succinylcholine.