

- Cousins MJ: Epidural neural block, *Neural Blockade in Clinical Anesthesia and Management of Pain*. Edited by Cousins MJ, Philip J, Bridenbaugh O. Philadelphia, JB Lippincott, 1980, pp 176-274
- Wallenstein SL: The evaluation of analgesics in man, *Analgesics: Neurochemical, Behavioral, and Clinical Perspectives*. Edited by Huhar M, Pasternak G. New York, Raven Press, 1984, pp 235-255
- Kileff ME, Jamer TM, Dewar DM, Floyd HM: Neonatal neuro-behavior responses after epidural anesthesia for cesarean section using lidocaine and bupivacaine. *Anesth Analg* 63:413-417, 1984
- Shnider SM, Levinson G: *Obstetric anesthesia, Regional Anesthesia*. Edited by Miller RD. New York, Churchill Livingstone, 1981, pp 1133-1173
- Thorburn J, Moir DD: Epidural analgesia for elective caesarean section. *Anaesthesia* 35:3-6, 1980
- Scanlon JW, Brown WV, Weiss JB, Alper MH: Neurobehavioral responses of newborn infants after maternal epidural anesthesia. *ANESTHESIOLOGY* 40:121-128, 1974
- James FM, Dewan DM, Floyd HM, Wheeler AS, Grant WM, Rhyne L, Westmoreland RT: Chloroprocaine versus bupivacaine for lumbar epidural analgesia for elective cesarean section. *ANESTHESIOLOGY* 52:488-491, 1980
- Carrie LES, O'Sullivan GM, Seegobin R: Epidural fentanyl in labor. *Anaesthesia* 36:965-969, 1981
- Bullingham RES, McQuay HJ: Unexpectedly high plasma fentanyl levels after epidural use (letter). *Lancet* 1:1361-1362, 1980

Anesthesiology  
65:334-338, 1986

## Traumatic Pseudoaneurysm of a Pulmonary Artery: Anesthetic Considerations

JAMES A. DiNARDO, M.D.\*

Traumatic pseudoaneurysm of the pulmonary artery is a rare vascular lesion with only seven cases reported since the entity was originally described in 1918 by Konjetzny.<sup>1</sup> Surgical resection of these lesions is recommended, as massive hemoptysis from rupture of the aneurysm into the bronchial tree can occur.<sup>1,2</sup> In addition the risk of an infected hemothorax<sup>3</sup> and the potential for development of a propagating clot in the traumatized vessel make resection indicated. Described is the anesthetic management of a patient who underwent resection of a traumatic pseudoaneurysm of the artery supplying the posterior basal segment of the left lower lobe.

### REPORT OF A CASE

A 37-yr-old man was admitted to the emergency room following an altercation in which he received two stab wounds to the left posterior chest with a 12-in kitchen knife. His past medical history was remarkable only for a history of alcohol abuse, a penicillin allergy, and a left tube thoracostomy at age 6 weeks for unknown indications. He had a systolic arterial blood pressure of 70-80 mmHg, a heart rate of 100 beats/min, and a respiratory rate of 30/min. A left chest tube, large bore iv cannulae, Foley catheter, and central venous line were inserted and the patient was given 5 l of lactated Ringer's solution and 2 units of

packed red blood cells iv. Subsequent chest roentgenogram revealed a left perihilar opacity consistent with a parenchymal hematoma (fig. 1). This impression was confirmed by a computerized axial tomography (CAT) scan obtained later the same day. The patient did well thereafter, with no symptoms and no alteration in his cardiovascular or respiratory status. With a fractional inspired O<sub>2</sub> concentration (F<sub>I</sub>O<sub>2</sub>) of 0.21, PaO<sub>2</sub> ranged from 78 to 85 mmHg. Three days later, a right upper lobe collapse was noted on a repeat chest roentgenogram. The patient was asymptomatic, and the collapse cleared with chest physical therapy.

Four days following injury, chest roentgenogram revealed that the left perihilar mass had increased in size and the diagnosis of a pulmonary artery pseudoaneurysm or arteriovenous (A-V) fistula was considered. A film obtained later that day showed the perihilar mass to be better defined and larger (fig. 2). A CAT scan with contrast on the next day revealed an intensely vascular 5.5 cm left perihilar mass felt to be highly suggestive of a pulmonary artery pseudoaneurysm or A-V fistula (fig. 3). A pulmonary artery angiogram done later that same day confirmed the presence of a pseudoaneurysm of the posterior basal segment artery of the left lower lobe (fig. 4). The patient remained asymptomatic.

The next day the patient was scheduled for resection of the pseudoaneurysm. At that time his hematocrit was 36.1% and his coagulation values were within normal limits. This 70-kg patient was premedicated with 10.0 mg of diazepam iv and brought to the operating room, where he had two peripheral 14-gauge iv cannulae, a 16-gauge right external jugular vein cannula, and a 20-gauge right radial artery cannula inserted. Anesthesia was induced with fentanyl 300 µg, thiopental 500 mg, and pancuronium 7 mg iv. Following ventilation with isoflurane 1% in 100% O<sub>2</sub>, the trachea was intubated with an 8.0 mm ID endotracheal tube and flexible fiberoptic bronchoscopy was performed by the surgeon to rule out any bronchial injury. No injury was detected, and the trachea was reintubated with a 37 French OD Bronchocath® left-sided double-lumen endotracheal tube. Proper tube position was verified with use of a pediatric fiberoptic bronchoscope. Differential lung ventilation was verified by auscultation. The patient was positioned for a left thoractomy, and differential ventilation was again verified.

Due to the patient's previous closed tube thoracostomy as a child, the visceral and parietal pleura were adherent and dense adhesions

\* Instructor in Anaesthesia, Harvard Medical School, and Co-Director, Division of Cardiac Anaesthesia.

Received from the Department of Anaesthesia and Respiratory Therapy, Beth Israel Hospital, 330 Brookline Avenue, Boston, Massachusetts 02215. Accepted for publication May 5, 1986.

Address reprint requests to Dr. DiNardo.

Key words: Anesthesia; thoracic. Arteries: pseudoaneurysm; pulmonary. Equipment: tubes, endobronchial.



FIG. 1. Chest roentgenogram revealing a left perihilar parenchymal hematoma at the time of admission. The arrows outline the hematoma.

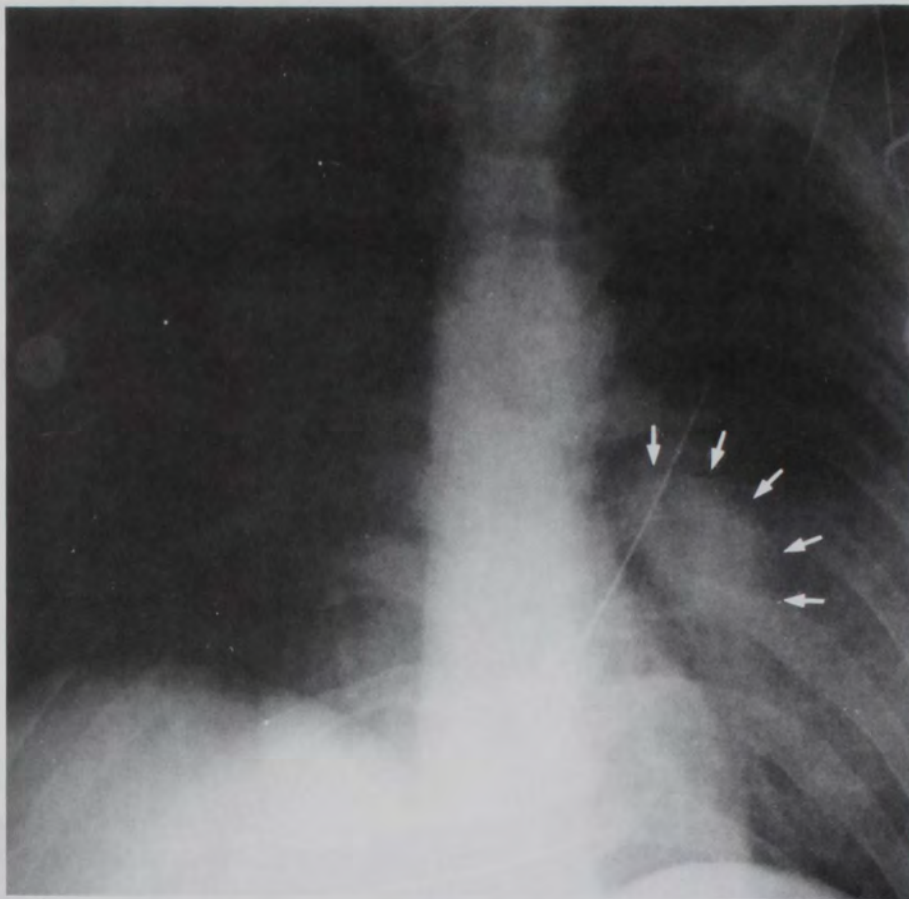


FIG. 2. Chest roentgenogram revealing a discrete left perihilar mass consistent with a pulmonary artery pseudoaneurysm or arteriovenous fistula. The arrows outline the mass.

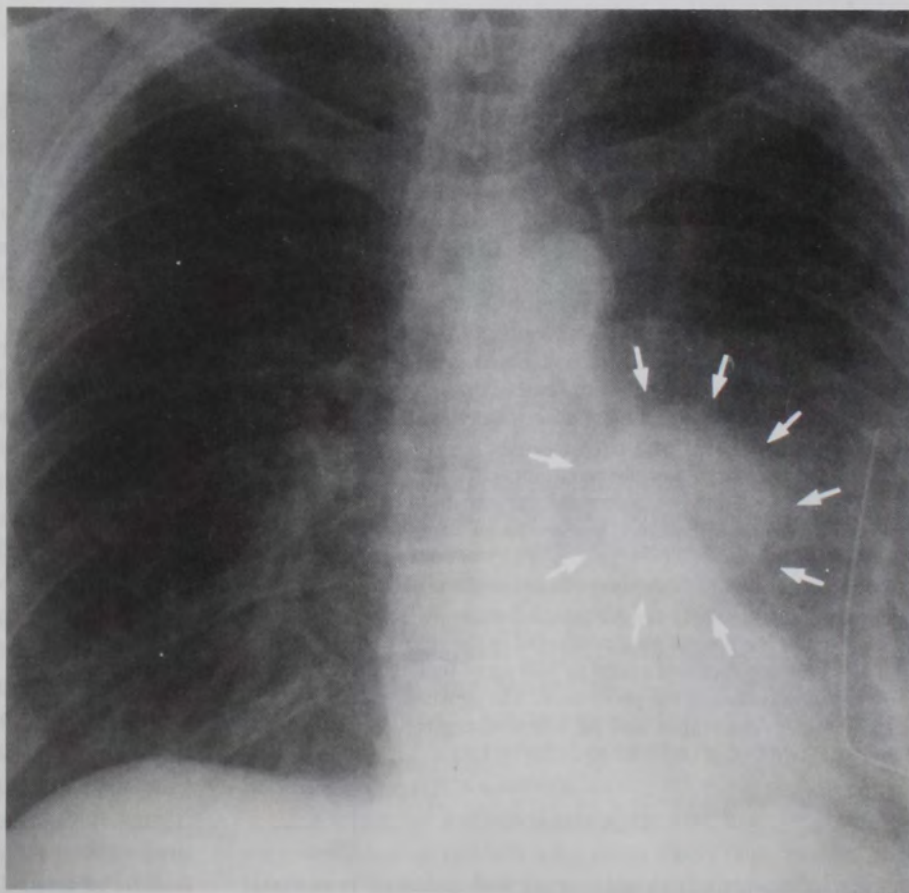



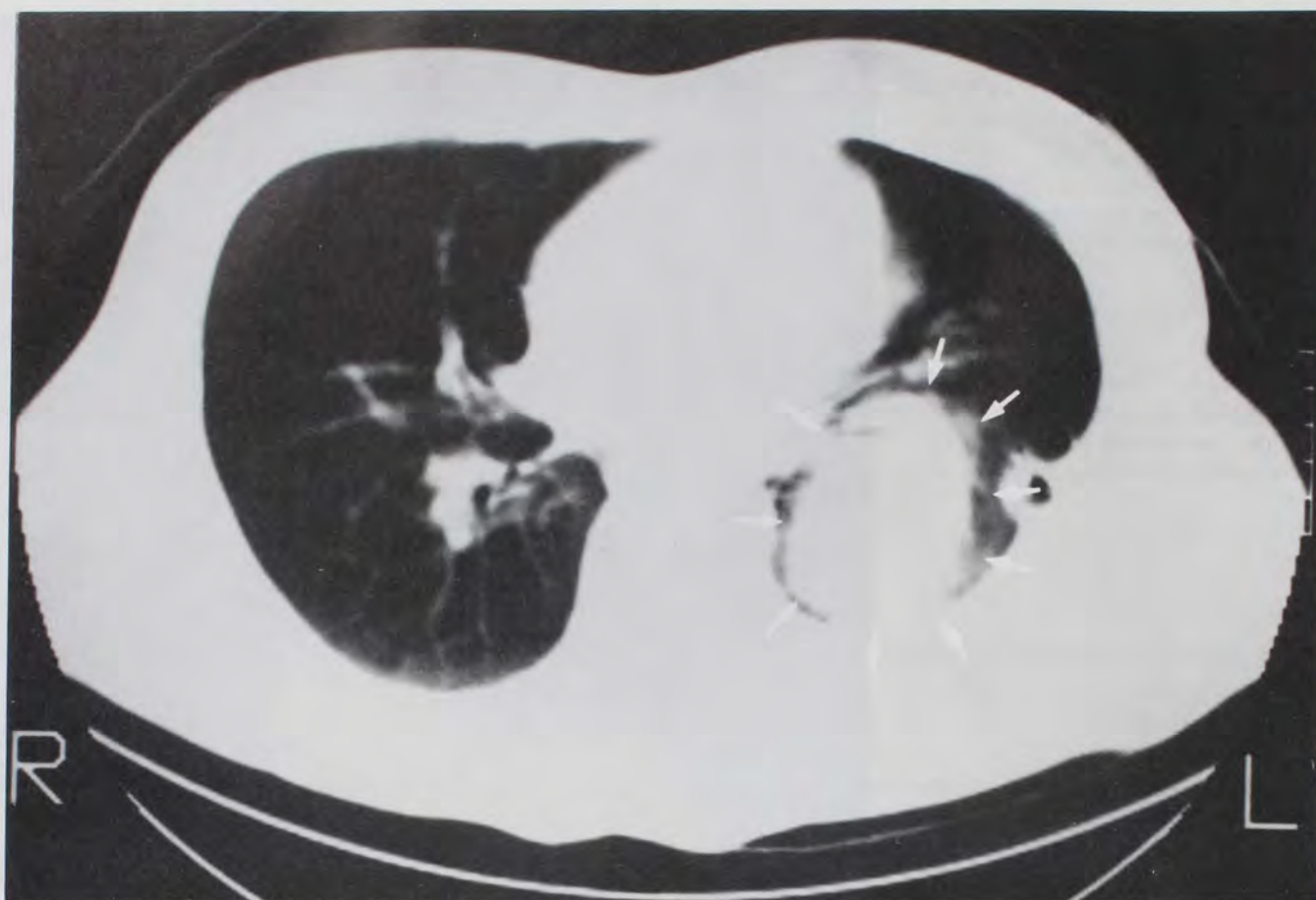


FIG. 3. CAT scan with contrast demonstrating an intensely vascular 5.5 cm left perihilar mass. The arrows outline the mass.

had to be lysed. When the left lung deflated secondary to selective ventilation of the right lung, brisk extrabronchial hemorrhage from the pseudoaneurysm site was encountered. This was ultimately controlled, and the patient underwent a left lower lobectomy. Intraoperatively the patient required 7 units of packed red blood cells, 5 l of lactated Ringer's solution, and 840 ml of autologous washed packed red blood cells concentrated from 2,200 ml of blood salvaged from the surgical field. A Sorenson Autotransfusion System® was used to collect and heparinize the blood, while an IBM Cell Processing System® was used to wash and concentrate it. Serial analysis of hematocrit, platelet count, and prothrombin and partial thromboplastin times and were within normal limits, and no other component therapy was necessary.

One-lung anesthesia was managed uneventfully with isoflurane 1–2% in 100% O<sub>2</sub>. A pulse oximeter and infrared end-tidal CO<sub>2</sub> monitor provided continuous indirect assessment of arterial O<sub>2</sub> saturation and PaCO<sub>2</sub>.

Neuromuscular blockade was reversed at the end of the procedure with edrophonium 60 mg and atropine 0.8 mg iv. Following extubation of the trachea the patient was transferred to the recovery room awake and alert, having received a total of 900 µg of fentanyl and 18 mg of pancuronium iv during the procedure. The remainder of his hospital course was unremarkable, and he was discharged home on hospital day 13.

#### DISCUSSION

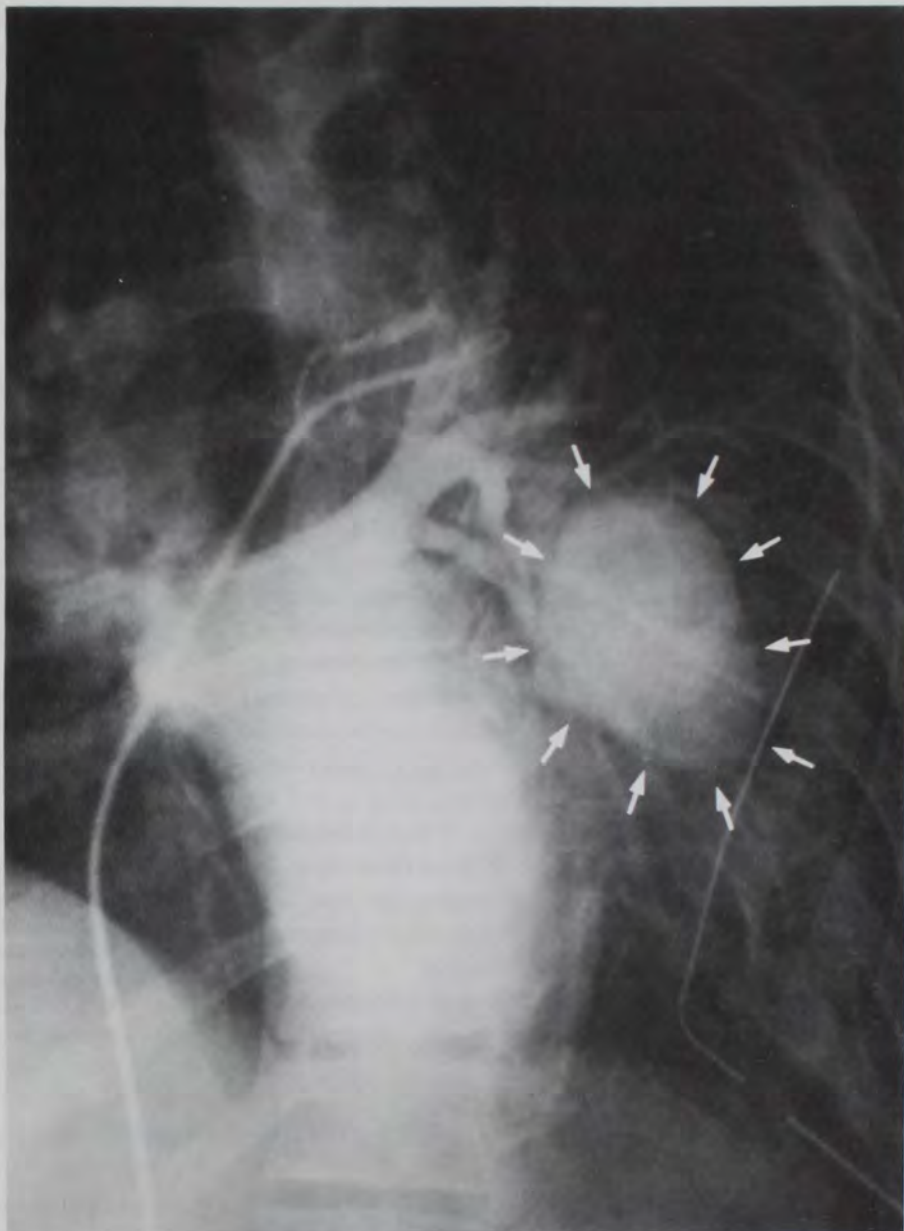
Of the seven previously reported cases of traumatic pulmonary artery aneurysm, five were due to penetrating

chest trauma and two to blunt chest trauma; this case represents the sixth reported case due to penetrating trauma. This patient was asymptomatic; his lesion was detected by examination of serial chest roentgenograms. Of the previously reported cases only one patient was asymptomatic at the time of presentation. That patient was noted to have a 2.5 × 4 cm left mid-lung-field lesion on a pre-operative chest roentgenogram 26 yr after suffering a gunshot wound to the left chest.<sup>4</sup> Of the six remaining cases the clinical presentation of one patient following blunt trauma is unknown<sup>5</sup>; two patients presented with massive hemoptysis within 2 months of a penetrating injury<sup>1,2</sup>; one patient presented with an infected hemothorax and hemoptysis 15 days following a penetrating injury<sup>3</sup>; one patient developed low grade intermittent hemoptysis during the 2-month period in which he was followed for a left lower lobe density that persisted after penetrating trauma<sup>6</sup>; and, one patient presented with a clinical picture and a ventilation perfusion scan consistent with a pulmonary embolus in the first week following blunt trauma.<sup>7</sup> One can only speculate as to whether my patient would have remained asymptomatic, as surgical intervention was undertaken so promptly.

The potential for rupture of the pseudoaneurysm into the bronchial tree prior to or during surgical exposure



FIG. 4. Representative frame of the pulmonary artery angiogram demonstrating a pseudoaneurysm of the posterior basal segment artery of the left lower lobe. The arrows outline the pseudoaneurysm.



of the involved pulmonary artery represents one of the few absolute indications for placement of a double-lumen endotracheal tube. Ideally then, intrabronchial hemorrhage would be limited to one lung, should it occur. In addition, a double-lumen endotracheal tube maximizes surgical exposure should a pneumonectomy be necessary for resection of the pseudoaneurysm. In one of the reported cases<sup>7</sup> a pneumonectomy was in fact necessary. In my case, as in the three others in which the surgical procedure was reported<sup>3,4,6</sup> a lobectomy sufficed. Proper placement of a right-sided endotracheal tube is more difficult to obtain even with fiberoptic bronchoscopy and offers no clear advantage in providing complete isolation of the lungs unless a left pneumonectomy is performed. A left pneumonectomy can be managed with a left-sided endotracheal tube if the tube is withdrawn into the trachea

prior to resection of the left main stem bronchus. However, if hemorrhage occurs into the left lung, the right lung may be contaminated with blood or obstructed with clot as the left-sided tube is withdrawn prior to ligation of the left main-stem bronchus. Theoretically, if the pseudoaneurysm involves a main pulmonary artery and is in danger of eroding into a main stem bronchus, then placement of a double-lumen endotracheal tube in that bronchus would be contraindicated as massive hemorrhage could be initiated. This patient was known to have a pseudoaneurysm of a peripheral pulmonary artery, and this was therefore not a concern.

The onset of extrabronchial hemorrhage coincident with deflation of the left lung most likely represented disruption of the clot and fibrous tissue that are felt to form the pseudoaneurysm and tamponade the bleeding in the



low pressure pulmonary arterial circuit.<sup>4</sup> This emphasizes the need for large-bore iv access for intravascular fluid administration in these patients. When available, a system that allows blood from the surgical field to be collected, heparinized, washed, and centrifuged to produce a concentrate of autologous red blood cells<sup>8</sup> can be used as it was in this case.

Traumatic pulmonary arteriovenous fistulas are also very rare lesions with only three cases reported in the literature.<sup>6,9,10</sup> All three were the result of penetrating chest trauma. Hypoxemia secondary to an intrapulmonary right-to-left shunt was a consistent finding. One patient demonstrated persistent hypoxemia and intermittent hemoptysis commencing 2 days after stab wounds to the chest.<sup>6</sup> Hypoxemia, clubbing, cyanosis, and secondary erythrocytosis were noted in two patients in whom the diagnosis was made 10 and 31 years, respectively, after the initial injury.<sup>9,10</sup> The absence of hypoxemia weighed more heavily in favor of a pulmonary artery pseudoaneurysm than a pulmonary arteriovenous fistula in my patient.

As was true in this case, others have found pulmonary artery pseudoaneurysms and A-V fistulas to be most definitively demonstrated by pulmonary arteriography.<sup>6,7,9,10</sup> A chest roentgenogram revealing a well circumscribed and persistent radiodense lesion at the site of lung injury should arouse suspicion that these rare, but potentially lethal, lesions exist. If, as was the case here, the radiographic lesion becomes progressively larger, the index of suspicion should be even higher.

Traumatic pseudoaneurysm of the pulmonary artery is a rare, potentially lethal, but surgically correctable le-

sion. Appropriate anesthetic management necessitates insertion of a double-lumen endotracheal tube, both to ensure isolation of the lungs should intrabronchial rupture occur and to facilitate surgical exposure. In addition, adequate iv access for intravascular fluid replacement is essential. A system for salvaging, washing, and concentrating autologous blood will reduce the need for nonautologous blood transfusions.

#### REFERENCES

1. Konjetzny GE: Zur prognose der lungenschussverletzungen. *Mitt Grenzgeb Med Chir* 30:671-688, 1918
2. Marble HC, White PD: Traumatic aneurysm of the right pulmonary artery. *JAMA* 74:1778, 1920
3. Hohlweg E: Operativ geheiltes traumatisches aneurysma einer lungenarterie. *Chirug* 19:373-376, 1948
4. Symbas PN, Scott HW: Traumatic aneurysm of the pulmonary artery. *J Thorac Cardiovasc Surg* 45:645-649, 1963
5. Hornaersche P: Aneurysm of the pulmonary artery. *Rev Med Uruguay* 27:316, 1924
6. Symbas PN, Goldman M, Erbesfeld H, Vlasia PA: Pulmonary arteriovenous fistula, pulmonary artery aneurysm, and other vascular changes of the lung from penetrating trauma. *Ann Surg* 191:336-340, 1980
7. Dillon WP, Taylor AT, Mineau DE, Datz FL: Traumatic pulmonary artery pseudoaneurysm simulating pulmonary embolus. *Am J Roentgenol* 139:818-819, 1982
8. Hauer JM: Autotransfusion in trauma surgery, Autotransfusion. Edited by Hauer JM, Thurer RT, Dawson RB. New York, Elsevier North-Holland, 1981, pp 93-105
9. Arom KV, Lyons GW: Traumatic pulmonary arteriovenous fistula. *J Thorac Cardiovasc Surg* 70:918-920, 1975
10. Loebl EC, Platt MR, Mills LJ, Estrera AS: Pulmonary resection for a traumatic pulmonary arteriovenous fistula. *J Thorac Cardiovasc Surg* 77:674-676, 1979