

6. Michenfelder JD, Milde JH, Sundt TM Jr: Cerebral protection by barbiturate anesthesia: Use after middle cerebral artery occlusions in Java monkeys. *Arch Neurol* 33:345-350, 1976
7. Yatsu FM, Diamond I, Graziana C, Lindquist P: Experimental brain ischemia: Protection from irreversible damage with a rapid-acting barbiturate (methohexital). *Stroke* 3:726-732, 1972
8. Snyder JV, Nemoto EM, Carroll RG, Safar P: Global ischemia in dogs: Intracranial pressures, brain blood flow and metabolism. *Stroke* 6:121-127, 1975
9. Kofke WA, Nemoto EM, Hossmann KA, Taylor F, Kessler PD, Stezoski SW: Brain blood flow and metabolism after global brain ischemia and post-insult thiopental therapy in monkeys. *Stroke* 10:554-560, 1979
10. Kagstroem E, Smith ML, Siesjo BK: Local cerebral blood flow in

- the recovery period following complete cerebral ischemia in the rat. *J Cereb Blood Flow Metab* 3:170-182, 1983
11. Hossmann KA: Treatment of experimental cerebral ischemia. *J Cereb Blood Flow Metab* 2:275-297, 1982
12. Safar P, Vaagenes P: Systematic search for brain resuscitation potentials after total circulatory arrest, NATO Conference on Mechanisms of Secondary Brain Damage, 1984. Edited by Baethmann A, Go KG, Unterberg A. New York, Plenum Press, 1986 (In press)
13. Gisvold SE, Safar P, Hendrickx HHL, Rao G, Moossy J, Alexander H: Thiopental treatment after global ischemia in pigtailed monkeys. *ANESTHESIOLOGY* 60:88-96, 1984
14. Yatsu FM: Cardiopulmonary cerebral resuscitation (editorial). *N Engl J Med* 314:440-441, 1986

(Accepted for publication May 8, 1986.)

Anesthesiology
65:235, 1986

In reply:—'Tis true that I initially criticized their primate model (because they failed to demonstrate absence of cerebral blood flow in individual animals during ischemia and because neurologic function was assessed by a nonblinded observer). 'Tis also true that we later invited a then *past* member of the Pittsburgh group (Gisvold) to introduce the basic model into our laboratory. The final truth is that we modified the model in order to demonstrate absence of cerebral blood flow in individual animals during ischemia and to provide for blinded evaluation of the animal's neurologic status postischemia.¹ It is now a good model.

JOHN D. MICHENFELDER, M.D.
*Professor of Anesthesiology
Mayo Medical School and Mayo Clinic
Rochester, Minnesota*

REFERENCE

1. Steen PA, Gisvold SE, Milde JH, Newberg LA, Scheithauer BW, Lanier WL, Michenfelder JD: Nimodipine improves outcome when given after complete cerebral ischemia in primates. *ANESTHESIOLOGY* 62:406-414, 1985

(Accepted for publication May 8, 1986.)

Anesthesiology
65:235-236, 1986

Position of Proximal Orifice Determines Electrocardiogram Recorded from Multiorificed Catheter

To the Editor:—Johans¹ reported that the intravascular electrocardiogram (ECG) monitored with a multiorificed catheter depends on the position of the proximal orifice, and that further work is needed to explain this finding. Examination of the electrical principles involved make this finding predictable.

The saline-filled catheter is a conductor with a different voltage source at each orifice provided by the summed electrical activity of the heart at that orifice. The electrocardiograph is electrically connected to the proximal orifice by a column of saline with impedance Z_c . The voltage measured by the electrocardiograph, V_{ECG} , is related to

the voltage at the proximal orifice, V_p , by the following equation:

$$V_{\text{ECG}} = V_p - I_c Z_c$$

where I_c is the current flowing from the orifice to the electrocardiograph. Because the electrocardiograph has a high-input impedance compared with Z_c , I_c approaches 0, and V_{ECG} must nearly equal V_p . Johans' observation that this relationship is true confirms the expectation that the summed electrical activity of the heart at the proximal orifice provides an independent voltage source unaffected by voltages at more distal orifices.

DAVID O. WARNER, M.D.

Resident in Anesthesiology

ROY F. CUCCHIARA, M.D.

*Associate Professor of Anesthesiology**Mayo Clinic**Rochester, Minnesota*

REFERENCE

1. Johans TG: Multiorificed catheter placement with an intravascular electrocardiographic technique. *ANESTHESIOLOGY* 64:411-413, 1986

*(Accepted for publication April 11, 1986.)*Anesthesiology
65:236, 1986

The Use of an Extension Line in Epidural Anesthesia

To the Editor:—Two options that exist for epidural injection are through the needle or through the catheter. Those who prefer the needle as an injection port usually attach the syringe to the needle, then introduce incremental doses of local anesthetic with or without removal of the syringe.

As a modification of the traditional "injection by needle" technique, we place an extension line with a "T" (Abbott® 4616) between the Touhy needle and the syringe (fig. 1). The connector requires only 0.33 ml for priming and has little effect on the typical sensation during the injection, while the built-in clamp prevents back-flow.

In addition, the absence of a Luer®-type twist lock between the needle and the extension line makes the connection simple, further reducing the risk of inadvertent reposition of the needle.

SIMON GURMARNIK, M.D.

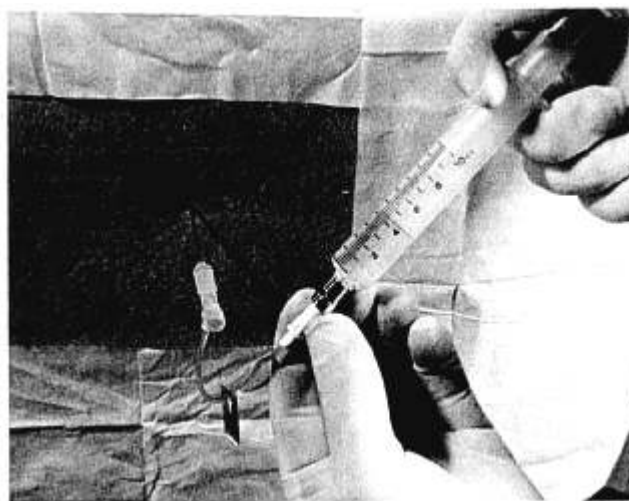
*Department of Anesthesiology**The Park City Hospital**695 Park Avenue**Bridgeport, Connecticut 06604*

FIG 1. Illustration of extension line for epidural anesthesia.

*(Accepted for publication April 11, 1986.)*Anesthesiology
65:236-237, 1986

Tracheo-bronchial Angles in Infants and Children

To the Editor:—The article by Kubota *et al.*¹ documents the fact that there is indeed a difference in the angles subtended by the left and right mainstem bronchi at the carina in infants and children. They have, hopefully, settled a long-standing controversy.

However, they quote Brown and Fisk² (not Fish) as stating that the bevel of the endotracheal tube usually lies to the right on insertion. The fact is that the bevel of the tube faces to the left following insertion, as stated by Brown and Fisk, and the tip of the tube therefore lies to the right of the midline of the trachea. This is the reason

for the fact that the tube invariably enters the right mainstem bronchus. The normal bronchial angles are of no real significance. In fact, if one wishes deliberately to advance the tube into the left bronchus, it can be done by rotating the tube through 180° before advancing it beyond the carina.

EDMOND C. BLOCH, F.F.A.R.C.S.

*Associate Professor of Anesthesiology**Duke University Medical Center**Durham, North Carolina 27710*