

lymphocytes, and other plasma cells. Our technique of platelet preparation yields extremely pure platelet fractions with few, if any, other cell types present. Because the pure platelet fractions used in the test do not present the metabolic characteristics associated with malignant hyperthermia (MH), we question the cellular source of the changes found in Solomons and Masson's experiments. Moreover, O'Brien *et al.* have shown that Ca^{++} -dependent ATPase and other erythrocyte enzymes involved in ATP metabolism, as well as erythrocyte fragility, are directly affected in MH.² Perhaps Solomons and Masson's results are reproducible in erythrocytes or erythrocyte-contaminated platelet preparations only.

We agree that nucleotide fractions cannot be stored. In fact, they cannot be stored at an acid pH; the acid must be neutralized prior to storage or the nucleotides will be destroyed, as we demonstrated in our study.³

We agree with Solomons' observation that our patients exhibited widely variable clinical symptoms, but we strongly disagree with his impression that these clinical symptoms are incomplete. A clinical episode of MH is diagnosed by several, but not necessarily all, of the following symptoms, including muscle rigidity, and changes in arterial and venous blood gas values, core temperature, pulse, respiratory rate, serum creatinine kinase (CK), and myoglobin levels following administration of a triggering agent. All of our three patients who had MH reactions without follow-up muscle biopsies had many but not all of these symptoms. However, no disease requires all of its possible symptoms to exist, and MH is not an exception.

Laboratory analysis of muscle biopsy samples from seven of our ten MH-susceptible patients served, in these

seven cases, to confirm our clinical diagnosis. While we are happy to have muscle biopsy results in these cases, it is well known that MH responses to triggering agents were originally observed, diagnosed, and treated in patients before the advent of laboratory diagnostic aids, and absence of such aids should not be misconstrued to indicate an incomplete or inaccurate diagnosis. Furthermore, if Solomons' platelet nucleotide assay had been effective in diagnosing MH, any diagnostic discrepancies between our test subjects would have been apparent in the nucleotide patterns from these patients. This was not the case.

LEILA EDWARDS, PH.D.

Clinical Assistant Professor

Departments of Biochemistry, Pathology, Medical Technology, and Medicine

MICHAEL G. ADRAGNA, M.D.

Assistant Professor of Anesthesiology

State University of New York at Buffalo and Erie County Medical Center

Buffalo, New York 14215

REFERENCES

1. Tuszyński GP, Daniel JL, Stewart G: Association of proteins with the platelet cytoskeleton. *Semin Hematol* 22:303-312, 1985
2. O'Brien PJ, Forsyth GW, Olexson DW, Thatte HS, Addis PB: Canine malignant hyperthermia susceptibility: Osmotic fragility, glucose-6-phosphate dehydrogenase deficiency and abnormal Ca^{++} homeostasis. *Can J Comp Med* 48:381-389, 1984
3. Lee MB, Adragna MG, Edwards L: The use of a platelet nucleotide assay as a possible diagnostic test for malignant hyperthermia. *ANESTHESIOLOGY* 63:311-315, 1985

(Accepted for publication December 18, 1985.)

Another Approach to the Problem Airway

To the Editor:—Direct airway endoscopy for awake nasal intubation in problem situations was one of the early uses described for the flexible fiberoptic bronchoscope.¹ However, this technique is usually used in the operating room as a last resort approach to a difficult intubation. Under pressured conditions when the airway is compromised by secretions, blood, or edema, the failure rate is high. Patil *et al.* have described several mechanical aids for fiberoptic endoscopy using a mask with an endoscopic port or an oral airway with a Rowbotham connector.² They have also suggested the use of binasal airways for ventilation during oral endoscopic intubation. Rogers and Benumof devised a technique whereby a fiberoptic endoscope could be inserted through a plastic, oropharyngeal airway with a cylindric passage along the midlongitudinal axis.³ Although undoubtedly useful, the techniques require special equipment not always immediately

available and presuppose that the mouth can be opened. We have developed a means to approach the difficult airway avoiding the oral cavity in a controlled and safe manner, using only a standard nasal airway.

After sedating the patient, the nasal mucosa is vasoconstricted by a few drops of phenylephrine. Local anesthesia of the upper airway is achieved by topical application of lidocaine, supralaryngeal nerve block, and transcriothyroid block. A nasal airway fitted to an adapter connected to the breathing circuit of an anesthetic machine is inserted in one nostril (fig. 1). When awake intubations are indicated (*e.g.*, full stomach, facial fractures, *etc.*), oxygen delivery is maintained. Under elective circumstances, when difficulty in intubation may be anticipated, analgesia is achieved by breathing low doses of inhalation agents. Spontaneous respiration is maintained. A second nasal airway, slit lengthwise, is used as a guide

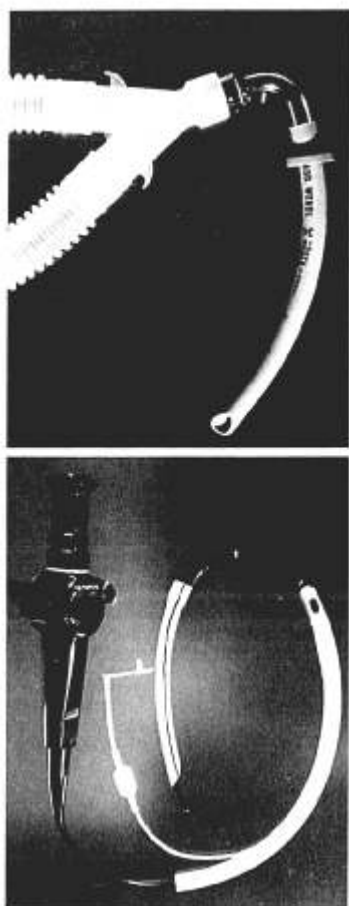


FIG. 1 (upper). A nasal airway with an adapter connected to the breathing circuit.

FIG. 2 (lower). A nasal airway with a longitudinal slit is used as a guide for the insertion of the fiberoptic bronchoscope during nasotracheal intubation.

for the insertion of the flexible fiberoptic bronchoscope in the other nostril (fig. 2). When adequate visualization of the cords is obtained, the nasal airway is removed and the prepositioned endotracheal tube is slipped over the bronchoscope into the trachea. The technique is advantageous in that intubation is achieved with minimal trauma and discomfort to the patient.

GABRIEL P. LU, M.D.
Assistant Professor

ELIZABETH A. M. FROST, M.D.
Professor

PAUL L. GOLDINER, M.D.
Professor and Chairman

*Department of Anesthesiology
Albert Einstein College of Medicine
of Yeshiva University
1300 Morris Park Avenue
Bronx, New York 10461*

REFERENCES

1. Murphy P: A fibre-optic endoscope used for nasal intubation. *Anaesthesia* 22:489-491, 1967
2. Patil V, Stehling LC, Zauder HL, Koch JP: Mechanical aids for fiberoptic endoscopy. *ANESTHESIOLOGY* 57:69-70, 1982
3. Rogers SN, Benumof JL: New and easy techniques for fiberoptic endoscopy aided tracheal intubation. *ANESTHESIOLOGY* 59: 569-572, 1983

(Accepted for publication March 6, 1986.)

Anesthesiology
65:102-103, 1986

CPAP Oxygenation during One-lung Ventilation Using an Underwater Seal Assembly

To the Editor:—During one-lung ventilation (OLV), oxygenation can be optimized by insufflating oxygen at 10 cmH₂O into the nonventilated lung.¹ This letter describes a simple device using an underwater seal (fig. 1) that can function as a device for applying continuous positive airway pressure (CPAP) to the nonventilated lung as well as a bronchial seal indicator.² When the oxygen flowmeter is off, the device becomes a simple underwater seal that functions as an indicator for a precise end-point inflation of the bronchial cuff. To provide CPAP oxygenation during OLV, the oxygen flowmeter is turned on; the required CPAP is controlled by the level of the underwater seal and checked by an aneroid manometer.

The device was used in eight adult patients undergoing thoracotomy in the lateral position. Anesthesia was induced by thiopental 5 mg/kg and succinylcholine 1.5 mg/kg. The patients' tracheas were then intubated with Robertshaw double-lumen tubes with the bronchial limb corresponding to the nonoperated lung. Anesthesia was

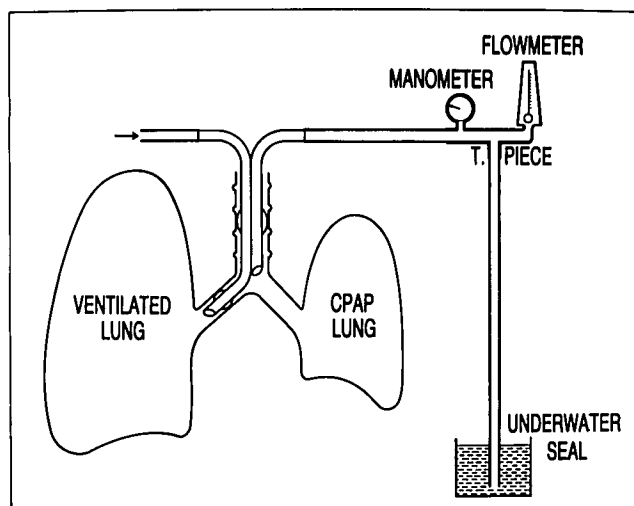


FIG. 1. Diagram of the underwater seal-oxygen flowmeter assembly. The device is attached by a tubing to the limb of the double-lumen tube corresponding to the nonventilated lung.