

KEVIN K. TREMPER, PH.D., M.D.
*Associate Professor and Chairman
Department of Anesthesiology*

STEPHEN Z. GARBER, M.D.
Fellow in Obstetrical Anesthesia

*University of California, Irvine Medical Center
Department of Anesthesiology, Route 81A
101 City Drive South
Orange, California 92668*

REFERENCES

1. Murray IP, Modell JH: Early detection of endotracheal tube accidents by monitoring carbon dioxide concentration in respiratory gas. *ANESTHESIOLOGY* 59:344-346, 1983
2. Shnider SM, Levinson G: *Anesthesia for cesarean section, Anesthesia for Obstetrics*. Edited by Shnider SM, Levinson G. Baltimore, Williams and Wilkins, 1979, pp 262-263
3. Peters RM: Monitoring of ventilation in the anesthetized patient, *Monitoring Surgical Patients in the Operating Room*. Edited by Gravenstein JS, Newbower RS, Ream AK, Smith NT. Springfield, Charles C Thomas, 1979, pp 142-149

(Accepted for publication December 25, 1985.)

Anesthesiology
64:830-831, 1986

Real-time Ultrasonic Guidance for Percutaneous Puncture of the Internal Jugular Vein

To the Editor:—Anatomical landmarks¹ and ultrasound Doppler flowmetry² have been employed for the location of the internal jugular vein (IJV). We have used transcutaneous ultrasonographic scanning to determine the precise location of the IJV and to observe the procedures of venous puncture and catheterization. An ultrasonographic scanner (Echo® Camera, Model SSD-256, Aloka, Japan) equipped with a 5 MHz ultrasound transducer was used to obtain the real-time ultrasound images. With the head rotated approximately 45 degrees contralateral to the side of the puncture, povidone iodine gel was used as the acoustic coupling medium. The probe was sterilized with ethylene oxide and applied longitudinally to the neck (fig. 1). The carotid artery is the only observable structure that bears a fixed relationship to the IJV at the levels scanned.³ Both the IJV and carotid artery are identified as echo-free band images on the oscilloscope (fig. 2). Dur-

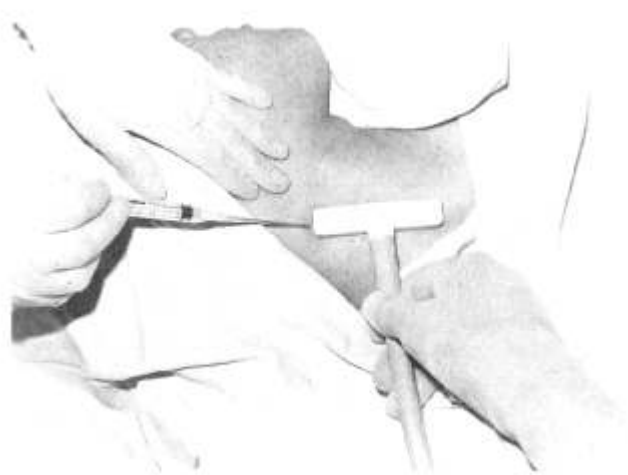


FIG. 1. Puncture of the right internal jugular vein. T-shaped probe is positioned in right internal jugular vein.

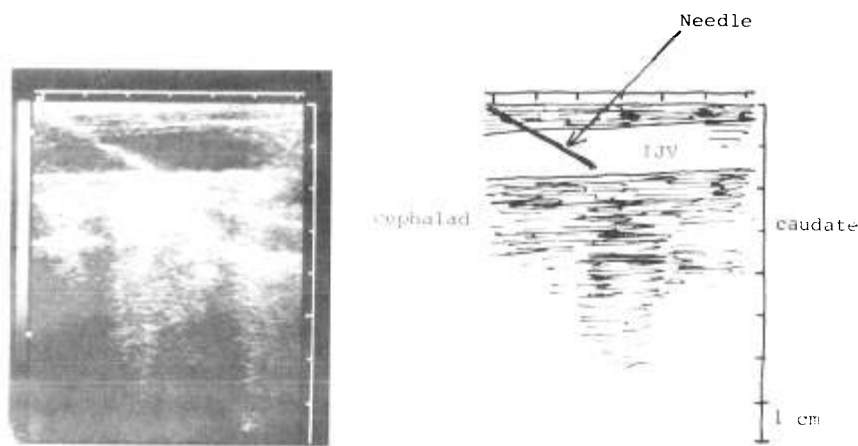


FIG. 2. The longitudinal ultrasound image of the internal jugular vein with the puncture needle in place. The internal jugular vein is observed as an echo-free band.

ing the respiratory cycle, the diameter of the IJV changes, and when pressure is applied with the probe, the vein collapses and the carotid artery does not. The IJV was identified easily by these ultrasonic findings. The physician stands at the patient's head and introduces the needle caudally through the skin just under the probe. The needle at a depth of 1 cm can be visualized as an ultrasonic image on the oscilloscope. The correct angle and depth of the needle was determined from the ultrasonic image (fig. 2). Puncture of the IJV was confirmed by aspiration of dark blood, and the cannula was then advanced down the needle into the vein and the needle was withdrawn. A guidewire for a Swan-Ganz® catheter or a catheter for the central venous pressure measurement was inserted into the vein through the cannula. All of these procedures were observed on the oscilloscope. Ultrasound-guided IJV catheterization was performed 160 times on unselected patients by all members of our anesthetic department. There was no failure in achieving satisfactory venous puncture and catheterization. During the two-year trial, we have not had any complications with this technique. The advantage of this technique was safe and easy puncture of the IJV in patients with bleeding tendency or cervical hematoma due to inadvertent carotid puncture oc-

curing with conventional techniques. The disadvantages were the cost of the equipment and the probe being too large for a short neck or a child.

AKITOMO YONEI, M.D.

TADAHIKO NONOUE, M.D.

ATSUO SARI, M.D.

Director

Department of Anesthesia
Kurashiki Central Hospital
1-1-1 Miwa Kurashiki
Okayama, Japan 710

REFERENCES

1. Roa TLK, Wong AY, Salem MR: A new approach to percutaneous catheterization of the internal jugular vein. *ANESTHESIOLOGY* 46:362-364, 1977
2. Ullman JI, Stoelting RK: Internal jugular vein location with the ultrasound Doppler blood flow detector. *Anesth Analg* 57:118, 1978
3. Bazaral M, Harlan S: Ultrasonographic anatomy of the internal jugular vein relevant to percutaneous cannulation. *Crit Care Med* 9:307-310, 1981

(Accepted for publication December 31, 1985.)

Cricoid Pressure, Awake Intubation, or Both?

To the Editor:—The experiment by Salem *et al.*¹ attempted to resolve the question of the desirability of leaving a nasogastric tube in place during rapid-sequence induction. Although cricoid pressure was found to be highly effective in occluding the upper esophagus in six fresh cadavers, for several reasons these findings may not allow one the degree of certainty with which Salem recommends this course of action in the clinical setting. First, the force of cricoid compression may well have been much greater than that used clinically, and reduction in the force of compression to meet the needs of intubation may result in reflux. Second, cricoid compression has been known to distort and/or laterally displace the glottis, and extensive anterior-posterior compression of the cricoid may also result in compromise of the narrowest lumen to be traversed with intubation. Third, no attempt was made to intubate the cadaver, and the antioclusive effects of

anterior displacement forces of laryngoscopy require evaluation.

The advantage of an 18-Fr nasogastric tube as a "blow off" valve is questionable because induction is generally delayed until suction of gastric contents becomes non-productive. Slow withdrawal of the nasogastric tube allows aspiration of esophageal and pharyngeal contents as well as subsequent evaluation of the patency of the tube itself, which frequently becomes occluded with particulate matter not found in colored saline. This slow withdrawal of the nasogastric tube may be particularly useful in patients with hiatal hernia or achalasia, where the danger of aspiration arises from material proximal to the stomach. Rare entities such as megaesophagus could preclude efficacy of cricoid compression, the upper esophagus becoming much wider than the cricoid. With Zenker's diverticulum, aspiration secondary to cricoid compression