

## Polymorphous Ventricular Tachycardia during Coronary Artery Bypass Surgery

MANUEL WEISKOPF, M.D.,\* STANLEY W. STEAD, M.D.†

Polymorphous ventricular tachycardia (PVT), also known as Torsade de Pointes (TdP), is an unusual ventricular dysrhythmia whose features have been well described.<sup>1-3,‡</sup> We present the first reported case of this dysrhythmia occurring during a coronary artery revascularization operation.

## REPORT OF A CASE

A 64-yr-old man was admitted for coronary artery bypass surgery. The patient was known to have hypertension with chronic obstructive pulmonary disease and had had an uncomplicated myocardial infarction (MI) 15 yr prior to admission. Two years later, the patient noted the onset of exertional angina for which he was treated medically over the next ten years. Eighteen months prior to admission, premature ventricular contractions (PVCs) were noted, and oral procainamide was started. Cardiac catheterization the same year revealed triple-vessel coronary artery disease. Surgery was advised but was refused by the patient. Over the next 12 months, the patient developed four-pillow orthopnea and angina at rest and was hospitalized twice for an irregular cardiac rhythm. Following this, the patient consented to have coronary revascularization performed. His medical history was otherwise unremarkable. Preoperative medications included procainamide 500 mg every 6 h and isosorbide dinitrate 50 mg every 4 h. Physical examination revealed bilateral carotid bruits, with the right greater than the left, and an S<sub>4</sub> gallop. His ECG showed a sinus rhythm at 60 beats/min, an intraventricular conduction delay, signs of an old inferior-wall MI, and a borderline increased QT interval. Carotid angiography showed a 50% stenosis of both external carotid arteries and shallow plaques with ulcers of both internal carotid arteries. Preoperative laboratory studies were remarkable only for a creatinine of 2.0 mg% and blood urea nitrogen of 28 mg%. Chest roentgenogram was normal. Hemodynamic measurements revealed a cardiac index (CI) of 2.5 l · min<sup>-1</sup> · min<sup>-2</sup>, arterial blood pressure of 125/72 mmHg, a systemic vascular resistance (SVR) of 1618 dyne · sec<sup>-1</sup> · cm<sup>-5</sup>, a normal right atrial filling pressure, and a pulmonary capillary wedge pressure (PCWP) of 6 mmHg.

Cardiac medications were continued up to the time of surgery. After premedication with lorazepam 3 mg im, anesthesia was induced with intravenous (iv) fentanyl, and muscle relaxation was provided with pancuronium bromide. A continuous iv infusion of nitroglycerin at 0.5 μg · kg<sup>-1</sup> · min<sup>-1</sup> was maintained until the institution of bypass. Cardioplegia followed aortic cross clamp, and surgery proceeded unevent-

fully. Four aortocoronary saphenous vein grafts and a small posterior left ventricular aneurysmectomy were performed.

Postbypass, the patient had poor cardiac function manifested by low cardiac output and right ventricular dysfunction. An intraaortic counter pulsation balloon (IACPB) was passed *via* the right femoral artery and inflated at a 1:1 ratio. The patient was then successfully weaned off cardiopulmonary bypass with infusions of dopamine, (5 μg · kg<sup>-1</sup> · min<sup>-1</sup>) sodium nitroprusside (0.5 μg · kg<sup>-1</sup> · min<sup>-1</sup>) and nitroglycerin (0.5 μg · kg<sup>-1</sup> · min<sup>-1</sup>). A few PVCs were noted shortly postbypass. Two 75-mg iv bolus doses of lidocaine were given, followed by an infusion of lidocaine at 2 mg/min. CI was 2.25 l · min<sup>-1</sup> · min<sup>-2</sup>, arterial pressure 120/65 mmHg, SVR 1320 dyne · sec<sup>-1</sup> · cm<sup>-5</sup>, and a PCWP of 12 mmHg.

Approximately 90 min postbypass, the patient experienced the onset of premature atrial contractions and several runs of supraventricular tachycardia at 140-150 beats/min. The ECG showed a normal QT interval (0.32 s, QTc = 0.40). Verapamil 5 mg iv was given without effect. Serum electrolytes drawn at this time were within normal limits and revealed a potassium of 3.6 mEq/l. The supraventricular tachycardia degenerated into ventricular tachycardia of the TdP type (fig. 1). The patient was successfully DC-cardioverted on the second attempt with 20 joules directly to the myocardium. The lidocaine infusion was stopped, and a loading dose of 750 mg iv procainamide was given, followed by a continuous infusion at 2 mg/min. The remainder of the intraoperative course was uneventful.

The patient required both procainamide and lidocaine to control PVCs in the surgical intensive care unit postoperatively. The patient was successfully weaned off the IACPB on the second postoperative day. He was discharged in good condition on oral procainamide without any further dysrhythmias.

## DISCUSSION

TdP, a polymorphous type of ventricular tachycardia, was first described in 1966 by Dessertenne.<sup>1</sup> Since the original description, a number of reports have appeared in the literature reviewing diagnostic and electrophysiologic features.<sup>2-6,‡</sup> The features that are diagnostic for TdP have remained controversial, although most authorities feel that the following characteristics must be present.<sup>7</sup>

1. Phasic variation over 5-20 beats in the electrical polarity of the QRS complex, termed polymorphous ventricular tachycardia.
2. Frequent initiation by a premature ventricular depolarization occurring late in diastole on a prolonged T or U wave.
3. Common occurrence of spontaneous termination.
4. Occasional degeneration into ventricular fibrillation.
5. Heart rate greater than 150 beats/min (and often greater than 200 beats/min) with varying R-R intervals.

\* Adjunct Assistant Professor.

† Assistant Professor.

Received from the Department of Anesthesiology, UCLA School of Medicine, Los Angeles, California 90024.

Address reprint requests to Dr. Stead.

Key words: Surgery: cardiac. Heart: dysrhythmia, polymorphous ventricular tachycardia.

‡ Fontaine GH, Frank R, Welti JJ, Grosogoeat Y: Electrophysiology of Torsade de Pointes. Meere C (ed) Proceedings of the 6th World Symposium of Cardiac Pacing. Montreal Chapter 6-3, 1979.

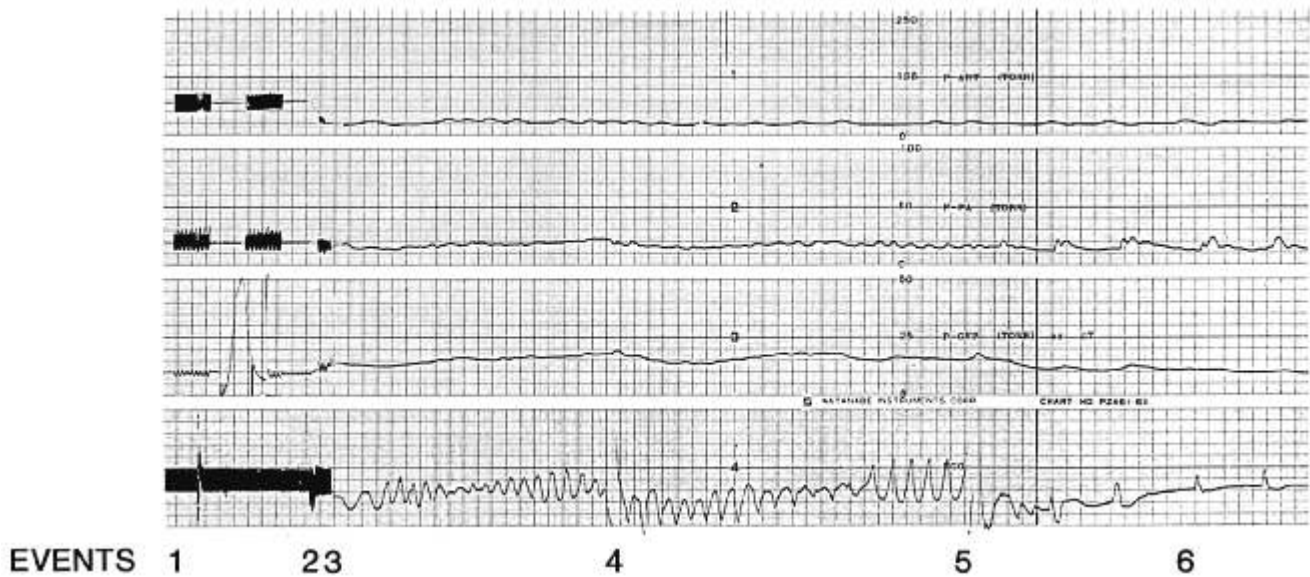


FIG. 1. Recorder channels labeled 1-4 correspond to arterial pressure, pulmonary artery pressure, right atrial pressure, and ECG. At point (1) the chart speed was  $25 \text{ mm} \cdot \text{min}^{-1}$ . Thirty seconds of pulsatile pressure was alternated with 30 s of mean each min. Point (2) shows the onset of polymorphous ventricular tachycardia (PVT) with a drop in arterial and pulmonary arterial pressures. The chart speed was increased to  $25 \text{ mm} \cdot \text{sec}^{-1}$  at point (3). The recording shows the continuing PVT dysrhythmia. At point (4), the patient was defibrillated with internal paddles at 20 joules. The PVT continued. The patient was successfully defibrillated with a second application of 20 joules at point (5). Recovery of electrical cardiac activity began, with a gradual increase in arterial pressures and decreased central venous pressure during the period marked (6). ECG demonstrates sinus bradycardia with first degree AV block. The patient stabilized rapidly.

Recognition of this dysrhythmia, its causes, and recognition of management are important because of its clinical behavior and unusual response to conventional dysrhythmia treatment.

One of the more controversial aspects of the TdP syndrome is the requirement for the presence of a prolonged QT and QTc interval for diagnosis.<sup>7</sup> TdP has been described in association with all of the QT prolongation syndromes, both congenital (Jervell and Lange-Nielsen Syndrome, Romano-Ward Syndrome), and acquired (electrolyte abnormalities, drug-related, and intrinsic heart disease). Some investigators have emphasized the primary role of abnormal repolarization to distinguish TdP from other ventricular arrhythmias, while others have labelled a PVT as TdP in patients with a predominantly normal QT interval.<sup>7-9</sup> This distinction is significant with regard to management because the treatment of PVT in the presence of normal *versus* prolonged QT intervals is quite different.

In patients on class I antidysrhythmic agents (procainamide, quinidine), a prolongation of the QT interval can occur, thereby increasing the susceptibility of the patient to TdP. Decreasing the dose of the drug or discontinuing the drug entirely until the QT interval returns to normal is the appropriate treatment.<sup>2,7</sup> While defibrillation is essential for prolonged episodes, electrical conversion alone is useless.<sup>2,11-13</sup> Antidysrhythmic drugs also have no role in acute management because agents that prolong the

QT interval, such as quinidine and procainamide, may aggravate the arrhythmia and are absolutely contraindicated.<sup>2,8</sup> An isoproterenol infusion is generally recommended in order to obtain an emergency control of the dysrhythmia.<sup>2,3,10,11</sup> The definitive treatment is overdrive atrial pacing, unless the presence of atrioventricular block requires ventricular pacing.<sup>2,3,10</sup> Atrial pacing can be discontinued when the predisposing cause has been corrected and the QT interval has returned to normal.<sup>2</sup>

There are a number of reports in the literature of PVT occurring with a normal QT interval. This dysrhythmia was considered to be TdP. In 1973, Slama *et al.*<sup>10</sup> described a patient with a polymorphous type of ventricular tachycardia (TdP) who responded to procainamide given precisely because the QT interval was normal. Two similar cases, both responding to quinidine, were described in the same report. In 1982, Soffer *et al.* described a patient with a polymorphous type of ventricular tachycardia (TdP) that developed in the setting of acute myocardial ischemia with a normal QT interval. Procainamide therapy was successful in preventing recurrence. Moore *et al.*<sup>14</sup> induced a PVT, morphologically similar to TdP, in dogs with chronic MI and normal QT intervals. All responded to procainamide. Thus, PVT occurring in the setting of the normal QT interval can often be successfully treated with class I antidysrhythmic agents.<sup>14</sup>

We conclude that this case illustrates the important differences to be made in PVTs. PVT can be associated

with either a prolonged or normal QT interval, the occurrence with a normal QT interval being more unusual. PVT that occurs in the setting of a prolonged QT interval is more commonly referred to as TdP. Although this distinction is controversial, it does have implications in management. Those PVTs with prolonged QT intervals should not be treated with class I antidysrhythmic agents, but rather with discontinuation of these drugs. Prolonged episodes may be treated with electrical conversion plus subsequent isoproterenol infusion or overdrive atrial pacing. On the other hand, those cases with a normal QT interval respond well to treatment with a class I dysrhythmic agent.

## REFERENCES

- Dessertenne F: La-tachycardia Ventriculaire a Deux Foyers Opposes Variables. *Arch Mal Coeur* 59:263-272, 1966
- Smith WM, Gallagher JJ: Les Torsade de Pointes: An unusual ventricular arrhythmia. *Annals Int Med* 93:578-581, 1980
- Krikler DM, Curry P: Torsade de Pointes: An atypical ventricular tachycardia. *Br Heart J* 38:117-120, 1976
- Kossmann CE: Torsade de Pointes: An addition to the nosography of ventricular tachycardia. *Am J Card* 42:1054-1056, 1978
- Sciarovsky S, Strasberg B, Lewin RF, Agmun J: Polymorphous ventricular tachycardia: Clinical features and treatment. *Am J Card* 44:339-343, 1979
- Schwartz PJ, Periti M, Mallani A: The long QT syndrome. *Am Heart J* 89:378, 1975
- Soffer J, Dreifus LS, Michelson EL: Polymorphous ventricular tachycardia associated with normal and long QT intervals. *Am J Card* 49:2021-2028, 1982
- Horowitz LN, Greenspan AM, Spielman SR, Josephson ME: Torsade de Pointes: Electrophysiologic Studies in patients without transient pharmacologic or metabolic abnormalities. *Circ* 63:1120-1128, 1981
- Zilcher H, Glogar D, Kaindl F: Torsade de Pointes: Occurrence in myocardial ischemia as a separate entity. Multifocal ventricular tachycardia or not? *Eur Heart J* 1:63-69, 1980
- Slama R, Coumel PH, Motte G, Gourgon R, Waynberger M, Touche S: Tachycardies ventriculaires et Torsade de Pointes: Frontieres morphologiques entre les dysrhythmies ventriculaires. *Arch Mal Coeur* 66:1401-1411, 1973
- Cokkinos DV, Mallios C, Philiis N, Vorides EM: Torsade de Pointes: A distinct entity of ventricular arrhythmia? *Acta Cardiol (Brux)* 33:167-184, 1978
- Miller DS, Blount AW: Quinidine induced recurrent ventricular fibrillation (quinidine syncope) treated with transvenous pacemaker. *South Med J* 64:597-601, 1971
- Herman DF, Helwise J: Suppression of ventricular arrhythmias by transvenous intracardiac pacing. *JAMA* 195:172-174, 1966
- Moore EN, Spear JF, Michelson EL: Electrophysiological studies of sustained ventricular tachyarrhythmias initiated in a canine model of infarction, Cardiac Arrhythmias—A Decade of Progress. Edited by Harrison DC. Boston, GK Hall, 1981, pp 407-418

Anesthesiology  
64:394-398, 1986

## Midazolam Infusion for Sedation in the Intensive Care Unit: Effect on Adrenal Function

J. M. SHAPIRO, M.D.,\* L. M. WESTPHAL, B.A.,† P. F. WHITE, PH.D., M.D.,‡  
R. N. SLADEN, M.B., M.R.C.P. (U.K.), F.R.C.P.(C.),§ M. H. ROSENTHAL, M.D.¶

Benzodiazepines, opioids, and butyrophenones are frequently used in the intensive-care setting to treat agitation that, if uncontrolled, might prove hazardous to the critically ill patient. Problems related to agitation include cardiorespiratory instability, injuries to patients and hos-

pital personnel, inability to cooperate with nursing care, failure to maintain optimal positioning in bed, and disruption of life-sustaining tubes and catheters. Thus, the ability to provide safe, controllable, and reversible sedation can be important in the care of critically ill patients.

The multitude of drugs used to control agitation attests to the lack of an ideal drug or combination of drugs.<sup>1</sup> The most popular benzodiazepines, diazepam and lorazepam, have a slow onset and long duration of action, which may make titration difficult in the agitated patient. Morphine sulfate, the prototype opiate analgesic, can produce dose-related respiratory depression, hemodynamic instability, and inhibition of gastrointestinal motility. Haloperidol, an antipsychotic tranquilizer with sedative and antiemetic properties, can produce dysphoria and hypotension. The sedative-hypnotic etomidate can provide effective sedation in both mechanically ventilated<sup>2</sup> and spontaneously breathing patients.<sup>3</sup> However, critically ill patients receiving prolonged sedation with etomidate

\* Fellow, Critical Care Medicine.

† Medical Student Research Assistant.

‡ Assistant Professor of Anesthesia; Chief, Outpatient Anesthesia Service.

§ Associate Professor of Anesthesia; Associate Medical Director, Intensive Care.

¶ Associate Professor of Anesthesia, Medicine, and Surgery; Medical Director, Intensive Care Unit.

Received from the Stanford School of Medicine, Stanford, California. Accepted for publication October 17, 1985.

Address reprint requests to Dr. White: Department of Anesthesia, Room S-268C, Stanford School of Medicine, 300 Pasteur Drive, Stanford, California 94305.

Key words: Anesthetics, intravenous: midazolam. Anesthetic technique: continuous infusion. Intensive care.