

the diaphragm and hence will reflect quite closely the top of the cylinder of abdominal contents that lies below. In essence, the abdomen could become longer, and less wide, after induction of anesthesia.

Mead and Loring² show that these relative volume changes can be calculated, and they indicate that such a change in shape can take place with no change in the length of the diaphragm. Their analysis is more complex than that of Hedenstierna *et al.*,¹ whose calculation of the volume of abdominal contents is misleadingly simple and could be in considerable error. For example, the most cranial section across the abdomen was only 14 cm above the lower margin of L4, which is about the lower margin of T12. Since at functional residual capacity in the supine subject the dome of the diaphragm may extend up to about T6, this uppermost section will not accurately reflect the volume of the abdominal container up to the dome of the diaphragm. Analysis of the results of this

study is far from simple, and the authors should consider other muscles as well as the diaphragm in their analysis of the shape changes they describe.

G. B. DRUMMOND, F.F.A.R.C.S.
M. R. LOGAN, F.F.A.R.C.S.
*Department of Anaesthetics
Edinburgh Royal Infirmary
Edinburgh Scotland EH3 9YW*

REFERENCES

1. Hedenstierna G, Strandberg A, Brismar B, Lundquist H, Svensson L, Tokics L: Functional residual capacity, thoracoabdominal dimensions, and central blood volume during general anesthesia with muscle paralysis and mechanical ventilation. *ANESTHESIOLOGY* 62:247-254, 1985
2. Mead J, Loring SH: Analysis of volume displacement and length changes of the diaphragm during breathing. *J Appl Physiol* 53:750-756, 1982

(Accepted for publication July 22, 1985.)

Anesthesiology
63:730, 1985

In reply:—Dr. Drummond indicates the difficulty of determining the change in thoracic and abdominal volume caused by a change in the position and shape of the diaphragm. We have also stressed that “no detailed analysis of the configuration of the diaphragm was undertaken in the present study; this would have required additional transverse projections through the dome which was not possible for radiation dose reasons.” However, our method of calculating the thoracic and abdominal volumes (abdominal volume: transverse area times height of each abdominal segment, plus the maximum shift of the diaphragm multiplied by a factor of 0.75 times the transverse area at the level of the lowermost thoracic projection) turned out to be fairly accurate in various model analyses.

This calculation will include the abdominal content within the rib cage; thus we do not agree with Dr. Drummond that we have failed to consider it. The schematic drawing in figure 2, with no detailed or exact configuration of the diaphragm, should not be used for criticism of our analysis of the effects of a shift in the position of the diaphragm.

GÖRAN HEDENSTIERNA
*Department of Clinical Physiology
Huddinge University Hospital
S-141 86 Huddinge
Sweden*

(Accepted for publication July 22, 1985.)

Anesthesiology
63:730-731, 1985

Histamine H1 Antagonist Alone Attenuates *d*-Tubocurarine-induced Hypotension

To the Editor:—Morphine and *d*-tubocurarine (*d*Tc) have been widely used for anesthesia but are known to release histamine, which induces hypotension. Philbin *et al.* have shown that hypotension induced by morphine infusion was completely prevented by pretreatment with H1 and H2 antagonists when used in combination but not alone.¹ On the other hand, it also has been suggested that the cardiovascular action of histamine is altered by the method of the drug administration, *i.e.*, infusion or

injection.² We examined the efficiency of H1 and H2 antagonists, singly or in combination, in preventing hypotension induced by a bolus injection of *d*Tc.

Twenty-four patients (ASA I or II), of either sex, ranging in age from 18 to 60 yr, and who were undergoing peripheral orthopedic, gynecologic, or abdominal surgery, were studied. At the time of the study, the Human Ethical Committee for Research had not been established in our institution, however, after full explanation of the study,

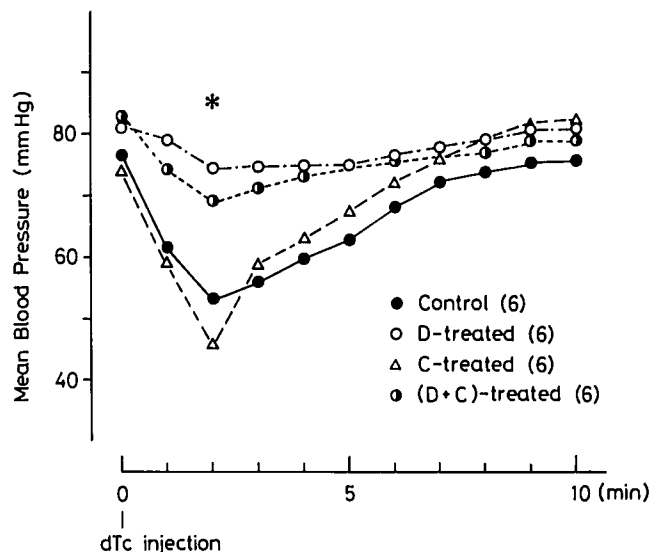


FIG. 1. Modifications by diphenhydramine and cimetidine, singly or in combination, of decrease in mean blood pressure induced by *d*Tc injection. Each point represents the mean blood pressure. Data were analyzed using one-way analysis of variance and Newman-Keuls multiple range test. D = diphenhydramine; C = cimetidine. Asterisk indicates that the values obtained following treatment with diphenhydramine alone or in combination with cimetidine were significantly greater than those of control or with cimetidine alone ($P < 0.05$). Figures in parentheses indicate the number of patients studied.

informed consent was obtained from each patient by the chairman of the Department of Anesthesiology, Professor Kenjiro Mori. The patients were divided into four groups of six patients each. All patients were premedicated with 0.5 mg im atropine. Direct blood pressure was recorded through a cannulated radial artery. Anesthesia was induced with fentanyl (3 μ g/kg), thiopental (6 mg/kg), and N₂O/O₂ (1:1), and ventilation was assisted using a face mask to maintain end-tidal CO₂ at approximately 30 mmHg throughout the study. Five minutes after thiopental administration, diphenhydramine (1 mg/kg) and

cimetidine (4 mg/kg) were given, singly or in combination in three groups; the control group received no antagonist. One minute after the administration of the histamine antagonists, *d*Tc at a dose of 0.6 mg/kg was given as a bolus injection.

Results are shown in figure 1. In the control group, the administration of *d*Tc produced a rapid decrease in blood pressure, reaching the maximum decrease within 2 min. Thereafter, the blood pressure gradually returned to the preadministration level. The decrease in blood pressure 2 min following *d*Tc injection was significantly attenuated by treatment with diphenhydramine alone or in combination with cimetidine but not with cimetidine alone.

Our findings indicate that treatment with H₁ antagonist alone is sufficient to prevent the hypotension induced by the bolus injection of *d*Tc. This is in contrast to the response observed with infusion of morphine.

YOSHIO HATANO, M.D.
KAZUHIKO FUKUDA, M.D.
TOSHIYUKI ARAI, M.D.
SUNAO TAMAI, M.D.
TOKUYA HARIOKA, M.D.
Department of Anesthesiology
Kyoto University Hospital
Sakyo-ku, Kyoto 606
Japan

REFERENCES

1. Philbin DM, Moss J, Akins CW, Rosow CE, Kono K, Schneider RC, Verlee TR, Savarese JJ: The use of H₁ and H₂ antagonists with morphine anesthesia: A double-blind study. *ANESTHESIOLOGY* 55:292-296, 1981
2. Levi R, Owen DAA, Trzeciakowski J: Actions of histamine on heart and vasculature, *Pharmacology of Histamine Receptors*. Edited by Ganellin CR, Parsons ME. Bristol, Wright PSG, 1982, pp 236-297

(Accepted for publication July 23, 1985.)

Unexpected Wedge Pressure (at less than 35 cm) May Be Artifactual

To the Editor:—I read with interest the letter by Badenhurst¹ concerning proximal port dysfunction in pulmonary artery catheters inserted from the right subclavian vein. In several patients wedge position was obtained at a catheter insertion distance of less than 35 cm. This interfered with use of the proximal infusion port and therefore cardiac output determinations. The patients are all described as adult females of "average build." In our intensive care unit we have encountered a similar problem

but with a different interpretation. In several cases catheters advanced from a right subclavian position would develop a dampened wave form with the appearance of a wedged tracing, at an insertion length of 30-40 cm. We frequently use fluoroscopy for catheter placement and could see that this tracing corresponded with advancement of the catheter tip into the apex of the right ventricle. It should be noted that the natural curvature of the catheter itself has a tendency to direct the tip into this