

Anesthesiology
63:205-207, 1985

Air Embolism in the Achondroplastic Dwarf

JEFFREY KATZ, M.B., CH.B.,* AND JAMES F. MAYHEW, M.D.†

Achondroplastic dwarfs frequently undergo suboccipital craniotomy for treatment of spinal stenosis in either the prone or the sitting position. While the sitting position is associated with the constant threat of venous air embolism, the prone position is uncomfortable for some surgeons and is associated with increased blood loss. Further, the prone position does not provide absolute protection from the entrainment of venous air.¹ We report on the incidence of air embolism in 18 achondroplastic dwarfs who had suboccipital craniotomies, six in the prone position and 12 in the sitting position.

METHODS

In the prone group, patients' ages ranged from 7 months to 13 years, while the sitting group had patients aged 4 months to 34 years. All patients had continuous electrocardiograph (ECG), blood pressure (BP), temperature, heart sounds, and inspired oxygen concentration monitoring. Special monitoring included an arterial catheter for BP and arterial blood gas analysis, a capnograph, and, in addition, those patients in the sitting position had right atrial catheters and precordial Doppler ultrasound units placed. Patients with iv catheters in place received thiopental for induction, while children younger than 8 years breathed halothane. Intubation of the trachea was facilitated with pancuronium iv. Maintenance of anesthesia was with isoflurane or halothane and 50% nitrous oxide in oxygen. Air embolism was diagnosed either by changes on the Doppler as judged by one of the authors or by sudden decreases in the end-expired carbon dioxide concentration. Of the 12 patients, nine had right atrial catheters inserted via the

right internal jugular vein, two through subclavian veins, and one via the right femoral vein.

Blood loss was estimated by adding the volume of blood in the suction traps to the volume in all sponges (visual assessment) removed from the operative field.

RESULTS

In one patient, right atrial catheterization was unsuccessful and the sitting position was abandoned for fear of venous air embolism. Intraoperatively, in the prone position this patient had a sudden decrease in the end-expired CO₂ develop (fig. 1), followed by severe hypotension and bradycardia, which responded to 100% oxygen, iv administered crystalloids, and 1 mg iv ephedrine. Hypotension was thought to be caused by an air embolism. No catheter was available for air aspiration.

In the sitting group, seven of the 12 patients had changes on the Doppler consistent with iv air embolism. The end-expired CO₂ decreased acutely in all of the patients by between 5 and 20 mmHg (fig. 2). In seven, air bubbles were aspirated through the catheters. Volumes varied from 2 to 12 ml of gas. Only one of these patients became significantly hypotensive (systolic pressure < 40 mmHg) and responded to 100% oxygen and 0.5 mg ephedrine iv. In one patient no air could be aspirated. Nitrous oxide was discontinued in all patients. The overall incidence of air embolism in this group was 60%. No murmurs or dysrhythmias were detected.

In the sitting group, the estimated blood loss (EBL) averaged 18 ml/kg, whereas this was considerably higher (38 ml/kg) in the prone group.

DISCUSSION

The incidence of air embolism in children undergoing this procedure in the sitting position has been reported to be 33%.² In our group of dwarfs having the same procedure, the incidence of air embolism was 60% if sitting and 17% in the prone group.

The incidence of hypotension in the sitting group with air embolism was 1 of 7 (14%), and 1 of 1 (100%) in the prone patient. This low incidence possibly reflects a smaller volume of air entrainment in our cases. However, when hypotension occurred it was rapid in onset and severe enough to immediately threaten the life of the patient. In both cases it responded to 100% oxygen and iv crystalloids and ephedrine. In the sitting patient,

* Assistant Professor of Anesthesiology, The University of Texas Medical School.

† Associate Professor of Anesthesiology, Arkansas Children's Hospital.

Received from the Department of Anesthesiology, The University of Texas Medical School, Houston, Texas, and the Department of Anesthesiology, Arkansas Children's Hospital, Little Rock, Arkansas. Accepted for publication March 8, 1985.

Address reprint requests to Dr. Katz: Department of Anesthesiology, The University of Texas Health Center at Houston, 6431 Fannin, 5.020 MSMB, Houston, Texas 77030.

Key words: Position. Embolism: air. Surgery: neurosurgical; achondroplastic dwarf.

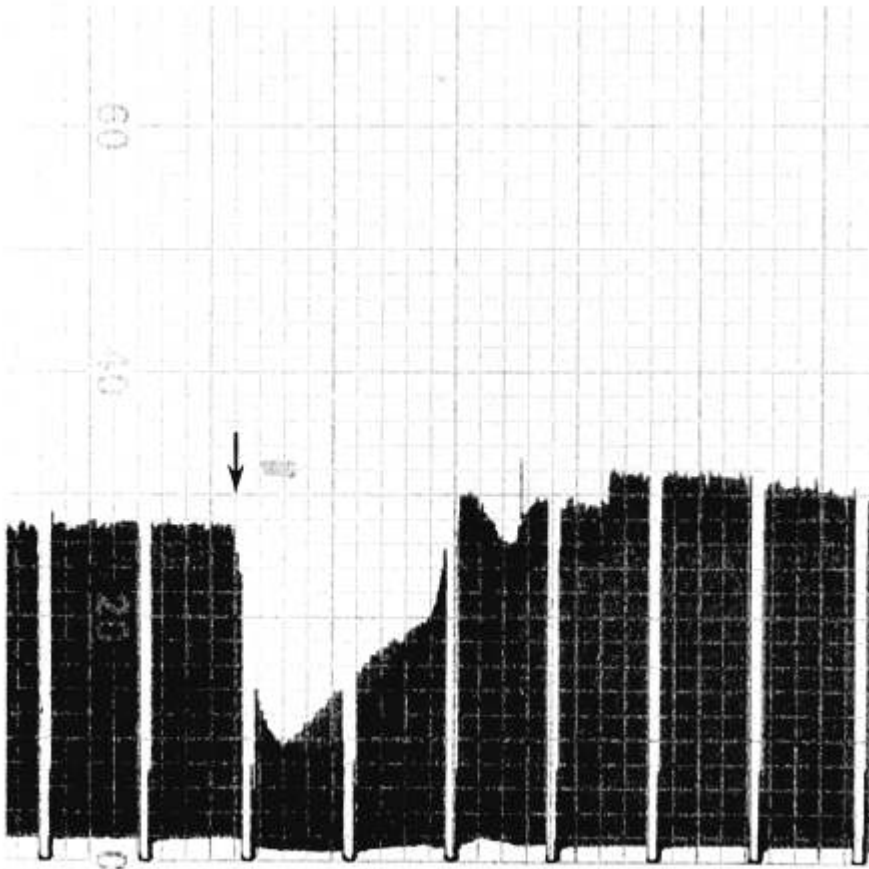


FIG. 1. Continuous capnograph readout showing sudden decrease in end-expired carbon dioxide. The arrow indicates onset of turbulence on the Doppler.

air bubbles (12 ml) were aspirated, whereas the prone patient had no atrial catheter. No positive end-expiratory pressure (PEEP) was applied to the airways of these patients because of the danger of facilitating the movement of gas bubbles from the right to the left atrium through an occult patent foramen ovale.⁴

Air bubbles were aspirated from the right atrial catheters in 7 of 7 patients who had air detected by the Doppler (100%). This success is not surprising, as the volume of bubbles is likely to be larger in relation to the volume of the right atrium than in adults and more likely to be in contact with the aspiration port of a correctly placed catheter. The largest volume of air aspirated (12 ml) was in the patient who also had hypotension.

In view of the high incidence of air embolism in these patients, the internal jugular vein (IJV) was catheterized, if necessary, to secure a right atrial catheter. Consequently, the rate of successful catheterization is higher than that in previous reports^{2,3} in which peripheral vein attempts yielded a success rate of about 50%. In only one case was it necessary to abandon attempts at catheterization and this was the patient who possibly had an air embolus in the prone position. Achondroplastic

dwarfs are especially challenging when it comes to inserting invasive monitors. Not only are they smaller and shorter than normal patients, but they also tend to have excess amounts of skin and subcutaneous tissue, making location of landmarks extremely difficult. We have found the posterior approach to the IJV especially helpful in these patients.

Many neurosurgeons now prefer to avoid the sitting position because of the constant threat of entrainment of room air into the venous system. However, the surgeon in these cases is convinced that the advantages, *i.e.*, less blood loss, better exposure and less discomfort, outweigh the disadvantages, *i.e.*, air embolism and hypotension, of the sitting position. The surgeon's assessment of the difference in blood loss is borne out by the increased loss in the prone position. This is probably related to favorable venous drainage in the sitting position. Yet, the prone or lateral positions do not guarantee freedom from the risk of air embolism.¹

It is not clear whether the sudden decrease in end-tidal carbon dioxide in the prone patient was related to an air embolus or a sudden change in ventilation/perfusion relationship because of hypotension. Blood loss was minimal, and no other cause for acute hypoten-

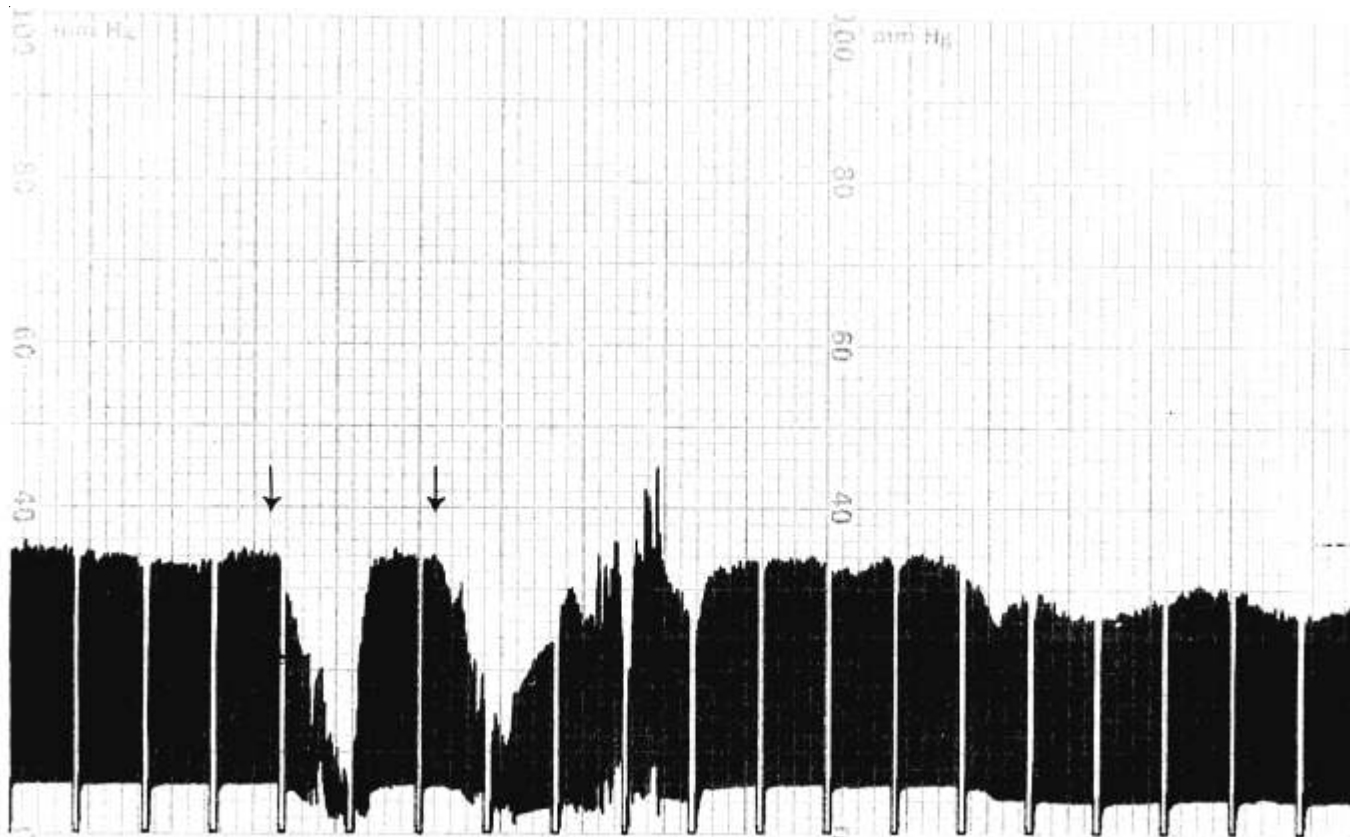


FIG. 2. Continuous capnograph readout showing repeated air emboli and their effect on the end-expired CO₂. The arrows indicate onset of turbulence on the Doppler.

sion could be found. Because no catheter had been placed, confirmation by aspiration of air was impossible.

Although we report a high incidence of air embolism, these patients all did extremely well postoperatively with no complications that could be related to the incidents of air entrainment. No patients had evidence of pulmonary infiltration on roentgenogram in the postoperative period. This therapeutic success can be related to early detection, high rate of successful aspiration of bubbles, and relatively small volumes of air entrainment.

Despite the fact that this is a relatively small series of patients, it represents a special group (achondroplastic dwarfs) in whom an alarmingly high incidence of air embolism was seen. In view of the increased frequency with which these procedures are being undertaken, it seems appropriate to report our experience, which is different from that in similar studies in nonachondroplastic children. Further, previous studies have concluded

that right atrial catheterization is not essential in children having sitting suboccipital craniotomies.²

Our experience indicates that in dwarfs serious consideration should be given to abandoning the sitting position and that if the sitting position is selected right atrial catheterization is essential.

REFERENCES

1. Albin MS, Carroll RG, Maroon JC: Clinical considerations concerning detection of venous air embolism. *Neurosurgery* 3:380-384, 1978
2. Cucchiara RF, Bowers B: Air embolism in children undergoing suboccipital craniotomy. *ANESTHESIOLOGY* 57:338-339, 1982
3. Klein MD, Rudd M: Successful central venous catheter placement from peripheral subcutaneous veins in children. *ANESTHESIOLOGY* 52:447-448, 1980
4. Perkins NAK, Bedford RF: Hemodynamic consequences of PEEP in seated neurological patients—implications for paradoxical air embolism. *Anesth Analg* 63:429-432, 1984