

Laryngeal Injury in a Dog Model of Prolonged Endotracheal Intubation

Michael J. Bishop, M.D.,* Arlis J. Hibbard, M.D.,† B. Raymond Fink, M.D.,‡
Arthur M. Vogel, M.D., Ph.D.,§ Ernest A. Weymuller, Jr., M.D.¶

Using a dog model of prolonged translaryngeal intubation, the authors studied laryngeal injury. Segments of 10.7 mm diameter endotracheal tube were sutured in place in the larynges of anesthetized animals, and the animals were allowed to awaken and the tubes left in place for periods of 24 h to 84 days in a total of 13 dogs. Each animal's larynx was studied endoscopically at weekly intervals and at the time of death. Both endoscopic and postmortem examination revealed erythematous laryngeal mucosa at 24 h and severe mucosal ulceration by 1 week. Microscopic examination revealed mucosal inflammation at 24 h with loss of mucosal architecture by 1 week. In several animals intubated 1 week or longer, inflammatory infiltrates were present in the arytenoid cartilage. While damage was generally severe by 1 week, it did not tend to become more severe after that time. Between week 1 and week 12, there was no significant correlation of the severity of laryngeal injury with the duration of endotracheal intubation. The results suggest that duration alone may not be a factor in laryngeal injury after the first week of intubation. (Key words: Intubation, endotracheal; complications. Larynx: arytenoid cartilage.)

DAMAGE TO THE LARYNX occurs routinely in patients whose tracheas remain intubated for a prolonged period.^{1,2} Whether or not the extent of the laryngeal injury correlates with the duration of intubation remains controversial.²⁻⁴ Knowledge of the role of the duration of intubation in the injury would be useful to clinicians in determining when to replace the translaryngeal endotracheal tube with a tracheotomy. Because of the multisystem disease often present in humans requiring artificial airways for a prolonged period, studying the isolated effect of a single factor, duration, has been difficult. Consequently we used a dog model of chronic intubation to study the effects on gross and microscopic

histology of translaryngeal intubation for periods of intubation ranging from 1 to 84 days.

Materials and Methods

We placed 10-cm lengths of polyvinyl chloride endotracheal tube into the larynx of each of 14 mongrel dogs (weight range of 20-30 kg). The intubations were carried out under sedation with 4 mg/kg thiamylal and paralysis with a succinylcholine infusion. The larynx and trachea were anesthetized with a topical spray of 2% lidocaine via a transtracheal 16-gauge catheter. The catheter was used to ventilate the animal with pure oxygen via a high-pressure injector. This left the larynx unobstructed for observation and placement of the tubes.

Each dog's larynx was inspected to ensure that no preexisting disease was present. At the time of this inspection, and at all subsequent direct laryngoscopies, the larynx was photographed with a Storz® camera using a zero degree Hopkin's rod (Karl Storz, Tuttlingen, West Germany) so that photographs could be used for comparison of the appearance at different times. An uncuffed segment of endotracheal tube (inner diameter 8.0 mm, outer diameter 10.7 mm) was then placed in the larynx so that the upper end was cephalad to the false cord, midway up the epiglottis. The 8.0-mm tubes were chosen based on our laboratory experience that this size produced lesions in 20-30 kg dogs that were similar to the vocal cord lesions seen in humans. The distal end of the tube segment extended to approximately the third tracheal ring. The segment was fixed in place with four 3.5", 18-gauge spinal needles passed percutaneously through the trachea and extending out the other side of the neck. Placement was monitored endoscopically. Tevdek 2-0 suture then was passed through the needles after removing the stylets and the ends tied after removing the needles so that each tube segment was tethered by two loops of suture. A neck dressing with a plastic shield was placed and the dog allowed to awaken.

On postoperative days 1, 7, 14 and every 2 weeks thereafter until death, the vocal cords of each dog were examined and photographed under thiamylal sedation.

Dogs were killed at 1 day (n = 3), 2 weeks (n = 2), 4 weeks (n = 4), 6 weeks (n = 2), and 12 weeks (n = 2)

* Associate Professor of Anesthesiology and Medicine (Adjunct). Dr. Bishop is a Parker B. Francis Investigator in Anesthesiology of the Puritan-Bennett Foundation.

† Resident, Otolaryngology.

‡ Professor of Anesthesiology.

§ Assistant Professor of Pathology.

¶ Associate Professor, Otolaryngology.

Received from the Departments of Anesthesiology, Medicine, Otolaryngology, and Pathology, and the Harborview Medical Center of the University of Washington, Seattle, Washington. Accepted for publication January 22, 1985. Supported by NIH Grant #R01HL19975 and a grant from the W. R. Grace Foundation. Presented in part at the International Anesthesia Research Society meetings, Reno, Nevada, March 1984.

Address reprint requests to Dr. Bishop: Department of Anesthesiology, Harborview Medical Center, 325 9th Avenue, Seattle, Washington 98104.

and the larynx removed. A pathologist, blinded as to the duration of intubation, ranked the damage to each larynx on a scale of 0 to 3 (table 1). A hemilarynx then was cut for microscopic examination after staining with hematoxylin and eosin and again ranked on a 0 to 3 scale (table 1). The subglottic larynx was examined but not graded, as no lesions were evident in any of the animals.

Photographs of the larynx of each dog were examined by three of the authors (E.A.W., M.J.B., and A.W.H.) to look for week to week differences.

The Spearman rank correlation coefficient was used to test for correlations between duration of intubation and laryngeal damage.

Results

Of the 14 animals entered in the study, 13 completed the investigation. The one animal eliminated extubated itself between the sixth and eighth week and was thus removed from the study.

Direct laryngoscopy at day 1 revealed either no abnormalities or mild mucosal erythema in all dogs. By day 7, ulceration of the mucosa overlying the vocal process of the arytenoid cartilage was present in all dogs (fig. 1). Review of notes from the time of examination and subsequent study of the photographs demonstrated clear differences between the appearances of the larynges at day 1 and day 7, but no further changes could be routinely appreciated after that and a rank order by severity could not be established from the photographs.

Examination of the excised larynges demonstrated minimal changes—primarily erythema—in dogs killed at day 1. These larynges were clearly distinguishable from those of dogs killed at 14 days and later, in whom ulcers were uniformly present over the vocal processes of the arytenoids with exposed cartilage present in a 14-day dog, a 28-day dog, and both 84-day dogs (fig. 2). Correlation of duration of intubation with severity of injury was high when all dogs were included (Spearman's correlation coefficient $r_s = 0.71$, $P < 0.02$), but there was no correlation when dogs killed on day 1 were excluded ($r_s = 0.40$, $P > 0.2$).

Microscopic examination revealed intact laryngeal mucosa with submucosal vascular congestion and mixed neutrophil and lymphocyte infiltration in dogs killed at 1 day. Mucosal ulceration was routinely present at 2 weeks with marked neutrophilic infiltration of the mucosa, which, in four of ten dogs, extended into the cartilage. Complete scores as a function of duration of intubation are presented in figure 3. While granulation tissue was present in some of the ulcers, no fibrosis was seen in any of the sections. Analysis of the data again revealed no correlation of severity of microscopic

TABLE 1. Pathology Scoring System

Score	
Gross	
0	Normal larynx
1	Mucosal erythema and/or edema
2	Mucosal erosion present
3	Exposed arytenoid cartilage
Microscopic	
0	Normal larynx
1	Mucosal inflammation
2	Mucosal disruption and ulceration
3	Deep ulceration with inflammation or erosion of cartilage

changes, with duration of intubation excluding animals killed after 1 day ($r_s = 0.4$, $P > 0.2$), but a positive correlation was present if those animals were included ($r_s = 0.71$, $P < 0.02$). No lesions were found in the subglottic region in any of the animals.

Discussion

We found that laryngeal injury reaches maximum severity between days 1 and 7, with no clear correlation with the duration of intubation beyond that point. We could not identify a time at which fibrosis begins in laryngeal injury, perhaps due to the small number of animals studied.

The lack of stenosis in any dogs was not surprising to us and can be accounted for by several factors. In humans, after comparable periods of intubation, the published incidences of stenosis ranges from 0 to 15%.^{2,5,6}

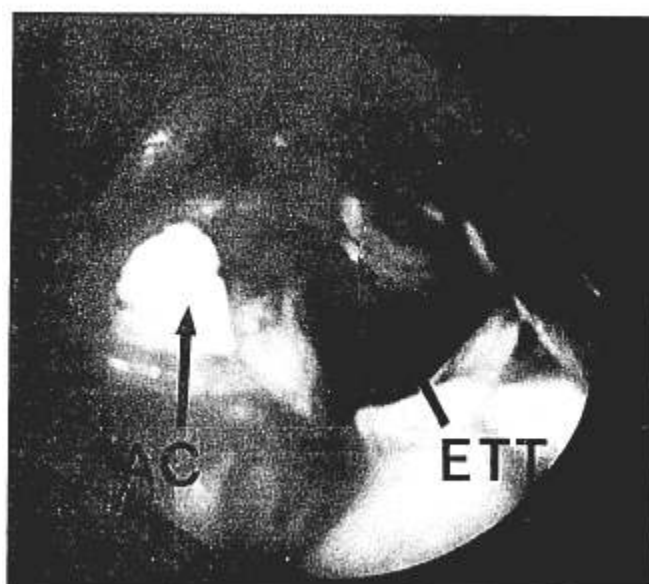


FIG. 1. Photograph obtained during examination at 1 week demonstrates severe mucosal erosion. Arrow AC points to exposed arytenoid cartilage. Arrow ETT points to tube segment.

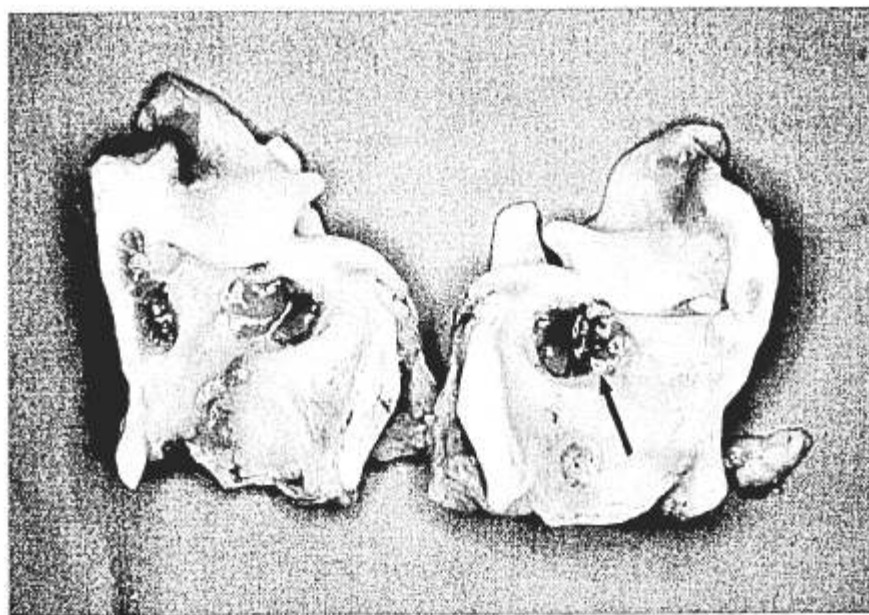


FIG. 2. Excised larynx from a dog killed at 2 weeks. Severe mucosal erosion is evident.

When stenosis does develop, it often does not occur until several weeks after extubation,^{2,7} whereas our dogs were killed at the time of extubation. Finally, there is evidence that tracheotomy itself may contribute to stenosis, since the inflamed vocal cords can remain apposed and may scar together.^{8,9} Since our animals did not go on to tracheotomy, there was no opportunity for this to occur.

The lesions observed in our animals were similar to those seen frequently in human autopsy specimens after prolonged intubation,^{3,4,10} which include ischemic ulcers

over the vocal processes occurring as early as 7 h after intubation. A major difference between lesions in humans and in our study animals was the complete lack of ulceration in the subglottic mucosa over the posterior cricoid. Two factors may account for the lack of subglottic lesions; the anatomic differences between the human larynx and the dog larynx and the lack of an inflated cuff in our segments.

In the human, the arytenoid cartilages slide apart during laryngeal opening to expose a portion of the cricoid,¹¹ whereas in the dog, the arytenoids rotate but

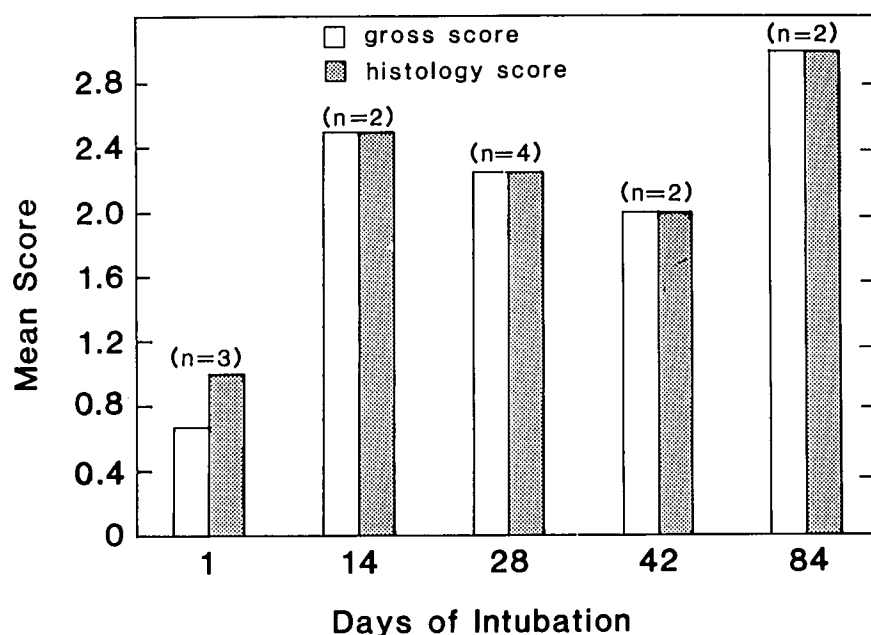


FIG. 3. Histogram demonstrating mean scores for gross and microscopic examination for groups killed at 1, 14, 28, 42, and 84 days of intubation.

do not separate. Thus, in the dog, the tube is suspended between the arytenoids and does not contact the mucosa overlying the cricoid cartilage.

A second explanation for the lack of lesions in the subglottic area is the lack of an inflated cuff. Subglottic lesions may be related to mucosal ischemia produced by cuff inflation to pressures exceeding the mucosal perfusion pressure.

The lesions we saw are consistent with necrosis resulting from direct pressure of the tube against the mucosa, which occludes the local circulation.¹² Based on our observations, the mucosal necrosis takes place relatively rapidly, but there appears to be little change in the lesion thereafter.

In humans, the importance of the duration of intubation in producing serious injury remains controversial.^{2,3,4,13} One reason for this may be that in humans, prolonged intubation correlates with a multiplicity of factors that could contribute to more severe injury—infection, poor nutrition, episodes of hypotension, and steroid therapy might be included in such a list. In the dogs, the laryngeal problem was an isolated problem with none of them developing any major complications.

Another major difference between our animals and humans was the greater activity and spontaneous ventilation as compared with the often-restrained sedated, and mechanically ventilated intensive care unit patient. There is controversy whether movement of the tube abrades the larynx and causes injury¹⁴ or whether injury results primarily from pressure necrosis.¹¹ Whether the ability of our animals to move about freely increased the extent of injury cannot be stated, but a human study specifically evaluated the effect of movement on laryngeal injury during prolonged intubation and found no correlation between motion and injury severity.³

Because of the differences between the dog model and the intensive care unit clinical situation, no definitive conclusions about duration of intubation and laryngeal injury can be made. However, these data suggest that a

tracheotomy intended to prevent laryngeal injury may need to be done very early. Thereafter, duration of intubation alone does not appear to warrant great weight as a criterion for performing a tracheotomy.

References

1. Bishop MJ, Weymuller EA Jr, Fink BR: Laryngeal effects of prolonged intubation. *Anesth Analg* 63:335-342, 1984
2. Whited RE: A prospective study of laryngotracheal sequelae in long-term intubation. *Laryngoscope* 94:367-377, 1984
3. Stauffer JL, Olson DE, Perry TL: Complications and consequences of endotracheal intubation and tracheostomy. *Am J Med* 70: 65-76, 1981
4. Donnelly WH: Histopathology of endotracheal intubation. *Arch Pathol* 88:511-520, 1969
5. Sellery GR, Worth A, Greenway RE: Late complications of prolonged tracheal intubation. *Can Anaesth Soc J* 25:140-143, 1978
6. Tonkin JP, Harrison GA: The surgical management of the laryngeal complications of prolonged intubation. *Laryngoscope* 81:297-307, 1971
7. Hawkins DB: Glottic and subglottic stenosis from endotracheal intubation. *Laryngoscope* 87:339-346, 1977
8. Eschapasse H, Lacomme Y, Hassani M, Henry E, Glovaes D, Gaillard J: Sténoses laryngées et trachéales apres intubation et/ou trachéostomie. *Acta Chir Belg* 76:381-385, 1979
9. Sasaki CT, Fukuda H, Kirchner JA: Laryngeal abduction activity in response to varying ventilation resistance. *Trans Am Acad Ophthalmol Otolaryngol* 77:403-420, 1973
10. Lindholm CE: Prolonged endotracheal intubation. *Acta Anaesthesiol Scand (Suppl)* 33:1-131, 1969
11. Fink BR: *The Human Larynx*. New York, Raven Press, 1975, pp 16-18, 121-129
12. Weymuller EA, Bishop MJ, Fink BR, Hibbard AW, Spelman FA: Quantification of intralaryngeal pressure exerted by endotracheal tubes. *Ann Otol Rhinol Laryngol* 92:444-447, 1983
13. Kastanos N, Miro RE, Perez AM, Mir AM, Agusti-Vidal A: Laryngotracheal injury due to endotracheal intubation: Incidence, evolution, and predisposing factors. A prospective long-term study. *Crit Care Med* 11:362-367, 1983
14. McGovern FH, Fitz-Hugh GS, Edgemon LJ: The hazards of endotracheal intubation. *Ann Otol Rhinol Laryngol* 80:556-564, 1971