

FIG. 1. Rusch® Nasal Airway with flange removed.

be aspirated, and the patient's life may depend on the shape or available lumen of the equipment and the positioning of the patient. It was fortuitous that the tube did not permanently enter one of the main bronchi, producing occlusion of the other.

In selecting equipment for use in patients unable to guard their airways, thought must be given to the dangers of aspiration. Other brands of nasopharyngeal airways have permanent flanges that cannot be removed making aspiration, swallowing, or impaction of the airway into the nose or nasopharynx much more difficult. Also, a radioopaque inclusion in the nasal airway would have made the radiologic diagnosis much easier. Presence of such a radioopaque wire in the missing flange would have completely laid to rest fears that the flange was

deeper in the tracheobronchial tree or in the digestive tract.

Another valuable lesson is that, no matter how unlikely it seems that the equipment could have been aspirated, if the position of the foreign body is not known for certain, the patient should undergo bronchoscopy prior to intubation. Laryngoscopy was performed by experienced anesthesiologists and otolaryngologists, all of whom saw the vocal cords in the open position, and none was able to recognize the nasal airway below the glottis. While preparing the patient for endoscopy, a lively debate took place over the impossibility of this awake, semialert, and only intermittently coughing patient having aspirated an object as large as a nasal airway without more respiratory symptoms. The symptom complex observed in sedated, disoriented, or elderly or very young patients can be an unreliable indicator of the possible aspiration.

Nasal airways with moveable flanges carry a risk of aspiration, since, when lubricated for insertion, the adjustable flange can slip off, permitting aspiration of the tube. Radioopaque inclusions in any equipment used near patients make the diagnosis of foreign body aspiration much easier, but when there is any doubt as to the location of a foreign body, bronchoscopy should be performed prior to intubation to avoid potentially pushing a foreign body further into the tracheobronchial tree.

REFERENCES

1. Wanner A: Nasopharyngeal airway: A facilitated access to the trachea. *Ann Int Med* 75:593-595, 1971
2. Howat DDC: Disposable nasopharyngeal airways—a potential hazard (Letter to the Editor). *Anaesthesia* 37:101, 1982

Anesthesiology
62:535-538, 1985

Compressed Spectral Array EEG Monitoring during Cardiac Arrest and Resuscitation

WILLIAM L. YOUNG, M.D.,* AND EUGENE ORNSTEIN, PH.D., M.D.†

Knowledge of the electrical activity of the brain during cardiac arrest and resuscitation has been gained almost exclusively from animal models of cerebral isch-

emia. Ongoing EEG monitoring in patients who are hemodynamically stable and suffer sudden but reversible cardiac arrest is extremely rare. One such instance of EEG monitoring in a patient suffering an episode of intraoperative ventricular asystole with successful resus-

* Instructor in Clinical Anesthesiology.

† Assistant Professor of Anesthesiology.

Received from the Department of Anesthesiology, College of Physicians and Surgeons, Columbia University, 630 W. 168th St., New York, New York 10032. Accepted for publication October 30, 1984.

Address reprint requests to Dr. Young.

Key words: Complications: arrest, cardiac. Monitoring: Spectral array EEG.

citation was reported by Moss and Rockoff.¹ They presented a case of emergency carotid endarterectomy, during which a 27-s period of asystole occurred with cessation of cerebral electrical activity within 15 s. Cerebral electrical activity returned promptly with resuscitation. Lead placement in this case consisted of Fp₁-C₃, C₃-O₁, Fp₂-C₄, C₄-O₂, T₃-C₃, C₃-C₄, and C₄-T₄.

There have been attempts to process the raw EEG signal electronically in an effort to facilitate its interpretation under circumstances of clinical monitoring. The first commercially available device, the Cerebral Function Monitor® (CFM), was described by Maynard *et al.*² There have been reports of ongoing EEG analysis utilizing this device during cardiac arrest.²⁻⁴ The various types of automated EEG processing are reviewed elsewhere.⁴

Two methods of processed EEG analysis that have been introduced are compressed spectral array (CSA) and density spectral array (DSA). Both of these methods employ computer processing and make use of the Fast Fourier Transform. Certain statistical descriptors of the frequency spectrum can be derived for any given period of EEG sampling time or epoch. One such descriptor is the spectral edge frequency (SEF)⁵ and is defined as being the highest frequency component of the EEG visible in the current spectrum.

We report here a case of sudden intraoperative cardiac arrest and resuscitation, during which time the patient was monitored with a commercially available CSA device. As with previously reported standard EEG and CFM monitoring, it demonstrates the changes in cerebral electrical activity as a consequence of cardiac arrest. It also serves to demonstrate the CSA format and the changes in SEF recorded during the arrest period.

REPORT OF A CASE

The patient, a 75-year-old man, had a history of several episodes of amaurosis fugax during the preceding year. Other medical history included mild hypertension and palpitations. Medications included dipyridamole and aspirin. Angiography disclosed severe left internal carotid artery stenosis. Preoperative ECG showed possible old anteroapical myocardial infarction. Because of recurrent TIAs, a left carotid endarterectomy was performed.

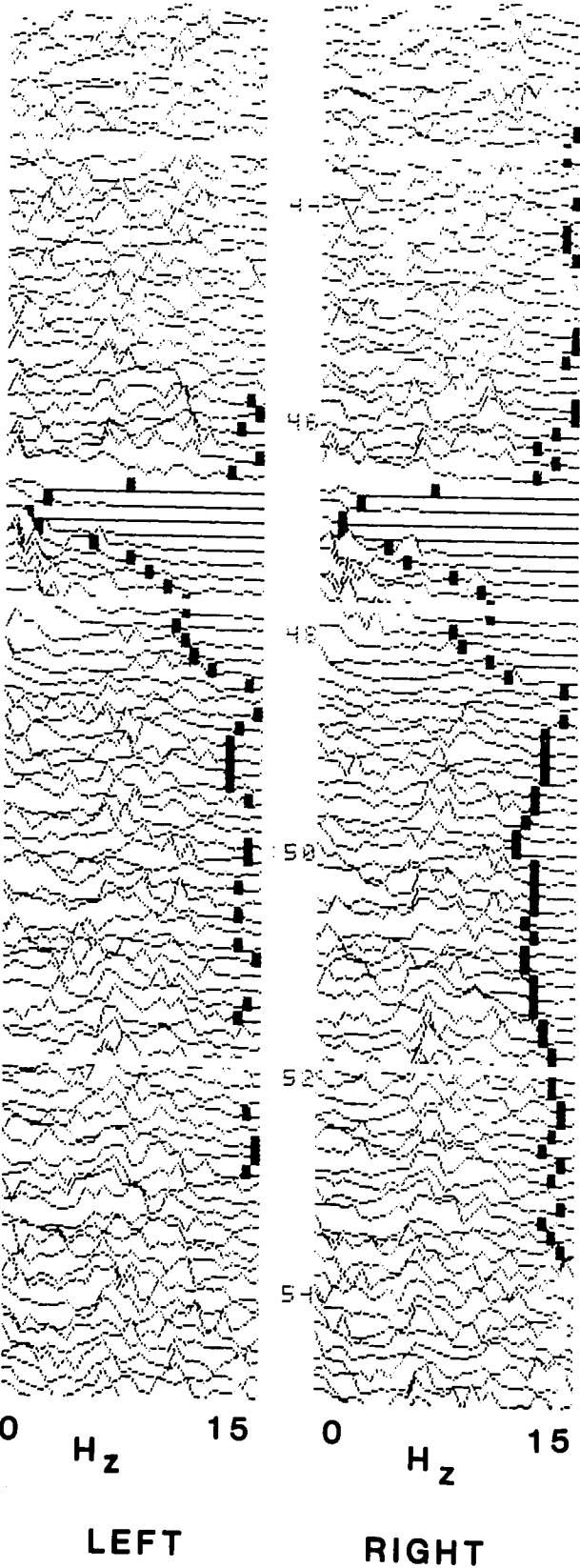
A commercially available CSA device (Neurotrac®, Interspec Medical, Conshohocken, Pennsylvania) was used for EEG monitoring. Lead placement consisted of a bilateral frontal to mastoid montage, with a reference lead placed between the two frontal leads. Electrodes were standard AgCl ECG pads (Red Dot®, 3M, Minneapolis, Minnesota). Following insertion of intravenous and radial artery catheters, and placement of an ECG monitor, general anesthesia was induced with thiopental, 300 mg, and fentanyl, 0.02 mg, iv. Succinylcholine was given iv to facilitate endotracheal intubation. Anesthesia was maintained with N₂O/O₂, 60:40% and 0.5% isoflurane (inspired). Metocurine was given for muscle relaxation. Ventilation was controlled mechanically to maintain P_{CO₂} at 35–40 mmHg. Arterial blood pressure was maintained at approximately the patient's preoperative level of 140/70 mmHg by means of a phenylephrine infusion as

needed. When the carotid artery initially was cross-clamped, the heart rate fell from 65 to 43 bpm, with an abrupt fall in arterial blood pressure to 95/50 mmHg. This was treated with atropine 0.5 mg iv, with prompt return of blood pressure and heart rate to their previous values within 60 s. There was no change in the EEG during this event.

The remainder of the operation was uneventful, and EEG monitoring revealed no signs of cerebral ischemia. Isoflurane was discontinued during wound closure, and 15 min later, at the conclusion of surgery, the neuromuscular blockade was antagonized with neostigmine (3 mg) and glycopyrrolate (0.3 mg) given iv. At this time, the heart rate was 100 bpm and arterial blood pressure 110/70 mmHg. Over the next 2 min, the heart rate gradually slowed to 70 bpm, and over 10–20 s progressed to asystole with loss of arterial pressure waveform. Manual chest compression was instituted, and the patient was ventilated manually with 100% oxygen. Normal sinus rhythm, rate (65 bpm), and blood pressure (110/70 mmHg) returned within 60 s. Arterial blood pressure and heart rate stabilized at these levels. No additional drugs were given during the arrest period. The CSA tracing for the arrest period is shown in figure 1. The trachea was extubated and the patient was brought to the neurologic intensive care unit for recovery. Postoperatively, the patient had no neurologic deficit and no evidence of myocardial damage by ECG or cardiac enzyme assays. The patient had no recall of the intraoperative period.

DISCUSSION

In our case, cardiac arrest occurred following termination of surgery, immediately after reversal of neuromuscular blockade. The CSA pattern in the immediate prearrest period probably reflects the residual effects of isoflurane anesthesia at subanesthetic levels⁶ with the frequency spectrum extending into the 15–20 Hz range (fig. 1). During this case, monitoring was carried out using only a 15-Hz display range, so the higher components of the frequency spectrum lie to the right of the displayed spectral axis for each channel. The SEF is denoted by a dark bar and is seen to be absent during those epochs, with EEG activity extending beyond the 15-Hz display cutoff. After injection of neostigmine and glycopyrrolate and the onset of bradycardia, the SEF can be seen to move to the left somewhat, even before there was any change in blood pressure. After onset of asystole, the SEF can be seen to fall to 1–2 Hz within 30 s, corresponding to the onset of inadequate cerebral oxygen availability. Perhaps the onset of chest compression prevented the SEF from falling to zero and contributed to the gradual rise in the SEF back toward the prearrest baseline. Unfortunately, no concurrent display of the raw EEG is possible with this particular monitor. Low-frequency artifact secondary to chest massage may have prevented the SEF from falling to zero. The relative contributions of chest massage and return to normal sinus rhythm to the shifting of the SEF toward the prearrest baseline cannot be ascertained. Sixty to 90 s after restoration of normal sinus rhythm, the SEF appears to have reached a new, somewhat lower baseline



EVENT	BP	HR
NEOSTIGMINE ADMINISTERED	110/70	100
BRADYCARDIA ASYSTOLE CHEST COMPRESSION	110/70	70
RETURN OF SINUS RHYTHM	110/70	65

FIG. 1. Compressed spectral array EEG tracing obtained during cardiac arrest and resuscitation. Lead placement: Left frontal and left mastoid leads, left column; right frontal and right mastoid leads, right column. Reference lead placed on forehead in the midline. Numbers between columns are minutes. Dark vertical bars denote spectral edge frequency (SEF). The horizontal axis is frequency in Hz (scale 0-15). Each line of CSA tracing reflects an 8-s epoch of processed EEG information recorded with a gain setting on the CSA device of 80 μ V p-p. Events are denoted at the right of the CSA tracing.

as compared with the prearrest period. The reason for this is unclear. Perhaps transient cerebral ischemia may have caused this, although the period of ischemia was brief. The SEF can be seen to shift gradually back to the right and, as in the prearrest period, move to the right of the frequency display cut-off of 15 Hz.

Rampil *et al.*⁷ reported a transient depression of the SEF following injection of an atropine-neostigmine mixture for reversal of neuromuscular blockade in a series of patients undergoing carotid endarterectomy monitored by a DSA device. They did not report if any hemodynamic changes occurred with drug administration. Although the effect of anticholinesterases on anesthetic depth is controversial, evidence does exist for an effect of neostigmine to decrease halothane MAC in the dog.⁸ Physostigmine, which crosses the blood-brain barrier to a greater extent than neostigmine, appears to confer some protection against hypoxia in the rat.⁹ Although this has not been investigated, neostigmine may have some central nervous system active properties capable of influencing the EEG during recovery from ischemia or anesthesia.

On-line EEG monitoring for cerebral ischemia until recently has been relatively restricted for the most part to research settings, as standard 16- or 20-lead EEG placement and interpretation require personnel with specialized training and the data are spread over many pages at standard paper speed. Recent advances in technology have enabled EEG information to be processed and displayed in a form that may facilitate the interpretation of complex EEG patterns. One result is that clinicians may monitor cerebral function as an integrated part of monitoring other rapidly changing physiologic functions. Spectral analysis of the EEG has been applied successfully to several clinical situations, most notably in monitoring the adequacy of cerebral perfusion during carotid endarterectomy,^{7,10} and cardiopulmonary bypass.¹¹ It also has found a place, although less well defined, in monitoring critically ill patients in an ICU setting¹² and assessing depth of anesthesia.¹³

There is a strong correlation between EEG frequency and both oxygen uptake of brain and cerebral blood flow.¹⁴ In studies carried out during carotid endarterectomies, a reduction in regional cerebral blood flow below a critical level results in predictable ischemic EEG changes; restoration of regional cerebral blood flow by use of an indwelling shunt invariably is accompanied by reversal of these changes.¹⁵ This case demonstrates the loss of cerebral electrical activity with asystole and its prompt return following resuscitation. It demonstrates

the CSA format in the setting of cardiac arrest, and one statistical descriptor of the CSA, the SEF. The use of a single statistical descriptor applied to spectral analysis of EEG has been questioned.¹⁶ Further work remains to be done to determine the exact nature of the relationship between cardiac arrest, resuscitation, and neurologic outcome and computer-processed EEG monitoring techniques.

REFERENCES

1. Moss J, Rockoff M: EEG monitoring during cardiac arrest and resuscitation. *JAMA* 244:2750-2751, 1980
2. Maynard D, Prior PF, Scott DF: Device for continuous monitoring of cerebral activity in resuscitated patients. *Br Med J* 4:545-546, 1969
3. Prior PF, Maynard DE, Sheaff PC, Simpson BR, Strunin L, Weaver EJM, Scott DF: Monitoring cerebral function: Clinical experience with a new device for continuous recording of electrical activity of brain. *Br Med J* 2:736-738, 1971
4. Levy WJ, Shapiro HM, Maruchak G, Meathe E: Automated EEG processing for intraoperative monitoring: A comparison of techniques. *ANESTHESIOLOGY* 53:223-236, 1980
5. Rampil IJ, Sasse FJ, Smith NT, Hoft BH, Fleming DC: Spectral edge frequency—A new correlate of anesthetic depth. *ANESTHESIOLOGY* 53:S12, 1980
6. Stockard JJ, Bickford RG: *The neurophysiology of anaesthesia, A Basis and Practice of Neuroanaesthesia*. Edited by Gordon E. New York, Elsevier/North Holland Biomedical Press, 1981, p 1-49
7. Rampil IJ, Holzer JA, Rosenbaum S, Quest D, Correll J: Prognostic value of computerized EEG analysis during carotid endarterectomy. *Anesth Analg* 62:186-192, 1983
8. Horrigan RW: Physostigmine and anesthetic requirement for halothane in dogs. *Anesth Analg* 57:180-185, 1978
9. Scremin AME, Scremin OU: Physostigmine-induced cerebral protection against hypoxia. *Stroke* 10:142-143, 1979
10. Chiappa KH, Burke SR, Young RR: Results of electroencephalographic monitoring during 367 carotid endarterectomies: Use of a dedicated minicomputer. *Stroke* 10:381-388, 1979
11. Myers RR, Stockard JJ, Saidman LJ: Monitoring of cerebral perfusion during anesthesia by time compressed Fourier analysis of the EEG. *Stroke* 8:331-337, 1977
12. Bricolo A, Turazzi S, Faccioli F, Odorizzi F, Sciarreta G, Erculiani P: Clinical applications of compressed spectral array in long-term EEG monitoring of comatose patients. *Electroenceph Clin Neurophysiol* 45:211-225, 1978
13. Smith NT, Dec-Silver H, Sanford TJ, Westover CJ, Quinn ML, Klein F, Davis DA: EEGs during high-dose fentanyl-, sufentanil-, or morphine-oxygen anesthesia. *Anesth Analg* 63:386-393, 1984
14. Ingvar DH, Sjolund B, Ardo A: Correlation between dominant EEG frequency, cerebral oxygen uptake and blood flow. *Electroenceph Clin Neurophysiol* 41:268-276, 1976
15. Sundt TM, Sharbrough FW, Piepgras DG, Kearns TP, Messick JM, O'Fallon WM: Correlation of cerebral blood flow and EEG changes during carotid endarterectomy. *Mayo Clin Proc* 56:533-543, 1981
16. Levy WJ: Intraoperative EEG patterns: Implications for EEG monitoring. *ANESTHESIOLOGY* 60:430-434, 1984