

intraoperative period, a sample of blood was drawn from the distal port of the triple lumen catheter for measurement of blood glucose. The sample was noted to be bright red in color, and blood-gas analysis revealed a  $P_{O_2}$  of 62 mmHg and an oxygen saturation of 92%, with an  $FI_{O_2}$  of 0.4. A simultaneously drawn venous blood sample from a left antecubital vein had a  $P_{O_2}$  of 49 mmHg and an oxygen saturation of 81%. Concern arose over the possibility that the cannulation of an artery had indeed occurred and that the typical venous pressure wave form obtained from the catheter was perhaps due to a resulting damage to the artery.

We believe this unexpected observation can be explained by the presence of the arteriovenous shunt in the patient's right forearm for his regular hemodialysis therapy. This shunt delivered arterial blood via the axillary and subclavian veins into the superior vena cava distal to the tip of the multilumen catheter, leading to high oxygen saturation of central venous blood. Radiographic study obtained postoperatively confirmed the location of the catheter tip at the junction of the superior vena cava and the right atrium.

In conclusion, the presence of an ipsilateral arteriovenous fistula in a patient receiving regular hemodialysis therapy may result in arterialization of blood obtained from a jugular venous catheter and give rise to concern over possible arterial placement of the catheter.

ALIASGHAR AGHDAMI, M.D.  
*Associate Professor*

ROBERT ELLIS, M.D.  
*Assistant Professor*

*Medical College of Virginia  
Richmond, Virginia 23298*

#### REFERENCES

1. Jobes DR, Schwartz AJ, Greenhow DE, Stephenson LW, Ellison N: Safer jugular vein cannulation: Recognition of arterial puncture and preferential use of the external jugular route. *ANESTHESIOLOGY* 59:353-355, 1983
2. Morgan RNW, Morrell DF: Internal jugular catheterization: A review of a potentially lethal hazard. *Anaesthesia* 36:512-517, 1981

*(Accepted for publication October 12, 1984.)*

Anesthesiology  
62:373-374, 1985

### Securing the Epidural Catheter

*To the Editor:*—The epidural catheter typically is secured to the back with sterile gauze and adhesive tape.<sup>1</sup> Epidural catheter dislodgment, migration, and kinking continue to be management problems.<sup>2</sup> The Tegaderm® (3M) dressing is a clear, sterile gas-permeable

dressing widely used at our institution to secure intravenous and arterial catheters in a sterile field, providing a barrier to infection. Recently, we have extended this practice to our obstetrics service. Rather than coiling epidural catheters under sterile gauze, we place a Tegaderm® dressing over a single loop of catheter and secure it in the customary fashion (fig. 1). To our knowledge, this practice has not been described in the literature. We feel that this practice provides better anchorage, allows direct inspection, and facilitates repositioning of the malpositioned catheter. Further, we feel that this technique may decrease the incidence of dislodged or migrated catheters.

MARTIN BROWN, M.D.  
*Senior Resident*

PAUL REIN, D.O.  
*Assistant Professor and Director of Obstetrical Anesthesia*  
*Department of Anesthesiology  
Medical College of Virginia  
MCV Station Box 695  
Richmond, Virginia 23298*

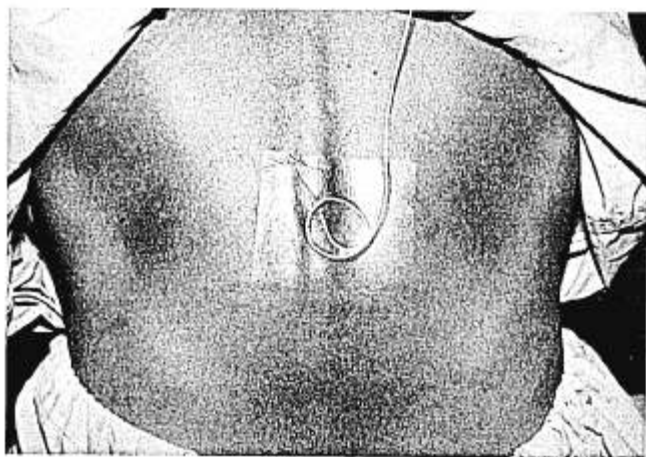


FIG. 1. Tegaderm® dressing covering epidural catheter.

## REFERENCES

1. Bromage PR: Epidural Analgesia. Philadelphia, WB Saunders, 1968, p 226
2. Climie CR: Shield for epidural catheters. *Anaesthesia* 15:331, 1960

(Accepted for publication October 12, 1984.)

Anesthesiology  
62:374, 1985

## Decreasing the Incidence of Upper Airway Bleeding when Using a Large-size Nasotracheal Tube

*To the Editor:*—Some groups advocate nasotracheal intubation as the technique of choice when prolonged ventilatory support is anticipated after open heart surgery. However, mucosal trauma resulting in severe bleeding due to anticoagulation during cardiopulmonary bypass limits its use. While a small-size endotracheal tube (ETT 7.0 mm ID) would decrease the risk of bleeding and mucosal trauma, it is likely to increase airway resistance<sup>1</sup> and thus the work of breathing during weaning from mechanical ventilation.

Modifying the nasotracheal intubation sequence, with equipment available in all operating suites, has permitted insertion of larger ETT (8.0 or 8.5 mm ID), while decreasing dramatically the incidence of these complications over the last 2 years, in our practice.

Suitable low-pressure cuff ETT are placed in an oven (50° C) next to the OR to soften the plastic of the ETT 15 min before expected intubation time. The cuff generously is lubricated with liquid sterile petroleum jelly. After induction, the selected nasal airway may be cleaned with an appropriate solution, which afterwards is suctioned. Then 5 ml liquid sterile petroleum jelly is poured down the selected nostril. The laryngoscope is positioned in the glosso-epiglottic fold to expose the vocal cords and to allow suctioning of the excess lubricant. The combined effect of temperature-induced softening and lubrication greatly facilitate the introduction of the ETT without any crunching feeling! Flexion of the head and cricoid compression allow axial alignment of tracheal and the nasal airway so that the tube easily can be introduced past the laryngeal inlet into the trachea.

Should the ETT tip impinge on the anterior laryngeal wall, 90-degree rotation counter clockwise usually will permit tracheal placement without resorting to a Magill forceps and the attending risk of cuff damage. If the

left nostril is selected, the ETT should be introduced with its concavity facing the anesthetist, that is, with its curvature in the opposite direction of the natural curvature of the nasal airway. This maneuver permits the sharp bevel of the ETT to slide along the septum, avoiding trauma to the richly vascular mucosa of the turbinates. Subsequently, the ETT is rotated 180 degrees clockwise and advanced in the trachea as previously described. This modified sequence can be used either with muscle relaxation or with topical anesthesia for awake intubation.

The introduction of a softened endotracheal tube via a generously lubricated nostril has made possible placement of larger endotracheal tubes, offering potential advantages of decreased upper airway bleeding incidence, decreased work of breathing during weaning, and easier tracheobronchial cares.

L. QUINTIN  
M. GHIGNONE  
*Health Sciences Center  
Texas Tech University  
Lubbock, Texas*

P. ODELIN  
R. TRINQUIER  
L. RUYNAT  
B. DU GRES  
*Departments of Anesthesia  
Hopital Cardiologique 69394 Lyon  
Hopital Henri Mondor  
94010 Creteil, France*

## REFERENCE

1. Nunn JF: Applied respiratory physiology. London, Butterworth, 1972, p 87

(Accepted for publication October 12, 1984.)