

REFERENCES

1. Wray RP: A source of nonanesthetic nitrous oxide in operating room air. *ANESTHESIOLOGY* 52:88-89, 1980
2. Kaarakka P, Malischke PR, Kreul JF: Alternative sites for measuring breathing zone N₂O levels. *ANESTHESIOLOGY* 55:A139, 1981
(Accepted for publication September 10, 1984.)

Anesthesiology
62:207, 1985

Lamp Placement and the Miller I Laryngoscope Blade

To the Editor:—In the June 1984 issue of *ANESTHESIOLOGY*, Dr. Diaz described the modifications of the straight Miller blade, suggested to facilitate laryngoscopy.¹ The Miller I blades currently available differ considerably from that originally described and illustrated by Dr. Miller.² He recognized the necessity of

placing the lamp close to the distal end of the blade for adequate laryngeal illumination.

I have modified the Welch-Allyn Miller I blade by removing the distal 13 mm of the blade and refashioning the distal end with a slight curve. Figure 1 shows the standard Welch-Allyn and Penlon Miller I blades and the shortened Welch-Allyn version. The modified blade has a working length of 67 mm, compared with the original 80 mm length. On laryngoscopy, the lamp is closer to the larynx, greatly improving illumination. With the manufacturer's models, the pharyngeal and paraepiglottic tissues often prolapse onto the lamp.

For patients up to 6 months of age, the shortened blade has no disadvantages.

R. D. M. JONES
Director of Anaesthesia
The Grantham Hospital
125 Wong Chuk Hang Road
Aberdeen, Hong Kong

REFERENCES

1. Diaz JH: Further modifications of the Miller blade for difficult pediatric laryngoscopy. *ANESTHESIOLOGY* 60:612-613, 1984
2. Miller RA: A new laryngoscope. *ANESTHESIOLOGY* 2:317-320, 1941

(Accepted for publication September 10, 1984.)

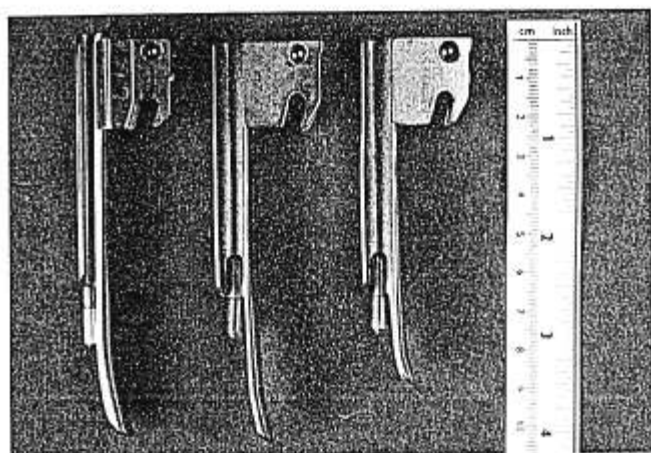


FIG. 1. Left: Standard Penlon Miller I blade. Middle: Standard Welch-Allyn Miller I blade. Right: Shortened Welch-Allyn Miller I blade.

Anesthesiology
62:207-208, 1985

A Case of Artifactual S-T Depression

To the Editor:—Recently, during a routine cholecystectomy, new and significant S-T segment depression appeared on our Hewlett-Packard® #78304A ECG monitor. This occurred while we monitored lead II (fig. 1). Fortunately, the depression lasted only a few minutes and resolved spontaneously without treatment.

After resolution, we checked all the lead wire attachments; each was well secured. Then, accidentally, we found that minor movement of the patient cable holding the lead wires could produce or terminate the S-T segment changes at will.

The New Dimensions in Medicine (NDM) fully shielded ECG lead wire with snap electrode connector

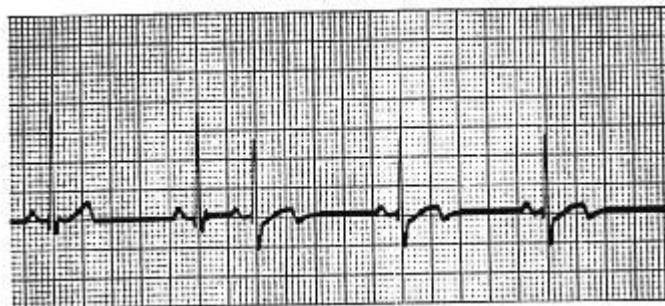


FIG. 1. New and significant S-T segment depression and T-wave configuration change occurring with minor movement of the NDM patient cable: lead wire interface.