

## CLINICAL REPORTS

Ronald D. Miller, M.D., Editor

Anesthesiology  
62:180-182, 1985

### Successful Treatment of Accelerated Junctional Rhythm with Propranolol: Possible Role of Sympathetic Stimulation in the Genesis of this Rhythm Disturbance

MICHAEL J. BRESLOW, M.D.,\* ALEX S. EVERS, M.D.,† AND PHILLIP LEBOWITZ, M.D.‡

Accelerated junctional rhythms (ventricular rate >60 bpm) are common during general anesthesia.<sup>1,2</sup> Little is known, however, about the etiology of this rhythm disturbance. We recently cared for a patient with multiple episodes of accelerated junctional rhythm in whom propranolol consistently resulted in conversion to sinus rhythm. The reproducible response of this patient to a beta-adrenergic receptor antagonist suggests that overactivity of the sympathetic nervous system often may be responsible for this rhythm disturbance.

#### REPORT OF A CASE

A 75-year-old man was scheduled for insertion of an aortobifemoral prosthesis. He had claudication at 1-2 blocks but was otherwise healthy. Physical examination and admission laboratory studies were normal. Diazepam 10 mg orally and morphine sulfate 10 mg im were given for premedication. On arrival to the operating room he was awake and calm, arterial blood pressure was 102/55 mmHg, heart rate 77 bpm (sinus rhythm), and respiratory rate 12 breaths/min. Following induction of anesthesia with thiopental and pancuronium iv, the trachea was intubated. Additional morphine sulfate (10 mg) iv and nitrous oxide then were given. Approximately 1 h later, halothane (0.5-1.0 %) was added. Shortly thereafter, an accelerated junctional rhythm occurred that persisted for the next 2 h, despite substituting enflurane (0.75-1.5 %) for halothane. Throughout this time, heart rate varied from 88 to 100 bpm and arterial blood pressure ranged from 110/70 to 120/80 mmHg. At

this point, propranolol 0.25 mg was given iv and promptly was followed by return to sinus rhythm at a rate of 77 bpm. The arterial blood pressure increased to 145/86 mmHg with restoration of sinus rhythm. Twenty-five minutes later, accelerated junctional rhythm recurred, with an abrupt drop in blood pressure from 127/81 to 107/75 mmHg and an increase in heart rate from 71 to 88 bpm. Administration of 0.25 mg propranolol iv again resulted in return to sinus rhythm, an increase in blood pressure to 130/83 mmHg, and a decrease in heart rate to 74 bpm. Accelerated junctional rhythm recurred at four additional points during the procedure. Each episode of accelerated junctional rhythm was associated with similar changes in heart rate and arterial blood pressure as previously described. Administration of propranolol 0.25 to 0.5 mg iv always resulted in prompt return to sinus rhythm. One instance of this is shown in Figure 1. Sinus rhythm was maintained for a minimum of 20 min after propranolol. Following the sixth successful conversion to sinus rhythm with propranolol, sinus rhythm persisted for the duration of the case. Arterial blood samples obtained at regular intervals during the case showed that  $PaO_2$ ,  $PaCO_2$ ,  $pH$ , and potassium values were normal. Postoperatively the patient did well without recurrence of accelerated junctional rhythm.

#### DISCUSSION

Accelerated junctional rhythms occur frequently during general anesthesia.<sup>1,2</sup> In healthy patients they usually are associated with only modest decreases (~15%) in systemic arterial blood pressure and cardiac output,<sup>3,4</sup> probably as a result of loss of the atrial contribution to ventricular filling, and treatment is rarely necessary. While different investigators have induced accelerated junctional rhythm by bolus injection of pancuronium,<sup>3</sup> or by varying the concentrations of halothane during surgical stimulation,<sup>4</sup> the mechanism responsible for this frequently encountered rhythm disturbance is not known.

We feel our patient provides insight into the cause of some instances of accelerated junctional rhythm. Because of the recurrent nature of his accelerated junctional rhythms, we were able to clearly show that small dosages of propranolol consistently resulted in prompt conversion to sinus rhythm. Of note is the fact that the junctional rate was significantly in excess of the sinus rate. This suggests that at least some instances of accelerated junctional rhythm during anesthesia result from acceleration of AV nodal pacemaker cells. Presumably, the increased automaticity of these AV nodal cells is mediated

\* Assistant Professor, Departments of Anesthesiology/Critical Care Medicine and Medicine, The Johns Hopkins University School of Medicine.

† Assistant Professor, Departments of Anesthesiology and Medicine, Washington University School of Medicine.

‡ Assistant Professor, Department of Anesthesiology, Massachusetts General Hospital.

Received from the Departments of Anesthesiology/Critical Care Medicine and Medicine, The Johns Hopkins University School of Medicine, Baltimore, Maryland, the Departments of Anesthesiology and Medicine, Washington University School of Medicine, St. Louis, Missouri, and the Department of Anesthesiology, Massachusetts General Hospital, Boston, Massachusetts. Accepted for publication August 8, 1984.

Address reprint requests to Dr. Breslow: Department of Anesthesiology and Critical Care Medicine, The Johns Hopkins Hospital, Baltimore, Maryland 21205.

Key words: Dysrhythmias. Heart. Propranolol. Sympathetic nervous system.

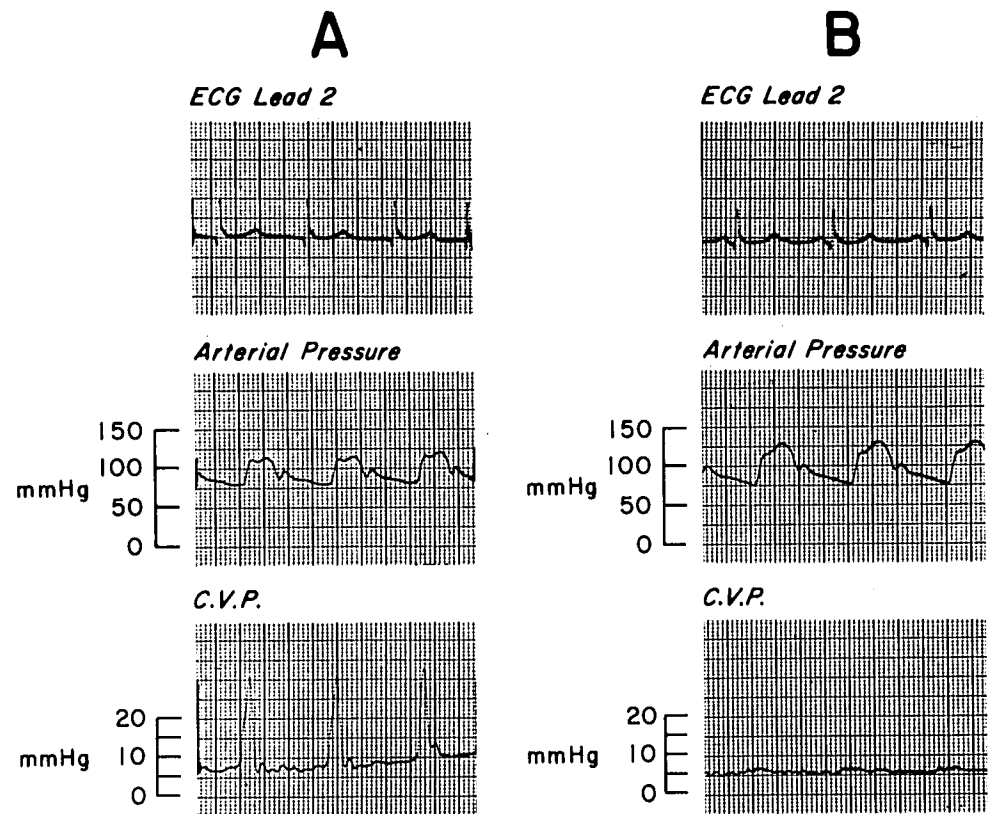


FIG. 1. Electrocardiogram and arterial blood pressure and central venous pressure tracings recorded intraoperatively. A. During accelerated junctional rhythm. B. Following conversion to sinus rhythm after administration of propranolol. Note absence of P waves on ECG and presence of canon A waves on central venous pressure tracing during junctional rhythm. Paper speed 25 mm/s.

by increased sympathetic activity. Propranolol, by antagonizing this sympathetically mediated increase in automaticity, allowed the SA node to regain electrical pre-eminence.

All pacemaker cells respond to sympathomimetic amines by increasing their rate of firing.<sup>5</sup> However, recent data suggest that the changes in ionic flux that mediate this increased automaticity in atrial tissue are different from the ionic permeability changes that occur in purkinje cells.<sup>6,7</sup> The existence of multiple mechanisms by which sympathetic stimulation increases automaticity provides a theoretic basis for dissimilar responses of different populations of pacemaker cells to sympathomimetic amines. This may be relevant to our patient in whom sympathetic stimulation resulted in a greater effect on AV nodal pacemaker cells than on sinus pacemaker cells. In addition, inhaled anesthetics have their own pronounced electrophysiologic effects that may modulate the response of different tissues to sympathetic stimulation. Hauswirth, in an *in vitro* preparation, showed that the automaticity of SA nodal cells is depressed more than that of lower pacemaker cells at low doses of halothane.<sup>8</sup> Reynolds, in other *in vitro* studies, demonstrated that halothane antagonizes the chronotropic effects of epinephrine at the SA node.<sup>9</sup> Perhaps inhaled anesthetics increase the likelihood that sym-

thetic stimulation will predominately affect AV nodal cells and predispose to the development of accelerated junctional rhythms.

In conclusion, we present a patient with recurrent accelerated junctional rhythm during general anesthesia who could be converted consistently to sinus rhythm by administration of the beta-adrenergic blocking agent, propranolol. The consistent response of this patient strongly suggests that sympathetic stimulation is important in the genesis of some instances of this rhythm disturbance.

#### REFERENCES

1. Vanik PE, Davis HS: Cardiac arrhythmias during halothane anesthesia. *Anesth Analg* 47:293-307, 1978
2. Kurer J, Eneseu V, Utsu F, Boszormeny E, Bernstein H, Corday E: Cardiac arrhythmias during anesthesia. *Dis Chest* 52:580-587, 1967
3. Laver MB, Turndorf H: Atrial activity and systemic blood pressure during anesthesia in man. *Circulation* 28:63-71, 1963
4. Haldeman G, Schaer H: Haemodynamic effects of transient atrioventricular dissociation in general anesthesia. *Br J Anaesthesia* 44:159-162, 1972
5. Hutter OF, Trautwein W: Vagal and sympathetic effects on the pacemaker fibers in the sinus venosus of the heart. *J Gen Physiol* 39:715-733, 1956
6. Hauswirth O, Noble D, Tsien RW: Adrenaline: mechanism of

- action on the pacemaker potential in cardiac purkinje fibers. *Science* 162:916-917, 1968
7. Brown HF, Noble SJ: Effects of adrenaline on membrane currents underlying pacemaker activity in frog atrial muscle. *J Physiol (London)* 238:51-53, 1974
  8. Hauswirth O: Effects on halothane on single atrial, ventricular, and purkinje fibers. *Circ Res* 24:745-750, 1969
  9. Reynolds AK, Chiz JF, Pasquet AF: Halothane and methoxyflurane: A comparison of their effects on cardiac pacemaker fibers. *ANESTHESIOLOGY* 33:602-610, 1970

Anesthesiology  
62:182-183, 1985

## Gastroduodenal Reflux of Irrigating Solution during Percutaneous Lithotripsy for Intrahepatic Cholelithiasis

MARK HARRIS, M.D.,\* WILLIAM R. KIMBALL, M.D., PH.D.,† HUGH H. YOUNG II, M.D.,‡  
RODNEY BUTCH, M.D.§

Percutaneous ultrasonic lithotripsy of renal calculi has been widely accepted by urologists for several years.<sup>1,2</sup> A nephroscope can be introduced into the closed urinary tract system and an ultrasonic probe advanced toward the calculi under direct vision. Once contact is made, the stone can be fragmented and the obstruction relieved. Recently, the concept of ultrasonic fragmentation has been applied to biliary lithiasis. We observed the following unexpected postoperative complication.

### REPORT OF A CASE

A 47-year-old 72-kg female with a long history of biliary disease presented for elective hepatoscopy and ultrasonic intrahepatic lithotripsy. She had been well until 1972, when she presented with cholecystitis. During surgery an 8-inch common duct cyst and generalized common bile duct atrophy was found that was thought to be consistent with Caroli's Disease.<sup>3</sup> Since then she had had multiple surgical procedures involving her biliary tract. During this admission, several attempts at percutaneous stone extraction through an existing T-tube were performed. Because several intrahepatic calculi remained

after manipulation, ultrasonic lithotripsy was scheduled under general anesthesia.

After receiving diazepam 10 mg orally and meperidine 50 mg im, anesthesia was induced with thiopental iv and maintained with nitrous oxide, oxygen, and isoflurane. The previously constructed tract to the right hepatic duct was dilated. A Wolf low-pressure nephroscope was inserted and advanced under direct vision until the calculi were visualized. At the conclusion of the ultrasonic lithotripsy, approximately 7 ls of 0.9% normal saline had been infused for irrigation. During emergence from anesthesia in the operating room, the patient vomited about 1 l of thin, watery gastric contents. She was taken to the recovery room in good condition, where she vomited once more and after a 3-h period of observation was transferred back to her room.

### DISCUSSION

Percutaneous lithotripsy is a relatively new and effective alternative to open lithotomy, which offers a unique opportunity to relieve obstructive intrahepatic and biliary calculi. In endourology, normally the irrigating solution that is not evacuated through the suction of the cystoscope is passed into the ureter and bladder, preventing significant systemic uptake. In contrast, at the conclusion of the present case, irrigating saline remained in the relatively distensible duodenum and proximal jejunum.

A competent pyloric sphincter would prevent duodenal contents from refluxing into the stomach. While much controversy surrounds the issue of whether the pylorus acts as a true sphincter, Fisher *et al.* have studied the effects of intraduodenal saline infusions on barrier pressure and gastroduodenal reflux.<sup>4</sup> Twenty-eight normal subjects, ages 21-76, were fasted overnight, and pressure nanometers were introduced into the duodenum. After recording basal pressures, sphincter pressures were recorded during duodenal infusion of saline and 0.1 N HCl. Phenol red was added to each solution

\* Resident in Anesthesia, Massachusetts General Hospital, Harvard Medical School.

† Instructor in Anesthesia, Massachusetts General Hospital, Harvard Medical School.

‡ Assistant Clinical Professor of Surgery, Urology, Massachusetts General Hospital, Harvard Medical School.

§ Clinical Instructor in Radiology, Massachusetts General Hospital, Harvard Medical School.

Received from the Departments of Anesthesia, Urology, and Radiology, Massachusetts General Hospital, Boston, Massachusetts. Accepted for publication August 8, 1984.

Address reprint requests to Dr. Harris: Department of Anesthesiology, Children's Hospital, 300 Longwood Avenue, Boston, Massachusetts 02115.

Key words: Fluid Balance: Water intoxication. Pneumonia: Aspiration. Surgery: intrahepatic cholelithiasis.