

7. Scully RE, Galdabine JJ, McNeely BU: Case records of the Massachusetts General Hospital, Case 45—1980. *N Engl J Med* 303:1162–1171, 1980
8. Monreal J, Collins GH, Masters CL, Fisher CM, Kin RC, Gibbs CJ, Gajdusek DC: Creutzfeldt–Jacob Disease in an adolescent. *J Neurol Sci* 52:341–350, 1981
9. Behan PO: Creutzfeldt–Jacob Disease. *Br Med J* 284:1658–1659, 1982
10. Traub RD, Pedley TA: Virus-induced electronic coupling: hypothesis on the mechanism of periodic EEG discharges in Creutzfeldt–Jacob disease. *Ann Neurol* 10:405–408, 1981
11. Brown P, Gibbs CJ, Amyx HL, Kingsbury DT, Rohwer RG, Sulima MP, Gajdusek DC: Chemical disinfection of Creutzfeldt–Jacob disease virus. *N Engl J Med* 306:1279–1281, 1982
12. Khurana RK, Garcia JH: Autonomic dysfunction in subacute spongiform encephalopathy. *Arch Neurol* 38:114–117, 1981

Anesthesiology
60:592–594, 1984

Unusual Cause of Hypotension after Coronary Artery Bypass Grafting: Idiopathic Hypertrophic Subaortic Stenosis

JAMES PEARSON, M.D.,* AND J. G. REVES, M.D.†

Hypotension, decreased cardiac output, and elevated left atrial pressure after discontinuation of extracorporeal circulation for coronary artery bypass grafting (CABG) are usually signs of cardiac failure, which requires treatment with drugs and/or intraaortic counter-pulsation balloon. We recently encountered a case of persistent hypotension worsened by iv catecholamine therapy. A myomectomy was performed to correct hypertrophic subaortic stenosis. The patient then was weaned successfully from cardiopulmonary bypass (CPB).

REPORT OF A CASE

A 59-year-old 90-kg man, ASA physical status III, was scheduled for elective coronary artery saphenous vein bypass grafting. NYHA class II symptoms of ischemic heart disease and a recent subendocardial myocardial infarction prompted a cardiac catheterization, which revealed three-vessel coronary artery disease (left anterior descending 90%, circumflex 90%, and right coronary artery 50%). The left ventricular end-diastolic pressure was 8 mmHg preangiographic and postangiographic dye injection. The systolic left ventricular and aortic pressures were 170 mmHg. The ventricle was "hyperdynamic," with an ejection fraction of 50%. The mitral valve was normal.

He had a long history of hypertension and hyperuricemia. His physical examination included an enlarged left ventricle and a grade 2/6 systolic ejection murmur, loudest at the second right intercostal space, that radiated to the carotid arteries, bilaterally. The murmur was considered innocent, and the left ventricular hypertrophy secondary to hypertension. Current medications were nitroglycerin 1/150 prn, cutaneous nitroglycerin, hydrochlorothiazide, probenecid, and KCl. ECG showed borderline left ventricular hypertrophy with anterior lateral

ST-T-wave changes compatible with myocardial ischemia. The chest roentgenogram was normal.

About 90 minutes after the administration of diazepam 15 mg po, morphine sulfate 10 mg im, and scopolamine 0.3 mg im, anesthesia was induced with diazepam 0.4 mg/kg iv, lidocaine hydrochloride 1 mg/kg iv, and pancuronium bromide 0.1 mg/kg iv. Nitrous oxide and oxygen were administered via mask before the trachea was intubated. Anesthesia was maintained with fentanyl 20 mcg/kg iv and inhalation of 50% N₂O and enflurane, 0.7% inspired concentration. Heart rate and rhythm were monitored from V₅ or lead II of the ECG. The left radial and right atrial pressures were monitored continuously before CPB. Also, a 2 F thermister-tipped catheter was inserted into the pulmonary artery via the right ventricle before CPB for determination of cardiac output using the thermodilution technique.

An initial cardiac index measured in duplicate was 2.8 l/min/m². CPB was established, the proximal vein graft anastomoses were made, and the patient was cooled to 28°C. The aorta was cross-clamped and myocardial protection accomplished with potassium cold cardioplegia via the aortic root. There was no unusual amount of regurgitation of cardioplegic solution through the aortic valve during cardioplegia infusion. Seventy-four minutes were required for seven distal vein to coronary artery anastomoses. Total body rewarming was begun during the last distal anastomosis, and once complete, the aortic cross-clamp was removed.

Attempts at weaning the patient from CPB were unsuccessful. Pharmacologic support consisted of nitroglycerin 0.3 mcg · kg⁻¹ · min⁻¹ iv and dopamine 10 mcg · kg⁻¹ · min⁻¹ iv. Despite this therapy, the mean LAP remained elevated (28 mmHg), and systemic pressure and cardiac output were low, as attempts were made to terminate CPB. Central arterial aortic pressure (100 mmHg) was measured and equaled the radial artery pressure, but a needle placed in the left ventricle revealed a maximum systolic pressure of 180 mmHg (fig. 1A). Premature ventricular contractions were produced by manual stimulation of the heart surface, which showed a postextrasystolic decrease in radial arterial pressure, instead of the usual increase in arterial blood pressure (positive Brockenbrough's sign—fig. 2).¹ A presumptive diagnosis of left ventricular outflow obstruction was made possibly secondary to septal hypertrophy. Vasodilators and catecholamine infusions were discontinued, and CPB was reinstated at a flow of 2.2 l · min⁻¹ · m²⁻¹.

After aortotomy, inspection revealed that the aortic valve was normal; however, the septum was markedly hypertrophied and exhibited a small area of fibrosis. A part of the septum (1 × 1 × 5 cm) was excised to relieve the left ventricular outflow obstruction.² Without

* Instructor of Anesthesiology.

† Professor of Anesthesiology; Director of Anesthesia Research.

Received from the Department of Anesthesiology, The University of Alabama Medical Center, 619 19th St. South, Birmingham, AL 35294. Accepted for publication November 4, 1983.

Address reprint requests to Dr. Pearson.

Key words: Heart: idiopathic hypertrophic subaortic stenosis; Complications: hypotension; Surgery: cardiac.

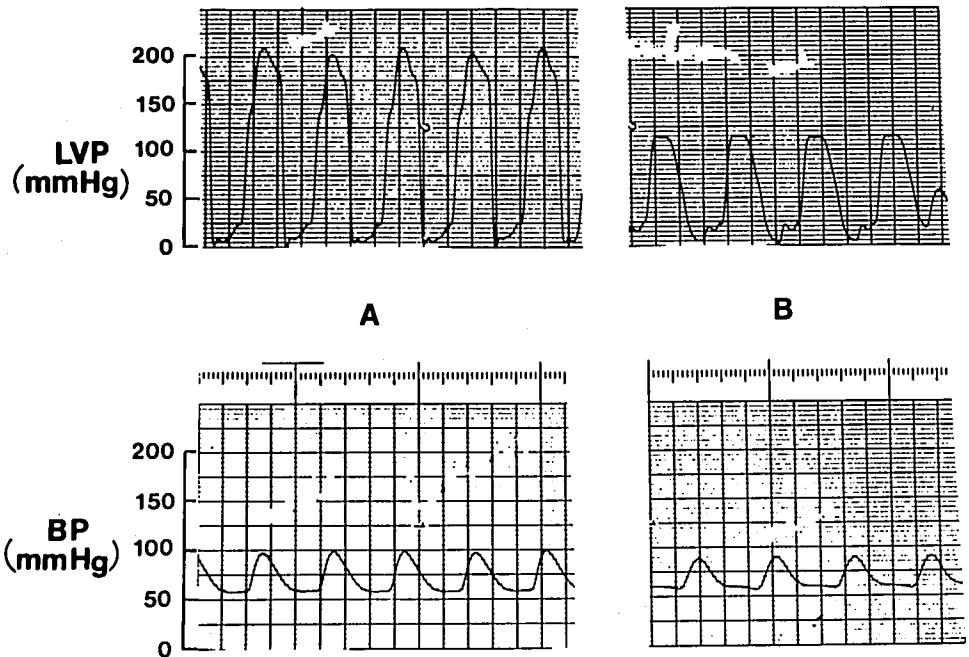


FIG. 1. Elevated left ventricular pressure (LVP) with concurrent low-normal systemic blood pressure (BP) seen in A is corrected after myomectomy so that the LVP and BP are more nearly normal (B). See text for details.

pharmacologic assistance to the heart, CPB was discontinued successfully, and the gradient from the left ventricle to the aortic root measured an acceptable 20 mmHg (fig. 1B). The patient tolerated the remainder of the procedure without difficulty and was taken to the CICU in stable condition. M-mode echocardiography prior to discharge revealed asymmetric septal hypertrophy with a septal to posterior wall ratio of 1.33.

DISCUSSION

Patients with idiopathic hypertrophic subaortic stenosis (IHSS) have a ventricular septum that is disproportionately hypertrophied compared with the posterobasal left ventricular free wall. In patients with IHSS, obstruction of the ventricular outflow tract occurs when the free edge of the anterior mitral leaflet moves forward during mid-systole against the hypertrophied ventricular septum.³ Braunwald⁴ described the dynamic nature of the obstruction at catheterization by changing the gradient between left ventricle and aorta with several different interventions; for example, increased arterial pressure or reduced myocardial contractility reduces the outflow gradient. On the other hand, decreased arterial pressure, increased myocardial contractility, or decreased left ventricular volume augments the gradient. Our patient developed a large pressure gradient between the left ventricle and aorta during attempts to wean from CPB.

IHSS can be classified as nonobstructive, evocable, or obstructive.⁵ This diagnosis usually is made at catheterization. Almost all of the patients with obstructive disease are symptomatic and may have angina, dyspnea on exertion, presyncope or syncope, and may have symptoms that mimic coronary artery disease.⁵ The incidence of

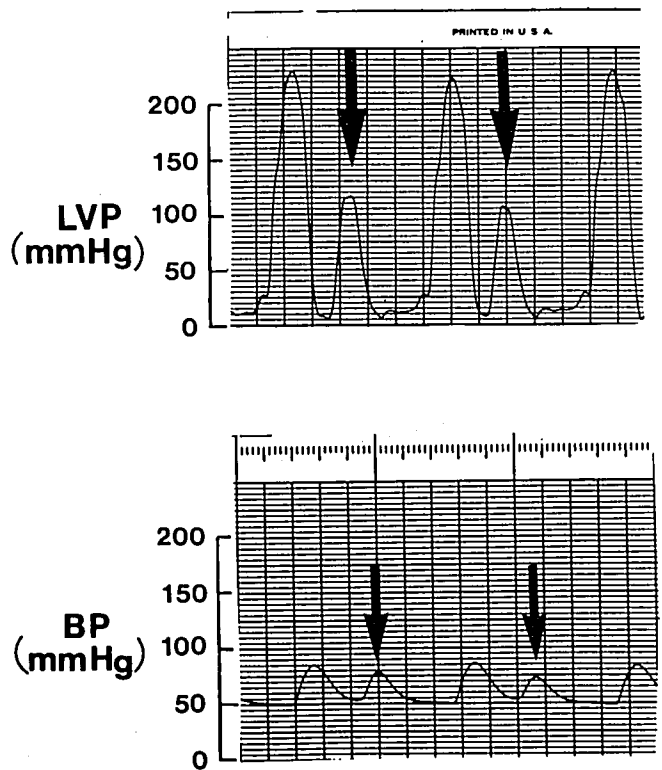


FIG. 2. Brockenbrough's sign; direct aortic tracing showing no increase in blood pressure after a premature ventricular contraction. Usually, a premature ventricular contraction causes a compensatory pause and this time allows for increased ventricular filling and increased myocardial contractility by the Starling mechanism. However, if an obstruction to outflow exists, then the systemic pressures will not reflect this sudden improvement in myocardial performance. This is diagnostic of IHSS (1). (Arrows indicate premature ventricular contractions.)

IHSS in patients with CAD is unknown, but it is known that there is a 15–20% incidence of CAD in patients with IHSS.⁶

In our case, the diagnosis of IHSS could have been made preoperatively by an echocardiogram and a more detailed physical examination (*i.e.*, maneuvers to decrease ventricular afterload or preload, making the murmur louder); however, IHSS was not suspected until difficulty in weaning from CPB occurred. Undoubtedly, the increase in myocardial contractility, secondary to dopamine infusion, in addition to preload reduction with nitroglycerin, led to increased outflow obstruction, which led to decreased stroke volume. It is also possible that improved myocardial performance after revascularization may have led to the obstructive symptoms that had never been documented in this patient.

In summary, we present an unusual but important cause of cardiac failure during discontinuation of CPB. Coronary bypass graft patients may have an unrecognized obstruction of the ventricular outflow tract. Detection

involves measurement of left ventricular to aortic gradient and treatment is surgical excision of the obstruction. The customary treatment of postbypass low cardiac output with vasodilators and inotropic agents worsens the condition and jeopardizes chances of a successful outcome.

REFERENCES

1. Brockenbrough EC, Braunwald E, Morrow AG: A hemodynamic technique for the detection of hypertrophic subaortic stenosis. *Circulation* 23:189–194, 1961
2. Kirklin JW, Ellis FH: Surgical relief of diffuse subvalvular stenosis. *Circulation* 24:739–742, 1961
3. Simon AL, Ross J Jr, Gault JH: Angiographic anatomy of the left ventricle and mitral valve in idiopathic hypertrophic subaortic stenosis. *Circulation* 36:852–867, 1967
4. Braunwald E: *Heart Disease*. Philadelphia, WB Saunders, 1980, pp 1456–1458
5. Harrison TR, Isselbacher KJ, Adams RD, Braunwald E, Petersdorf RG, Wilson JD: *Principles of Internal Medicine*, 9th edition. New York, McGraw-Hill, 1980, p 1145
6. Walston J, Behav V: Spectrum of coronary artery disease in idiopathic subaortic stenosis. *Am J Cardiol* 38:12–16, 1976

Anesthesiology
60:594–598, 1984

Propranolol Postoperative Maintenance by Continuous Intravenous Infusion

DANIEL VILLERS, M.D.,* MICHEL L. J. PINAUD, M.D.,† MICHEL BOURIN, M.D.,‡ BRIGITTE FRISON, M.D.,§
RÉMY J. SOURON, M.D.,¶ FRANÇOISE M. NICOLAS, M.D.**

In patients with coronary artery disease receiving propranolol and undergoing surgery, propranolol can be given up to the morning of surgery without adverse hemodynamic effects.^{1–3} If propranolol administration is terminated postoperatively for more than 24 h, the withdrawal rebound syndrome may occur,⁴ consisting of tachycardia, hypertension, worsening angina pectoris, ventricular arrhythmias, myocardial infarction, and even sudden death.⁵ During abdominal surgery, postoperative

maintenance of propranolol by an iv administration seems logical when patients cannot take the drug orally for at least 24 h.

Few reports on the iv administration of propranolol in patients with coronary artery disease undergoing abdominal surgery procedure are available.⁶ We describe below the clinical benefits and the hemodynamic effects of a continuous iv propranolol infusion maintaining postoperatively the plasma propranolol concentration within the 14 to 90 ng/ml range. According to Pine *et al.*⁷ such a concentration range is associated with optimal relief of angina pectoris and with a 64–98% blockade of exercise-induced tachycardia.

PATIENTS AND METHODS

Seven patients (49–61 yr) scheduled for abdominal surgery and receiving propranolol therapy because of a documented history of angina pectoris (Grade III) gave informed consent to this study, which was approved by our medical staff (table 1). Preoperatively, propranolol therapy was well tolerated; no patient had clinical, radiologic, or ECG evidence of congestive failure or atrioventricular block. Blood urea and serum creatinine as well as liver function tests were all within normal levels.

The patients received their last oral dose of propranolol

* Assistant in Intensive Care Medicine, Services de Réanimation Médicale.

† Assistant Professor of Anesthesiology, d'Anesthésiologie.

‡ Assistant Professor of Pharmacology, de Pharmacologie Clinique.

§ Assistant in Pharmacology.

¶ Professor and Chairman of Anesthesiology.

** Professor and Chairperson of Intensive Care Medicine.

Received from the Services de Réanimation Médicale; d'Anesthésiologie et de Pharmacologie Clinique, Hôtel-Dieu, Centre Hospitalier Universitaire, 44035 Nantes Cedex, France. Accepted for publication November 7, 1983. Presented in part at the annual meeting of the American Society of Anesthesiologists, Las Vegas, Nevada, September 1982.

Address reprint requests to Dr. Villers: Service de Réanimation, Place Alexis Ricordeau, 44035 Nantes Cedex, France.

Key words: Sympathetic nervous system; beta receptor blocker, propranolol; Heart: coronary artery occlusive disease; Surgery: Abdominal.